



PATIENT

Loui Coon

SPECIES

Canine

BREED

Yorkshire Terrier

SEX

Neutered male

AGE

6 years

WEIGHT

8.8 lbs

INTERPRETED BY

Eric Lindquist, DMV
DABVP, Cert. IVUSS

IMAGING PERFORMED BY

Bill McGee

HOSPITAL NAME

Bridgeport Animal
Hospital PLLC

REFERRING VET

Dr. Smith Bennett

INVOICE

68738

DATE

11/17/25

PRESENTING CLINICAL SIGNS

History: Loui has a history of chronic cough. Radiographs by the rDVM showed possibly cardiac silhouette enlargement. A dental cleaning is needed and the rDVM requested an echocardiogram to evaluate the heart

ULTRASONOGRAPHIC EXAMINATION OF THE HEART

The echocardiogram in this patient demonstrated normal **left atrial** size based on 3 separate methods of LA evaluation. The cranial and caudal **mitral** valve leaflets presented normal linear structure, extension in systole, and union in diastole with normal kinesis. The **left ventricle** presented thicknesses with linear contour and was not dilated nor restricted. The **myocardium** presented normal echogenicity without subjective evidence of significant fibrotic or ischemic disease. **Contractility** of the ventricular walls was adequate and in normal range for this patient evidenced by the fractional shortening measurement and subjective evaluation of the different regions of the myocardium. The **left ventricular outflow** tract demonstrated normal laminar flow and subjective structural integrity. The **right atrium** and auricle revealed normal size, structure and content. No evidence of masses was noted. **Tricuspid** valvular assessment demonstrated adequate linear morphology and kinesis. The **right ventricle** was of normal size (1/3 diameter of LV), chordae structure, myocardial echogenicity and thickness. **Pulmonary outflow** tract assessment revealed normal valve structure, laminar flow, and diameter (approx. 1:1 pa/ao ratio). No visible **pericardial** or free pleura fluid was noted. The cranial **mediastinum and pericardial and extra-cardiac regions** were free of masses in the visible window.

E Wave Velocity 0.7 m/sec

CANINE CARDIAC PARAMETERS	MR VMAX (m/s)	TR VMAX (m/s)	LA/AO	LA/AO (Heart Base)	FS (%)	EF (%)	EPSS (cm)
NORMAL PARAMETER	4.5-5.5	<2.7	1.3	<1.6	28-40	40-100	<0.6
PATIENT			1.0	1.18	35	68	0.1
CANINE CARDIAC PARAMETERS	HR (BPM)	AV VMAX (m/s)	PV MAX (m/s)	BODY WEIGHT	LA 2D short axis Base view (cm)	LVIDd Avg; 2D and m-mode short axis (cm)	LVIDs Avg; 2D and m-mode short axis (cm)
NORMAL PARAMETER	50-100	0.7-1.7	0.7-1.6	BELOW	BELOW	BELOW	BELOW
PATIENT		0.8	0.83	8.8 lbs	1.9	1.7	

ULTRASONOGRAPHIC FINDINGS

Normal echocardiogram.



PATIENT

Loui Coon

SPECIES

Canine

BREED

Yorkshire Terrier

SEX

Neutered male

AGE

6 years

WEIGHT

8.8 lbs

INTERPRETED BY

Eric Lindquist, DMV
DABVP, Cert. IVUSS

IMAGING PERFORMED BY

Bill McGee

HOSPITAL NAME

Bridgeport Animal
Hospital PLLC

REFERRING VET

Dr. Smith Bennett

INVOICE

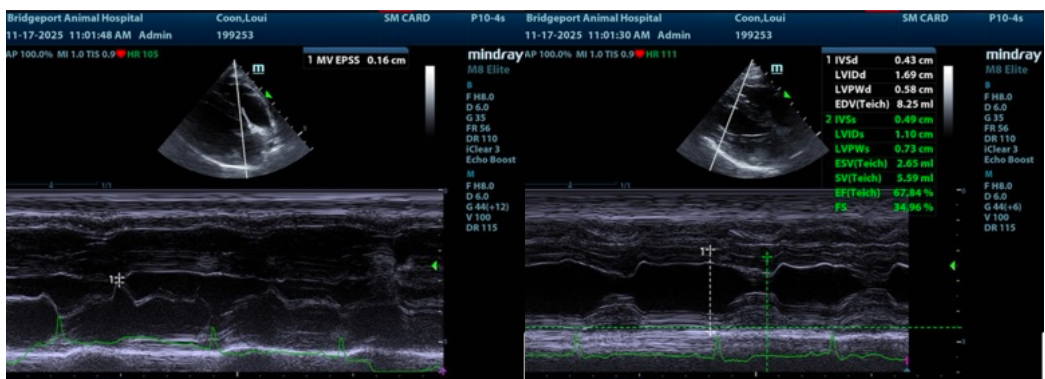
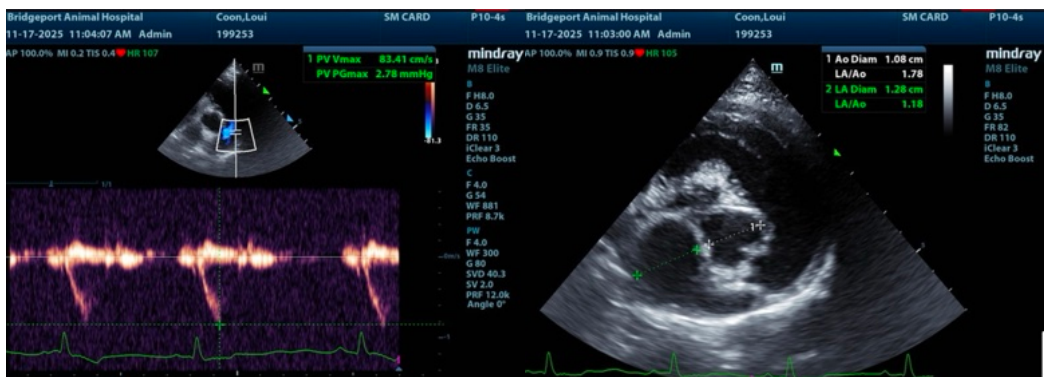
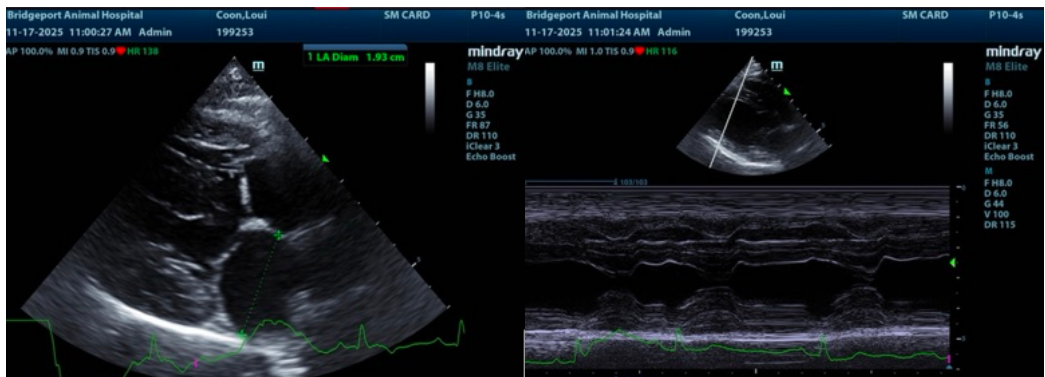
68738

DATE

11/17/25

INTERPRETATION OF THE FINDINGS & FURTHER RECOMMENDATIONS

There is no contraindication to anesthetic procedure. The cough is non-cardiogenic. There was no evidence of murmurs noted. Primary respiratory protocol is indicated.





PATIENT

Loui Coon

SPECIES

Canine

BREED

Yorkshire Terrier

SEX

Neutered male

AGE

6 years

WEIGHT

8.8 lbs

INTERPRETED BY

Eric Lindquist, DMV
DABVP, Cert. IVUSS

IMAGING PERFORMED BY

Bill McGee

HOSPITAL NAME

Bridgeport Animal
Hospital PLLC

REFERRING VET

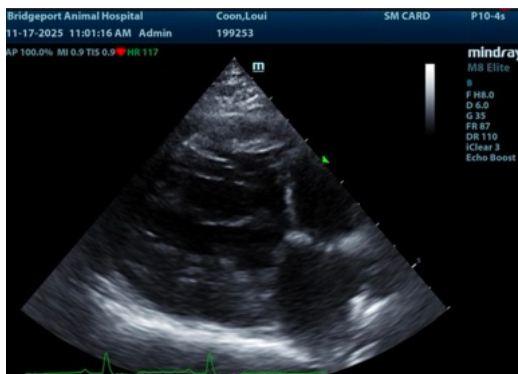Dr. Smith Bennett

INVOICE

68738

DATE

11/17/25



The information and recommendations provided are based on the images presented by the referring veterinarian/sonographer. No evaluation can be communicated regarding pathology that was not visible in the image/video clips provided.

Thank you for this referral. If the clinical or image interpretation does not parallel your findings or if I can be of any further assistance please contact me.

Eric Lindquist, DMV, DABVP (CFM), Cert. IVUSS, CEO of SonoPath.com

info@SonoPath.com