



PATIENT

Haze Pale

SPECIES

Canine

BREED

Pomeranian Mix

SEX

Neutered male

AGE

12 ½ years

WEIGHT

12 lbs

INTERPRETED BY

Eric Lindquist, DMV
DABVP, Cert. IVUSS

IMAGING PERFORMED BY

Dr. John Sampson

HOSPITAL NAME

Richboro VH

REFERRING VET

Dr. Sampson

INVOICE

68749

DATE

11/17/25

PRESENTING CLINICAL SIGNS

History: Doing well the past 6 months. Currently on Vetmedin 2.5 mg - 1/2 po bid 6 month recheck as recommended post initial echo

ULTRASONOGRAPHIC EXAMINATION OF THE HEART

The echocardiogram in this patient presented no significant volume overload in any of the four chambers. Contractility was adequate. Mitral insufficiency and aortic insufficiency was noted and is compensated.

CANINE CARDIAC PARAMETERS	MR VMAX (m/s)	TR VMAX (m/s)	LA/AO	LA/AO (Heart Base)	FS (%)	EF (%)	EPSS (cm)
NORMAL PARAMETER	4.5-5.5	<2.7	1.3	<1.6	28-40	40-100	<0.6
PATIENT	5.2		1.3	1.3	48	82	0.1
CANINE CARDIAC PARAMETERS	HR (BPM)	AV VMAX (m/s)	PV MAX (m/s)	BODY WEIGHT	LA 2D short axis Base view (cm)	LVIDd Avg; 2D and m-mode short axis (cm)	LVIDs Avg; 2D and m-mode short axis (cm)
NORMAL PARAMETER	50-100	0.7-1.7	0.7-1.6	BELOW	BELOW	BELOW	BELOW
PATIENT	127	0.1	0.7	12 lbs	2.36	2.1	

ULTRASONOGRAPHIC FINDINGS

Stable valvular disease with mitral and aortic insufficiency.

Stable B2 valvular disease.

INTERPRETATION OF THE FINDINGS & FURTHER RECOMMENDATIONS

Significant improvement has occurred under the current clinical protocol. I recommend continuation of the current protocol and monitoring blood pressure measurements and a recheck echocardiogram in 6 months.



PATIENT

Haze Pale

SPECIES

Canine

BREED

Pomeranian Mix

SEX

Neutered male

AGE

12 ½ years

WEIGHT

12 lbs

INTERPRETED BY

Eric Lindquist, DMV
DABVP, Cert. IVUSS

IMAGING PERFORMED BY

Dr. John Sampson

HOSPITAL NAME

Richboro VH

REFERRING VET

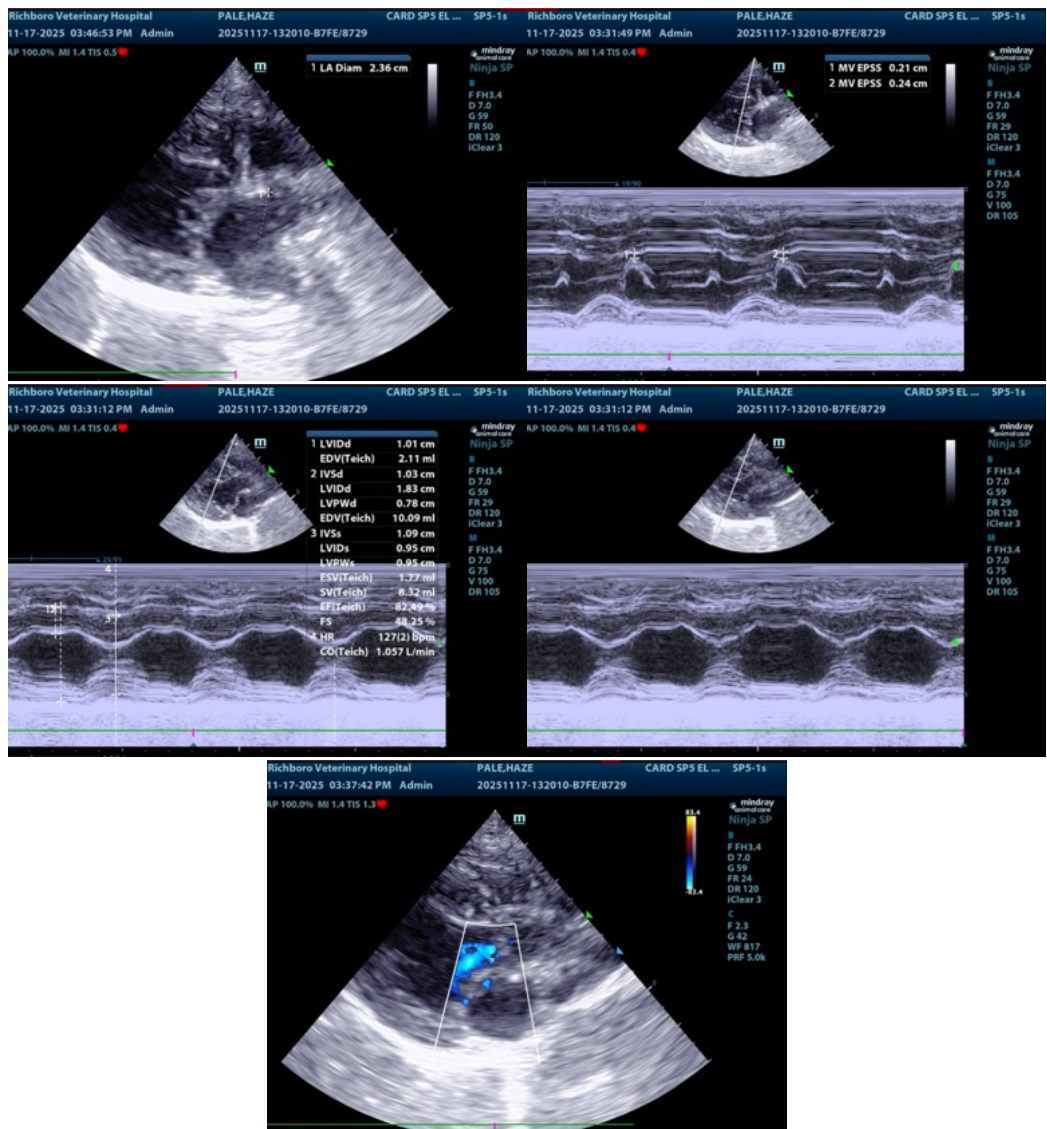
Dr. Sampson

INVOICE

68749

DATE

11/17/25



The information and recommendations provided are based on the images presented by the referring veterinarian/sonographer. No evaluation can be communicated regarding pathology that was not visible in the image/video clips provided.

Thank you for this referral. If the clinical or image interpretation does not parallel your findings or if I can be of any further assistance please contact me.

Eric Lindquist, DMV, DABVP (CFM), Cert. IVUSS, CEO of SonoPath.com

info@SonoPath.com