



PATIENT

Chloe Duncan

SPECIES

Canine

BREED

Pomeranian

SEX

Female

AGE

6 years

WEIGHT

9.2 lbs

INTERPRETED BY

Eric Lindquist, DMV
DABVP, Cert. IVUSS

PRESENTING CLINICAL SIGNS

History: Heart sounds were normal during pre surgery exam, was sedated for dental. ECG prior to induction- bradycardia with occasional third degree heart block- frequency increasing as waiting for atropine injection, noted few VPC's , Heart sounds on auscultation- development of grade 3 murmur PMI- mitral valve

ULTRASONOGRAPHIC EXAMINATION OF THE HEART

The echocardiogram in this patient demonstrated normal **left atrial** size based on 3 different LA measurement methods. Chamber volumes and echogenicity were normal. The cranial and caudal **mitral** valve leaflets presented vegetative thickening consistent with endocardiosis. Doppler indicated measurable insufficiency. The **left ventricle** presented thicknesses with linear contour and was not dilated nor restricted. The **myocardium** presented normal echogenicity without subjective evidence of significant fibrotic or ischemic disease. **Contractility** of the ventricular walls was adequate and in normal range for this patient evidenced by the fractional shortening measurement and subjective evaluation of the different regions of the myocardium. The **left ventricular outflow** tract demonstrated normal laminar flow and subjective structural integrity. The **right atrium** and auricle revealed normal size, structure and content. No evidence of masses was noted or chamber overload. Trivial **tricuspid** insufficiency was noted. The **right ventricle** was of normal size (1/3 diameter of LV), chordae structure, myocardial echogenicity and thickness. **Pulmonic** tract assessment revealed normal valve structure, laminar flow, and diameter (approx. 1:1 pa/ao ratio). No visible **pericardial** or free pleura fluid was noted. No echographically detectable evidence of infiltrative disease was visible. The cranial **mediastinum and pericardial regions** were free of masses in the visible window.

E Wave Velocity 0.86 m/sec.

IMAGING PERFORMED BY

Dr. Meier-Gast

HOSPITAL NAME

Meier VC

REFERRING VET

Dr. Meier-Gast

INVOICE

68736

DATE

11/17/25

| CANINE CARDIAC PARAMETERS | MR VMAX (m/s) | TR VMAX (m/s) | LA/AO | LA/AO (Heart Base) | FS (%) | EF (%) | EPSS (cm) |
|---------------------------|---------------|---------------|--------------|--------------------|---------------------------------|--|--|
| NORMAL PARAMETER | 4.5-5.5 | <2.7 | 1.3 | <1.6 | 28-40 | 40-100 | <0.6 |
| PATIENT | 5.0 | 1.0 | NM | 1.2 | 52 | 85 | 0.4 |
| CANINE CARDIAC PARAMETERS | HR (BPM) | AV VMAX (m/s) | PV MAX (m/s) | BODY WEIGHT | LA 2D short axis Base view (cm) | LVIDd Avg; 2D and m-mode short axis (cm) | LVIDs Avg; 2D and m-mode short axis (cm) |
| NORMAL PARAMETER | 50-100 | 0.7-1.7 | 0.7-1.6 | BELOW | BELOW | BELOW | BELOW |
| PATIENT | 70 | 1.2 | 2.14 | 9.2 lbs | 2.0 | 2.19 | |



PATIENT

Chloe Duncan

SPECIES

Canine

BREED

Pomeranian

SEX

Female

AGE

6 years

WEIGHT

9.2 lbs

INTERPRETED BY

Eric Lindquist, DMV
DABVP, Cert. IVUSS

IMAGING PERFORMED BY

Dr. Meier-Gast

HOSPITAL NAME

Meier VC

REFERRING VET

Dr. Meier-Gast

INVOICE

68736

DATE

11/17/25

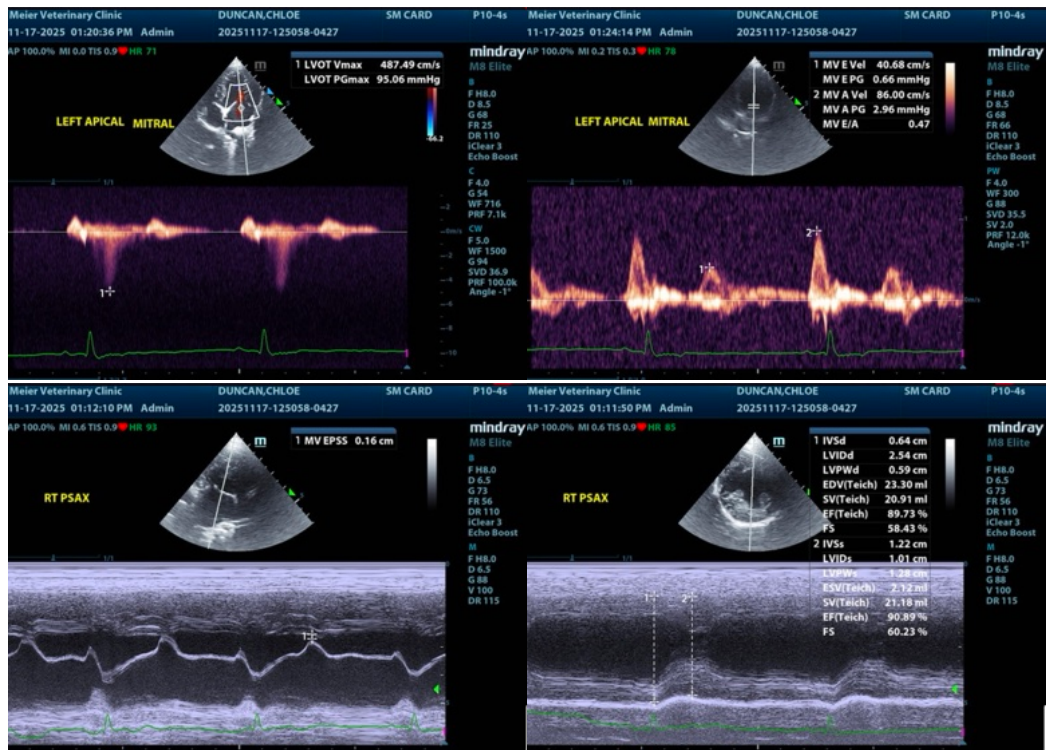
ULTRASONOGRAPHIC FINDINGS

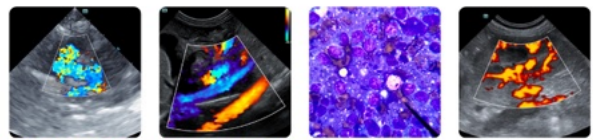
Stage B1 valvular disease.

INTERPRETATION OF THE FINDINGS & FURTHER RECOMMENDATIONS

There was no evidence of volume overload or pressure overload. No arrhythmogenic activity was noted at the time of the echocardiogram.

The heart is stable without clinical disease. No overt contraindication for anesthesia of brief to moderate duration. I suggest Torbutrol premed, Propofol induction, Isoflor maintenance or similar protocol if anesthesia is desired. Blood pressure recommended if not already performed and target white coat negative systolic pressure of < 160 mmHg. If higher than this ACE-inhibitor is suggested to reach this level. Recheck echocardiogram is recommended in 6 months, earlier if murmur grade increases or clinical signs initiate.





PATIENT

Chloe Duncan

SPECIES

Canine

BREED

Pomeranian

SEX

Female

AGE

6 years

WEIGHT

9.2 lbs

INTERPRETED BY

Eric Lindquist, DMV
DABVP, Cert. IVUSS

IMAGING PERFORMED BY

Dr. Meier-Gast

HOSPITAL NAME

Meier VC

REFERRING VET

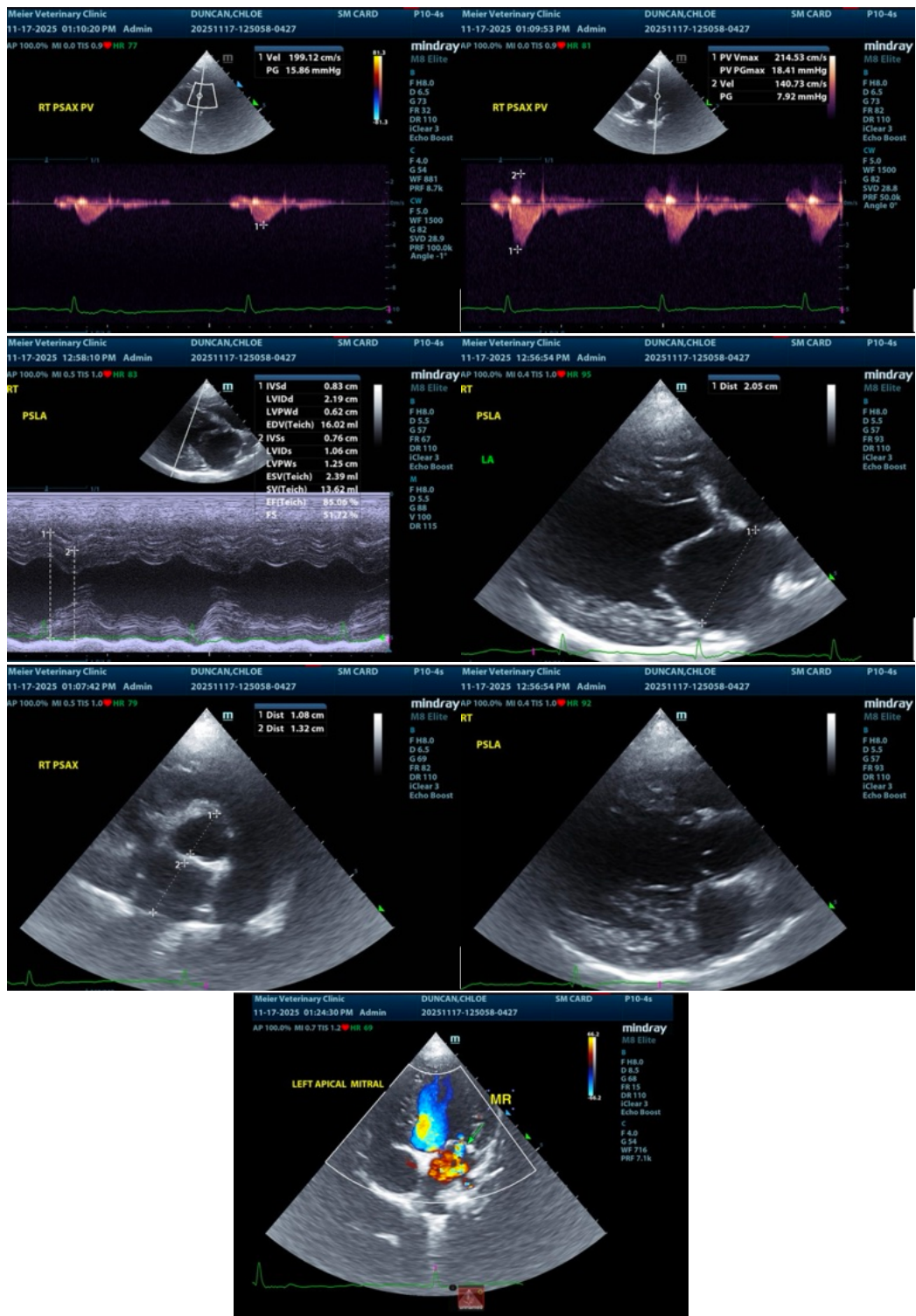
Dr. Meier-Gast

INVOICE

68736

DATE

11/17/25



The information and recommendations provided are based on the images presented by the referring veterinarian/sonographer. No evaluation can be communicated regarding pathology



PATIENT

Chloe Duncan

SPECIES

Canine

BREED

Pomeranian

SEX

Female

AGE

6 years

WEIGHT

9.2 lbs

INTERPRETED BY

Eric Lindquist, DMV
DABVP, Cert. IVUSS

IMAGING PERFORMED BY

Dr. Meier-Gast

HOSPITAL NAME

Meier VC

REFERRING VET

Dr. Meier-Gast

INVOICE

68736

DATE

11/17/25

that was not visible in the image/video clips provided.

Thank you for this referral. If the clinical or image interpretation does not parallel your findings or if I can be of any further assistance please contact me.

Eric Lindquist, DMV, DABVP (CFM), Cert. IVUSS, CEO of SonoPath.com

info@SonoPath.com