



**PATIENT**

Pedro Lutz

**PRESENTING CLINICAL SIGNS**

diarrhea and vomiting, anorexia for one day

**SPECIES**

Canine

**ULTRASONOGRAPHIC EXAMINATION OF THE ABDOMEN**

**Urinary System**

The **urinary bladder**, trigone, and pelvic urethra presented normal thicknesses and normal tone. The ureters were not visible which is normal. No uroliths or sediment were visualized and anechoic urine was present. No evidence of inflammatory or neoplastic changes were noted. Ureteral papillae were normal.

**BREED**

Chihuahua

**SEX**

Neutered Male

The **kidneys** revealed largely normal size and structure, corticomedullary definition and ratio (cortex 1/3 of medulla) were essentially maintained with some age-related loss of curvilinear patterns regarding the capsule and C/M junction. The cortices presented largely uniform texture with some increased echogenicity expected for his age patient. Medullary structure differed distinctly from that of the cortex and no evidence of pelvic dilation was present. The right kidney measured 4.03 cm. The left kidney measured 4.08 cm.

**AGE**

9 Years

**Adrenal Glands**

The **right adrenal gland** was mildly enlarged, measuring 1.97 cm x 1.17 cm at the cranial pole and 0.68 cm at the caudal pole. The **left adrenal gland** was uniform and measured 1.51 cm x 0.45 cm at the caudal pole and 0.57 cm at the cranial pole.

**WEIGHT**

9.7 Pounds

**Spleen**

The **spleen** presented a smooth homogeneous parenchyma hyperechoic to liver and renal cortical parenchyma. The capsule was smooth without noticeable expansion or deviation from within the spleen or adjacent pathology. The splenic vasculature demonstrated normal volume without signs of congestion or thrombosis. No sonographic evidence of acute or chronic inflammatory, neoplastic, or infarctual changes were noted.

**INTERPRETED BY**

Eric Lindquist, DMV  
DABVP, Cert. IVUSS

**IMAGING PERFORMED BY**

Jenn

**Liver**

The **liver** images from right and left intercostal as well as subcostal views revealed subjectively normal liver size, contour, and structure. Some age-related parenchymal remodeling was noted but likely not clinically significant at this time. Vascular and biliary tracts were of normal volume and no evidence of congestion was noted. The gallbladder presented some dependent debris with essentially normal contour. The cystic and common bile ducts were normal. No overt evidence of active inflammatory, infiltrative or regenerative pathology was noted but should be paired with current or past LE elevations regarding any clinical significance to this presentation. The hepatic lymph nodes were unremarkable.

**HOSPITAL NAME**

Rockaway AH

**REFERRING VET**

Dr. Maniar

**Gastrointestinal**

Examination of the **gastrointestinal tract** revealed hyperperistalsis, mild increased submucosal echogenicity, and areas of hypertrophied muscularis. Some reactive mesentery was noted associated with the small intestine. Minor pyloric thickening present.

**INVOICE**

29851

**Pancreas**

Minor heterogeneous **pancreatic** changes noted. Low-grade pancreatitis/gastroenteritis suspected.

**DATE**

11/17/21



**PATIENT**

Pedro Lutz

**ULTRASONOGRAPHIC FINDINGS**

- Gastroenteritis/minor pancreatitis pattern
- Age related abdominal changes otherwise

**SPECIES**

Canine

**INTERPRETATION OF THE FINDINGS & FURTHER RECOMMENDATIONS**

Supportive care should prove effective.

**BREED**

Chihuahua

**SEX**

Neutered Male

**AGE**

9 Years

**WEIGHT**

9.7 Pounds

**INTERPRETED BY**

Eric Lindquist, DMV  
DABVP, Cert. IVUSS

**IMAGING PERFORMED BY**

Jenn

**HOSPITAL NAME**

Rockaway AH

**REFERRING VET**

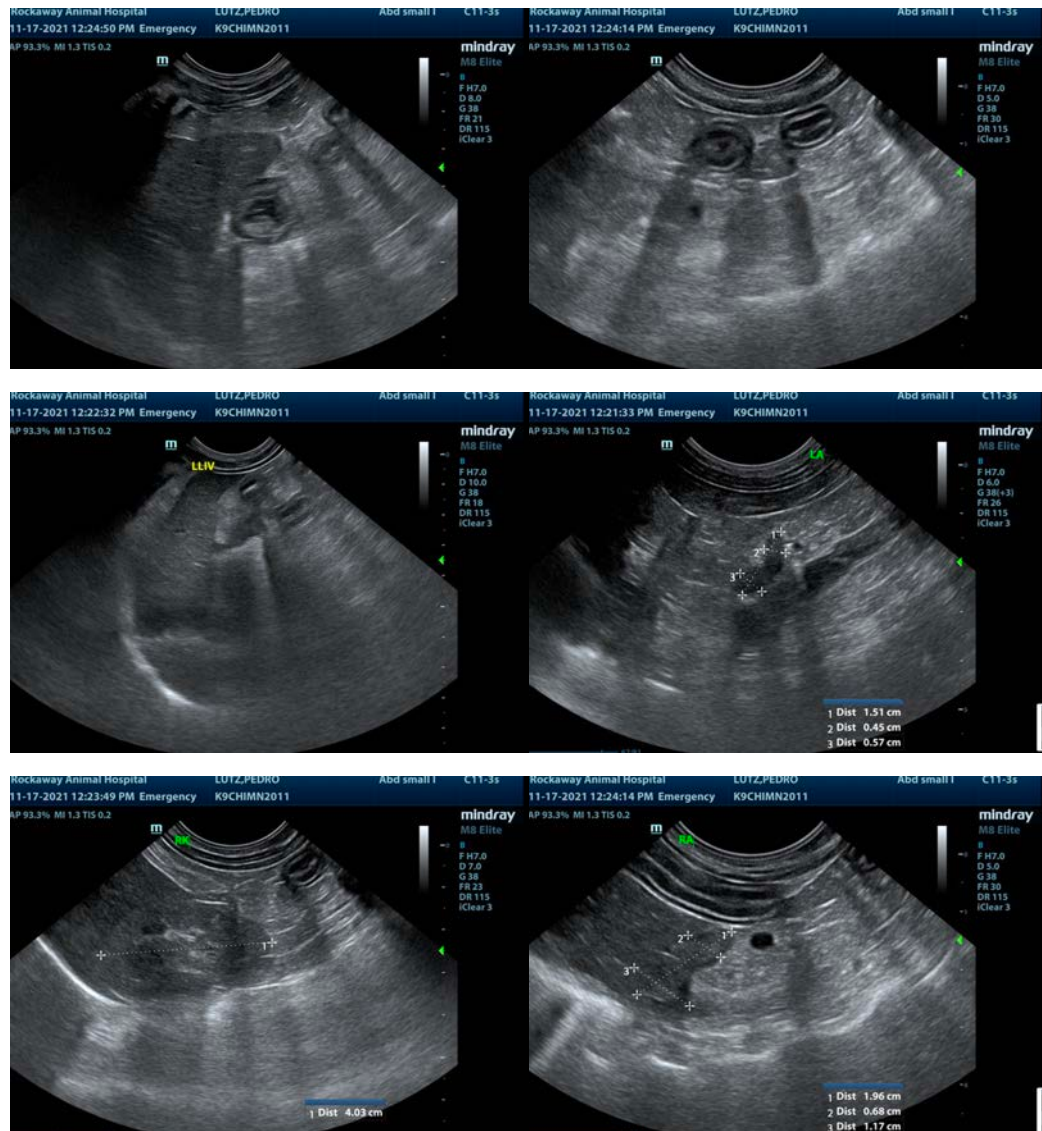
Dr. Maniar

**INVOICE**

29851

**DATE**

11/17/21





**PATIENT**

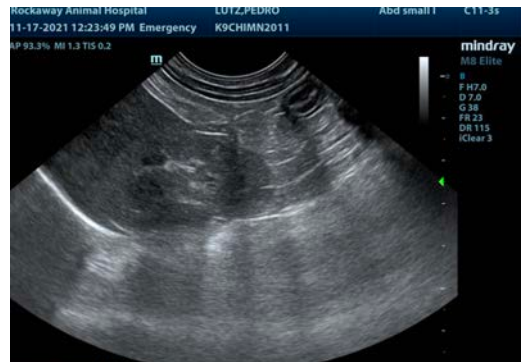Pedro Lutz

**SPECIES**

Canine

**BREED**

Chihuahua



**SEX**

Neutered Male

The information and recommendations provided are based on the images presented by the referring veterinarian. No evaluation can be communicated regarding pathology that was not visible in the image/video clips provided.

**AGE**

9 Years

Thank you for this referral. If the clinical or image interpretation does not parallel your findings or if I can be of any further assistance please contact me.

**WEIGHT**

9.7 Pounds

**Eric Lindquist**, DMV, DABVP, Cert. IVUSS, CEO of SonoPath.com  
[info@SonoPath.com](mailto:info@SonoPath.com)

**INTERPRETED BY**

Eric Lindquist, DMV  
DABVP, Cert. IVUSS

**IMAGING  
PERFORMED BY**

Jenn

**HOSPITAL NAME**

Rockaway AH

**REFERRING VET**

Dr. Maniar

**INVOICE**

29851

**DATE**

11/17/21