



## PATIENT

Brownie Vercosa

## SPECIES

Canine

## BREED

Dachshund

## SEX

Neutered Male

## AGE

6 Years

## WEIGHT

30 lbs

## INTERPRETED BY

Eric Lindquist, DMV,  
DABVP (CFM), Cert.  
IVUSS

## IMAGING PERFORMED BY

Dr. Jeremiah Gabriel

## HOSPITAL NAME

Central Jersey Animal  
Hospital

## REFERRING VET

Dr. Jeremiah Gabriel

## INVOICE

71870

## DATE

11/16/25

## PRESENTING CLINICAL SIGNS

Severe abdominal pain lameness on and off in the right front leg  
Abnormal PE/Chem/CBC/UA Results: History of pancreatitis three weeks ago

## ULTRASONOGRAPHIC EXAMINATION OF THE ABDOMEN

### Urinary System

The **urinary bladder**, trigone, and pelvic urethra presented normal thicknesses and normal tone. The ureters were not visible which is normal. No uroliths or sediment were visualized and anechoic urine was present. No evidence of inflammatory or neoplastic changes were noted. Ureteral papillae were normal. The pelvic urethra was imaged 1.0 cm beyond the cystourethral junction.

The **kidneys** revealed normal size and structure, corticomedullary definition and ratio for this age. The cortices presented largely uniform texture with normal echogenic relationship to liver and spleen. Medullary structure differed distinctly from the cortex and no evidence of pelvic dilation was present. The capsules were acceptably uniform without significant irregularities. The left kidney measured 5.4 cm. The right kidney measured 4.5 cm.

### Adrenal Glands

The **adrenal glands** were not visualized.

### Spleen

The **spleen** presented a smooth homogeneous parenchyma hyperechoic to liver and renal cortical parenchyma. The capsule was smooth without noticeable expansion or deviation from within the spleen or adjacent pathology. The splenic vasculature demonstrated normal volume without signs of congestion or thrombosis. No sonographic evidence of acute or chronic inflammatory, neoplastic, or infarctual changes were noted.

### Liver

The **liver** images submitted revealed subjectively normal liver size, contour, and structure. Parenchymal echogenicity was naturally coarse and hypoechoic to the spleen. Vascular and biliary tracts were of normal volume with no evidence of congestion. The gallbladder presented acceptably thin walls with primarily anechoic content. The cystic and common bile ducts were normal. No pathological hepatic lymphadenopathy was evident. No overt structural evidence of inflammatory, infiltrative or regenerative pathology was evident.

### Gastrointestinal

There was some residual chyme and gas was noted in the **stomach**, yet not pathological. This is consistent with end post prandial presentation. Transit of chyme into the small intestine was normal. Curvilinear patterns were maintained throughout the GI tract. No evidence of pathology. Small and large intestine demonstrated normal luminal chyme and stool consistency respectively. No obstructive or overt infiltrative disease was noted. No associated abnormal lymphatic activity was noted.



## PATIENT

Brownie Vercosa

## SPECIES

Canine

## BREED

Dachshund

## SEX

Neutered Male

## AGE

6 Years

## WEIGHT

30 lbs

## INTERPRETED BY

Eric Lindquist, DMV,  
DABVP (CFM), Cert.  
IVUS

## IMAGING PERFORMED BY

Dr. Jeremiah Gabriel

## HOSPITAL NAME

Central Jersey Animal  
Hospital

## REFERRING VET

Dr. Jeremiah Gabriel

## INVOICE

71870

## DATE

11/16/25

## Pancreas

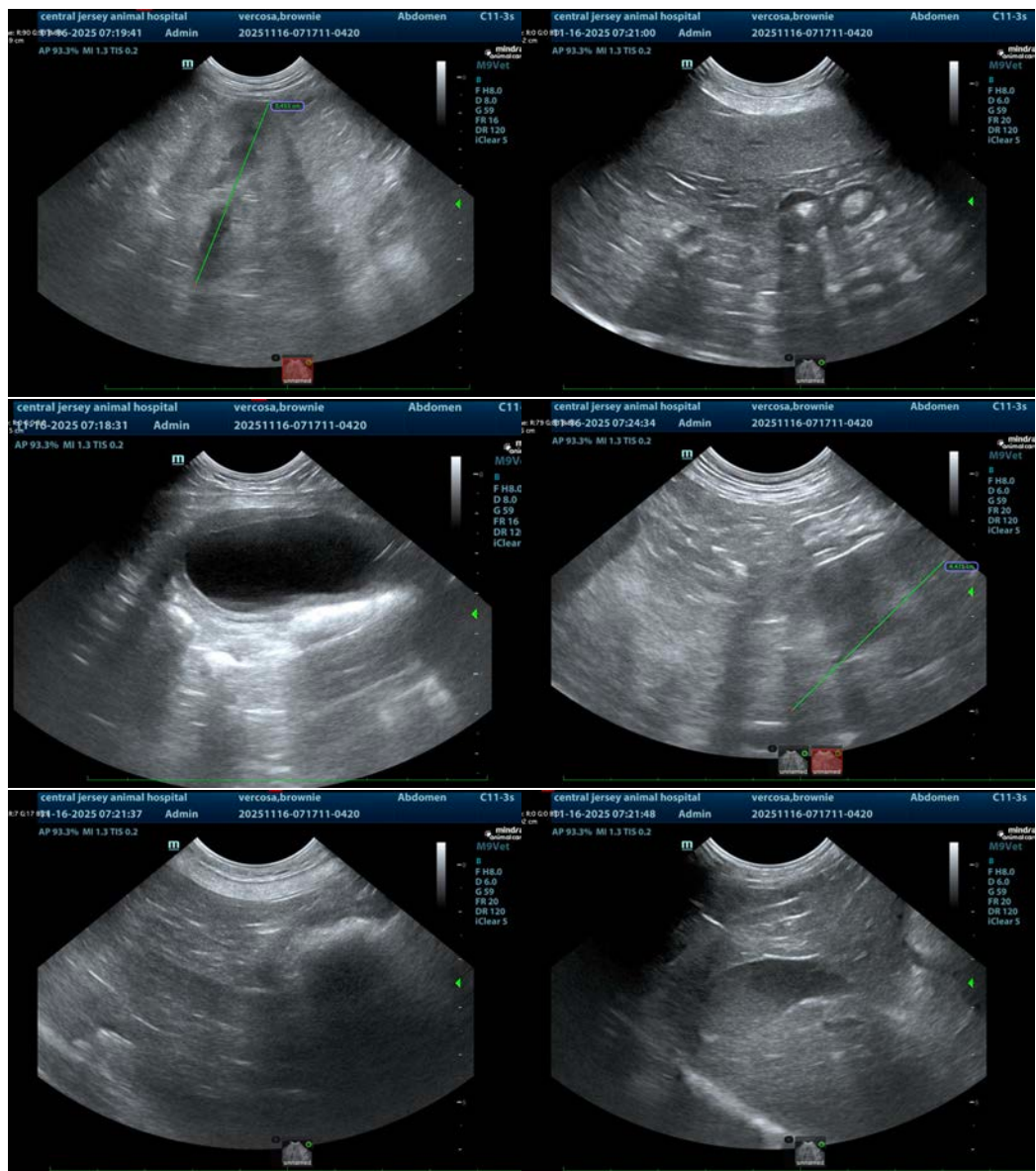
The base and limbs of the **pancreas** were observed to be largely isoechoic to surrounding omental fat. Pancreatic duct and capsular contour were acceptably normal and parenchyma respected normal curvilinear patterns. No overt evidence of active inflammatory or neoplastic disease was noted.

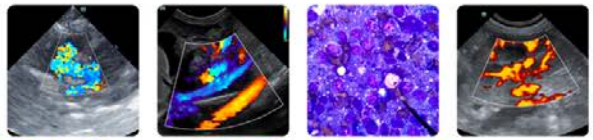
## ULTRASONOGRAPHIC FINDINGS

- Full stomach, unremarkable abdomen otherwise.

## INTERPRETATION OF THE FINDINGS & FURTHER RECOMMENDATIONS

No evidence of pathology. If adrenal disease is suspected, further imaging under sedation indicated.





## PATIENT

Brownie Vercosa

## SPECIES

Canine

## BREED

Dachshund

## SEX

Neutered Male

## AGE

6 Years

## WEIGHT

30 lbs

## INTERPRETED BY

Eric Lindquist, DMV,  
DABVP (CFM), Cert.  
IVUSS

## IMAGING PERFORMED BY

Dr. Jeremiah Gabriel

## HOSPITAL NAME

Central Jersey Animal  
Hospital

## REFERRING VET

Dr. Jeremiah Gabriel

## INVOICE

71870

## DATE

11/16/25

The information and recommendations provided are based on the images presented by the referring veterinarian/sonographer. No evaluation can be communicated regarding pathology that was not visible in the image/video clips provided.

Thank you for this referral. If the clinical or image interpretation does not parallel your findings or if I can be of any further assistance please contact me.

**Eric Lindquist**, DMV, DABVP(CFM), Cert. IVUSS,  
CEO, Owner, Founder -- SonoPath.com  
[info@SonoPath.com](mailto:info@SonoPath.com)