



**PATIENT**

Willow Last Resort  
Rescue

**SPECIES**

Canine

**BREED**

Chi X

**SEX**

Spayed Female

**AGE**

2 Years

**WEIGHT**

18.7 Pounds

**INTERPRETED BY**

Eric Lindquist, DMV

DABVP, Cert. IVUSS

**IMAGING PERFORMED BY**

Jenn

**HOSPITAL NAME**

Rockaway AH

**REFERRING VET**

Dr. Gannon

**INVOICE**

42729

**DATE**

11/16/22

**PRESENTING CLINICAL SIGNS**

re check on R sided CHF secondary to HW HW treated in summer 2022 Ascites has acutely worsened previous u/s on 4/22 shows R sided heart failure and volume overload , tricuspid insufficiency subnormal L heart size pleural effusion, passive congestion liver failure Current meds Sildenafil 10 mg BID Lasix 15 mg SID Spironolactone 12.5 mg BID Enalapril 5mg BID

**ULTRASONOGRAPHIC EXAMINATION OF THE HEART**

CANINE CARDIAC PARAMETERS	MR VMAX (m/s)	TR VMAX (m/s)	LA/AO (Boon method)	LA/AO (Heart Base; Swe)	FS (%)	EF (%)	EPSS (cm)
NORMAL PARAMETER	4.5-5.5	<2.7	1.3	<1.6	28-40	40-100	<0.6
PATIENT			1.2	1.3			NM
CANINE CARDIAC PARAMETERS	HR (BPM)	AV VMAX (m/s)	PV MAX (m/s)	BODY WEIGHT (kg)	LA 2D short axis Base view (cm)	LVIDd Avg; 2D and m-mode short axis (cm)	LVIDs Avg; 2D and m-mode short axis (cm)
NORMAL PARAMETER	50-100	0.7-1.7	0.7-1.6	BELOW	BELOW	BELOW	BELOW
PATIENT		1.0			2.5		

**Cardiac Presentation**

The cardiac presentation presented severe volume overload and dilation of the right atrium and right ventricle. Tricuspid insufficiency noted.

Ascites noted with dilated hepatic veins and chronic hepatic changes.

**ULTRASONOGRAPHIC FINDINGS**

- Right-sided heart failure
- Tricuspid insufficiency

**INTERPRETATION OF THE FINDINGS & FURTHER RECOMMENDATIONS**

No evidence of heartworms yet cannot be completely ruled out. Further cardiac evaluation of the pulmonary outflow and tricuspid valve indicated. Recommend continuation of the current protocol with quadrotherapy. However, Sildenafil can be increased by 0.5 mg/kg over the next two weeks. Pimobendan can also be added at 0.3 mg/kg BID. Prognosis long-term is poor.



**PATIENT**

Willow Last Resort  
Rescue

**SPECIES**

Canine

**BREED**

Chi X

**SEX**

Spayed Female

**AGE**

2 Years

**WEIGHT**

18.7 Pounds

**INTERPRETED BY**

Eric Lindquist, DMV  
DABVP, Cert. IVUSS

**IMAGING PERFORMED BY**

Jenn

**HOSPITAL NAME**

Rockaway AH

**REFERRING VET**

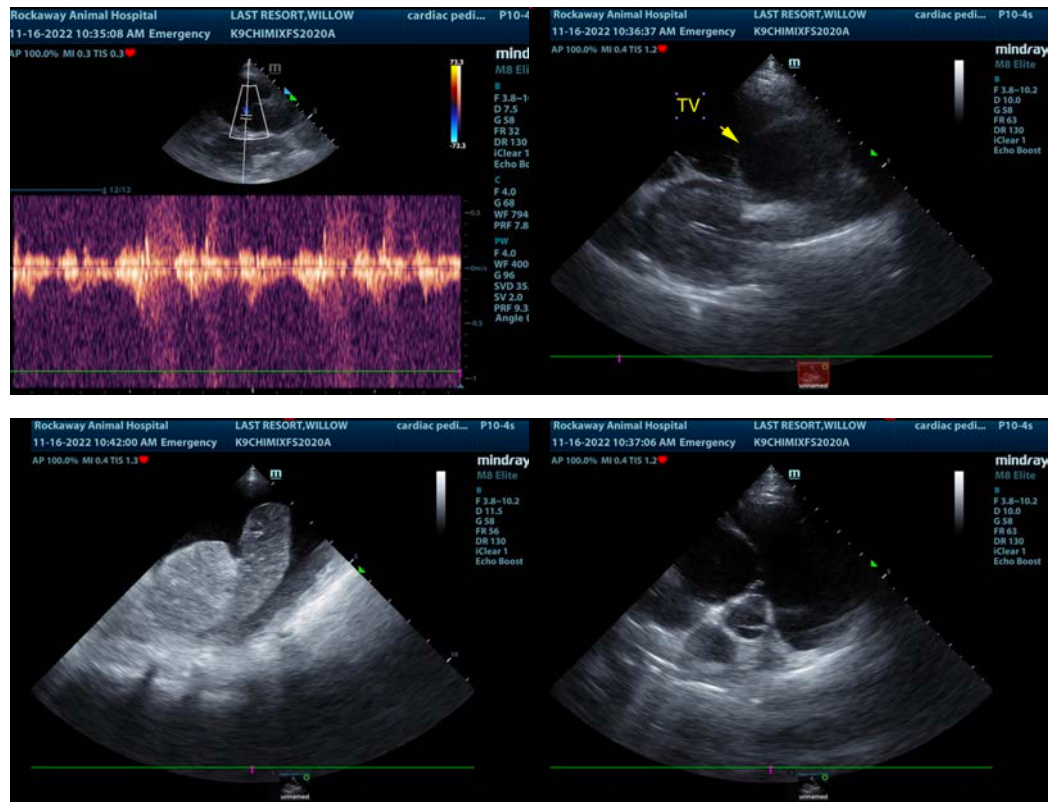
Dr. Gannon

**INVOICE**

42729

**DATE**

11/16/22



The information and recommendations provided are based on the images presented by the referring veterinarian/sonographer. No evaluation can be communicated regarding pathology that was not visible in the image/video clips provided.

Thank you for this referral. If the clinical or image interpretation does not parallel your findings or if I can be of any further assistance please contact me.

Eric Lindquist, DMV, DABVP, Cert. IVUSS, CEO of SonoPath.com

[info@SonoPath.com](mailto:info@SonoPath.com)