



PATIENT

Penny Schneider

SPECIES

Canine

BREED

Boxer

SEX

Spayed Female

AGE

11 ½ years

WEIGHT

83.8 lbs

INTERPRETED BY

Eric Lindquist, DMV
DABVP, Cert. IVUSS

IMAGING PERFORMED BY

Jessica Miller, RDMS

HOSPITAL NAME

Animal Care Center of
Flanders

REFERRING VET

Dr. Hallihan

INVOICE

93147

DATE

11/16/21

PRESENTING CLINICAL SIGNS

History: Arrhythmia noted on routine P.E. - EKG done showed multiple VPCs - concerned for ARVC - rec echo to see systolic function and r/o cardiomyopathy, DCM to decide on meds
Abnormal PE/Chem/CBC/UA Results: Alk Phos 279

ULTRASONOGRAPHIC EXAMINATION OF THE HEART

The echocardiogram in this patient demonstrated normal **left atrial** size based on 3 separate methods of LA evaluation. **Mitral** valve insufficiency was noted at 5.02 m/sec. The **left ventricle** presented thicknesses with linear contour and was not dilated nor restricted. The **myocardium** presented normal echogenicity without subjective evidence of significant fibrotic or ischemic disease. **Contractility** of the ventricular walls was adequate and in normal range for this patient evidenced by the fractional shortening measurement and subjective evaluation of the different regions of the myocardium. The **left ventricular outflow** tract demonstrated normal laminar flow and subjective structural integrity. The **right atrium** and auricle revealed normal size, structure and content. No evidence of masses was noted. **Tricuspid** valvular assessment demonstrated adequate linear morphology and kinesis. The **right ventricle** was of normal size (1/3 diameter of LV), chordae structure, myocardial echogenicity and thickness. **Pulmonary outflow** tract assessment revealed normal valve structure, laminar flow, and diameter (approx.1:1 pa/ao ratio). No visible **pericardial** or free pleura fluid was noted. The cranial **mediastinum and pericardial and extra-cardiac regions** were free of masses in the visible window. Arrhythmogenic activity was noted in this patient.

CANINE CARDIAC PARAMETERS	MR VMAX (m/s)	TR VMAX (m/s)	LA/AO (Boon method)	LA/AO (Heart Base; Swe)	FS (%)	EF (%)	EPSS (cm)
NORMAL PARAMETER	4.5-5.5	<2.7	1.3	<1.6	28-40	40-100	<0.6
PATIENT			1.1	1.15	26	51	0.16
CANINE CARDIAC PARAMETERS	HR (BPM)	AV VMAX (m/s)	PV MAX (m/s)	BODY WEIGHT (kg)	LA (2D short axis Base view) (cm)	LVIDd (Avg; 2D and m-mode short axis) (cm)	LVIDs (Avg; 2D and m-mode short axis) (cm)
NORMAL PARAMETER	50-100	0.7-1.7	0.7-1.6				
PATIENT		2.15	1.39	8.38 lbs	4.5 max	5.96	

ULTRASONOGRAPHIC FINDINGS

Mitral valve insufficiency.
Arrhythmogenic heart.
Boxer cardiomyopathy is likely.



PATIENT

Penny Schneider

SPECIES

Canine

BREED

Boxer

SEX

Spayed Female

AGE

11 ½ years

WEIGHT

83.8 lbs

INTERPRETED BY

Eric Lindquist, DMV
DABVP, Cert. IVUSS

IMAGING PERFORMED BY

Jessica Miller, RDMS

HOSPITAL NAME

Animal Care Center of
Flanders

REFERRING VET

Dr. Hallihan

INVOICE

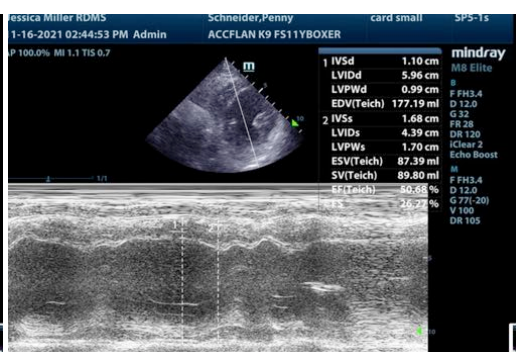
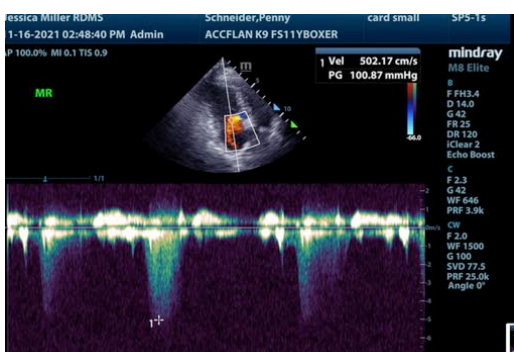
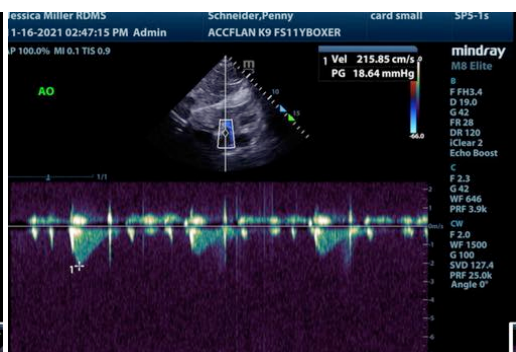
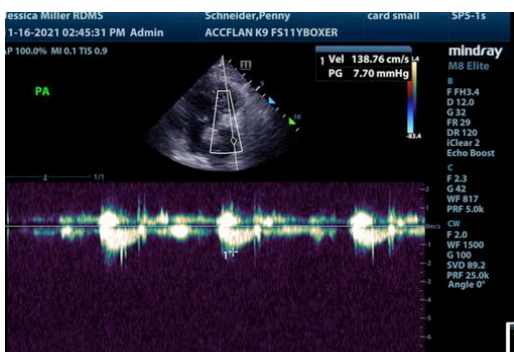
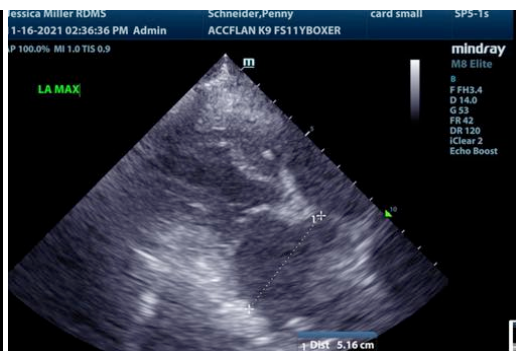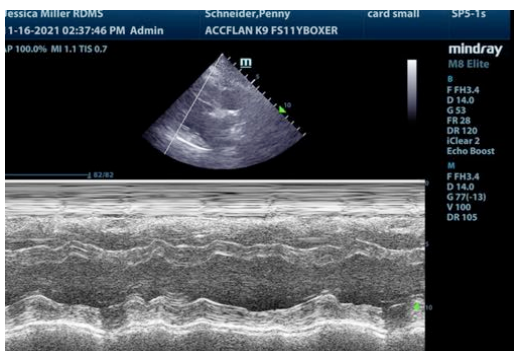
93147

DATE

11/16/21

INTERPRETATION OF THE FINDINGS & FURTHER RECOMMENDATIONS

Structurally and functionally the heart is unremarkable other than minor mitral insufficiency. EKG +/- Holter monitor is warranted. No primary cardiac medications are recommended at this time. However, anti-arrhythmias will be necessary based on EKG/Holter results. Holter monitor can be obtained from our office. Blood pressure measurements are also indicated.





PATIENT

Penny Schneider

SPECIES

Canine

BREED

Boxer

SEX

Spayed Female

AGE

11 ½ years

WEIGHT

83.8 lbs

INTERPRETED BY

Eric Lindquist, DMV
DABVP, Cert. IVUSS

**IMAGING
PERFORMED BY**

Jessica Miller, RDMS

HOSPITAL NAME

Animal Care Center of
Flanders

REFERRING VET

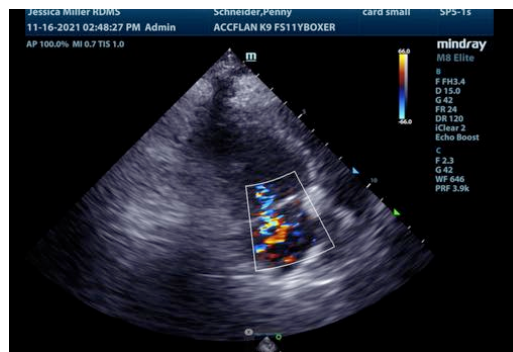
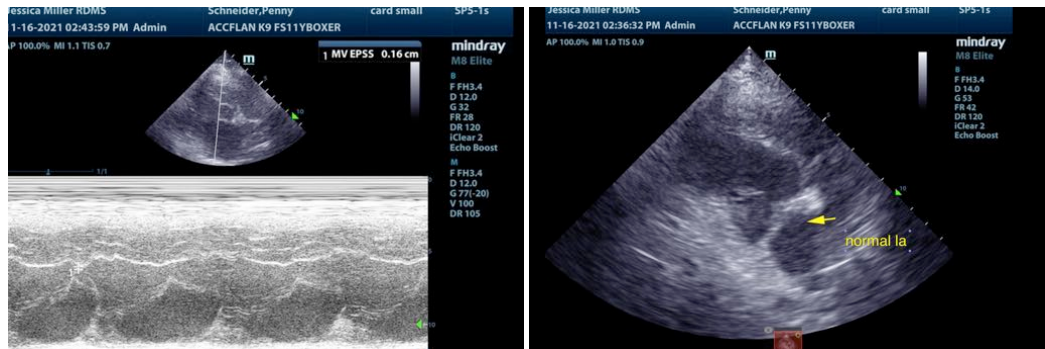
Dr. Hallihan

INVOICE

93147

DATE

11/16/21



The information and recommendations provided are based on the images presented by the referring veterinarian. No evaluation can be communicated regarding pathology that was not visible in the image/video clips provided.

Thank you for this referral. If the clinical or image interpretation does not parallel your findings or if I can be of any further assistance please contact me.

Eric Lindquist, DMV, DABVP, Cert. IVUSS, CEO of SonoPath.com
info@SonoPath.com