



PATIENT

Peewee Valdata

PRESENTING CLINICAL SIGNS

Soft tissue mass on the top of head is growing.

SPECIES

Feline

ULTRASONOGRAPHIC EXAMINATION OF THE ABDOMEN

The frontal aspect of the cranium was imaged and a 5.0 x 2.0 cm deep, uniformly, hypoechoic mass was noted with variable areas of mild vascularity noted on power Doppler assessment. The mass appeared to be attached to the periosteum. Some periosteal reactivity was noted in variable areas. However, mass likely derives from soft tissue and is creating a periosteal effect. Ultrasound-guided FNA was performed without complication. I suspected sarcoma.

BREED

Tabby

SEX

Neutered male

ULTRASONOGRAPHIC FINDINGS

Subcutaneous to facial sarcoma is suspected or other neoplasia with attachment to the periosteum.

AGE

8 years

INTERPRETATION OF THE FINDINGS & FURTHER RECOMMENDATIONS

Clean resection is unlikely in this patient given the periosteal reaction of the frontal bone of the cranium. Oncological evaluation is recommended based on cytology results. Chemotherapy +/- radiation therapy may be appropriate in this patient. Full abdominal sonogram and chest radiographs are warranted if not already performed to assess for related disease.

INTERPRETED BY

Eric Lindquist, DMV
DABVP, Cert. IVUSS

IMAGING PERFORMED BY

Eric Lindquist, DMV
DABVP, Cert. IVUSS

HOSPITAL NAME

Oakland AH

REFERRING VET

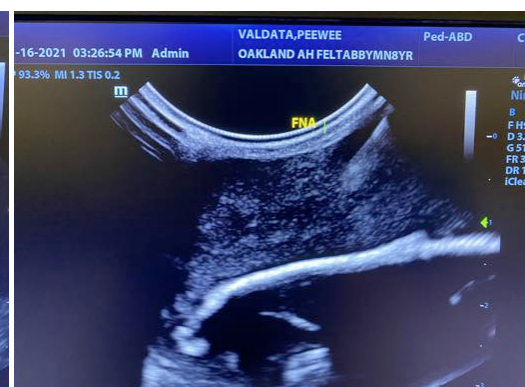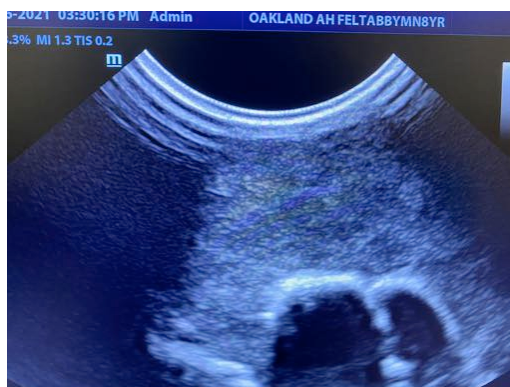
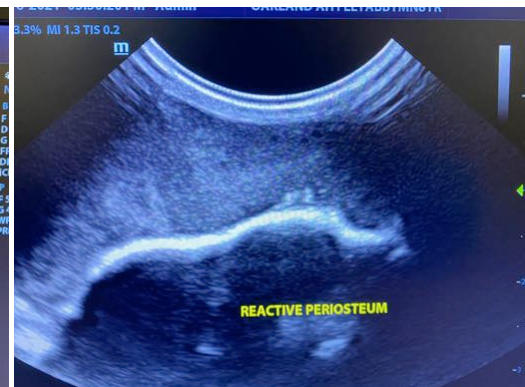
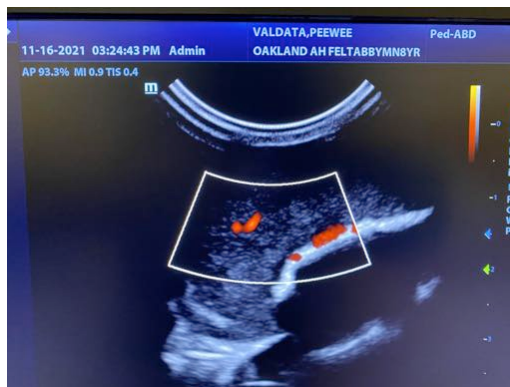Dr. Gordon

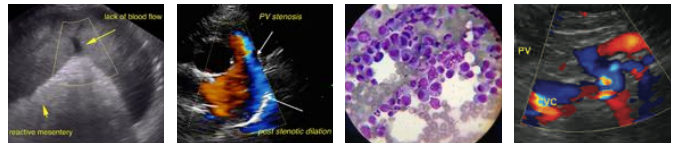
INVOICE

93118

DATE

11/16/21





PATIENT

Peewee Valdata

SPECIES

Feline

BREED

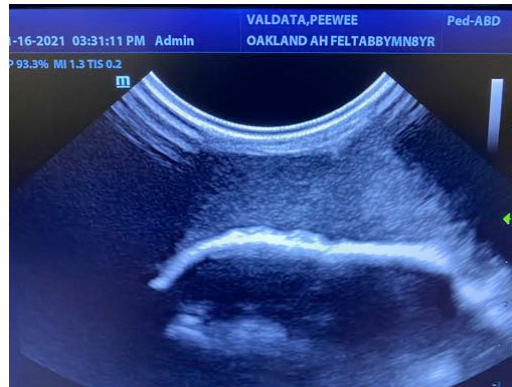Tabby

SEX

Neutered male

AGE

8 years



The information and recommendations provided are based on the images presented by the referring veterinarian. No evaluation can be communicated regarding pathology that was not visible in the image/video clips provided.

Thank you for this referral. If the clinical or image interpretation does not parallel your findings or if I can be of any further assistance please contact me.

Eric Lindquist, DMV, DABVP, Cert. IVUSS, CEO of SonoPath.com
Info@SonoPath.com

INTERPRETED BY

Eric Lindquist, DMV
DABVP, Cert. IVUSS

IMAGING PERFORMED BY

Eric Lindquist, DMV
DABVP, Cert. IVUSS

HOSPITAL NAME

Oakland AH

REFERRING VET

Dr. Gordon

INVOICE

93118

DATE

11/16/21