



PATIENT PRESENTING CLINICAL SIGNS

Milo Kwon
History: hematuria. 8 yr old intact shihtzu. not antibiotic responsive. ua/ucs not consistent with uti. on u/s prostate looks enlarged and urine has sludge. rad rules out urethral stones and bladder stones. r/o prostatitis

SPECIES

Canine

ULTRASONOGRAPHIC EXAMINATION OF THE ABDOMEN

BREED Urinary System

Shih Tzu
The **urinary bladder** revealed a minor amount of debris and a trace amount of sand. Slight, cystic changes were noted at the caudal aspect of the prostate. Minor, apical ventral wall thickening was noted.

SEX

The prostate measured 1.73 cm and was uniform.

Male

The **kidneys** revealed normal size and structure, corticomedullary definition and ratio for this age. The cortices presented largely uniform texture with normal echogenic relationship to liver and spleen.

AGE

Medullary structure differed distinctly from the cortex and no evidence of pelvic dilation was present. The capsules were acceptably uniform without significant irregularities.

7 years

WEIGHT ULTRASONOGRAPHIC FINDINGS

10.5 lbs Slight bladder sand and debris.

Minor BPH prostate with minor cyst or possible slight abscessation.

INTERPRETED BY

Eric Lindquist, DMV
DABVP, Cert. IVUSS

INTERPRETATION OF THE FINDINGS & FURTHER RECOMMENDATIONS

Neutering should be considered in this patient. Reduction of the prostatic size theoretically would allow for more complete liberation of the urinary content.

IMAGING PERFORMED BY

Marcela Salas

HOSPITAL NAME

Tenaflly VC

REFERRING VET

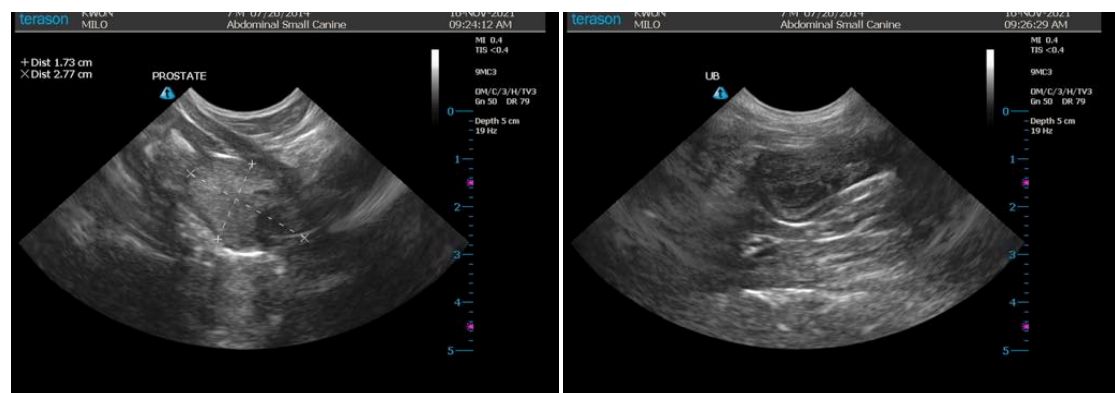
Dr. Han

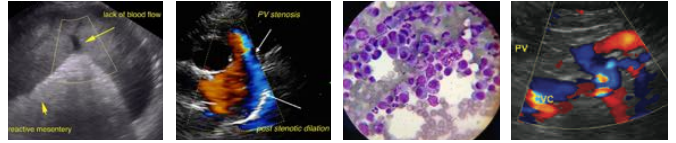
INVOICE

93160

DATE

11/16/21





PATIENT

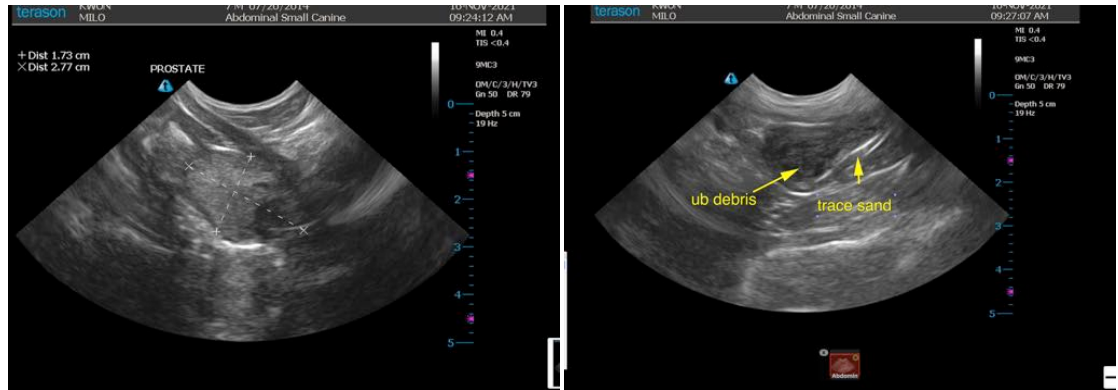Milo Kwon

SPECIES

Canine

BREED

Shih Tzu



SEX

Male

AGE

7 years

WEIGHT

10.5 lbs

The information and recommendations provided are based on the images presented by the referring veterinarian. No evaluation can be communicated regarding pathology that was not visible in the image/video clips provided.

Thank you for this referral. If the clinical or image interpretation does not parallel your findings or if I can be of any further assistance please contact me.

Eric Lindquist, DMV, DABVP, Cert. IVUSS, CEO of SonoPath.com
info@SonoPath.com

INTERPRETED BY

Eric Lindquist, DMV
DABVP, Cert. IVUSS

IMAGING PERFORMED BY

Marcela Salas

HOSPITAL NAME

Tenaflly VC

REFERRING VET

Dr. Han

INVOICE

93160

DATE

11/16/21