



PATIENT

Cooper Kennedy

SPECIES

Canine

BREED

Lab Mix

SEX

Neutered Male

AGE

2011

WEIGHT

67.25 lbs

INTERPRETED BY

Eric Lindquist, DMV
DABVP, Cert IVUSS

**IMAGING
PERFORMED BY**

Denise Bruno, LVT,
RDMS

HOSPITAL NAME

Brooklyn Heights VH

REFERRING VET

Dr. Thomson

INVOICE

93169

DATE

11/16/21

PRESENTING CLINICAL SIGNS

History: Smooth mass palpated along wall of left side of rectum (inside rectum). Not able to fully defecate, not the anal gland

Labs + Radiographs attached

ULTRASONOGRAPHIC EXAMINATION OF THE ABDOMEN

Urinary System

An undifferentiated, hypoechoic 5.8 cm mass was noted in the pelvic inlet. The mass appears isolated and is likely of lymph node origin. The **urinary bladder** and residual prostate appeared unremarkable. The residual prostate measured 1.0 cm.

The **kidneys** revealed normal size and structure, corticomedullary definition and ratio for this age. The cortices presented largely uniform texture with normal echogenic relationship to liver and spleen. Medullary structure differed distinctly from the cortex and no evidence of pelvic dilation was present. The capsules were acceptably uniform without significant irregularities. The right kidney measured 7.0 cm. The left kidney measured 6.49 cm.

Adrenal Glands

Both **adrenal glands** were visualized and recognized as having normal shape, size, position and echogenicity for this breed. The phrenic vasculature, glandular echogenicity and detail were unremarkable. Capsule, cortex, and medullary definition were normal for this age patient. The left adrenal gland measured 2.47 x 0.67 cm at the caudal pole and 0.46 cm at the cranial pole.

Spleen

The **spleen** presented a smooth homogeneous parenchyma hyperechoic to liver and renal cortical parenchyma. The capsule was smooth without noticeable expansion or deviation from within the spleen or adjacent pathology. The splenic vasculature demonstrated normal volume without signs of congestion or thrombosis. No sonographic evidence of acute or chronic inflammatory, neoplastic, or infarctual changes was noted.

Liver

The **liver** revealed slightly increased portal markings, yet was otherwise unremarkable. The gallbladder presented acceptably thin walls with primarily anechoic content. The cystic and common bile ducts were normal. No pathological hepatic lymphadenopathy was evident.

Gastrointestinal

Examination of the **gastrointestinal tract** revealed a stomach and intestine free of stasis, of normal wall thickness, acceptable curvilinear mural detail, and peristaltic activity. Small and large intestine demonstrated normal luminal chyme and stool consistency respectively. No obstructive or overt infiltrative disease was noted. No associated abnormal lymphatic activity was noted.



PATIENT

Pancreas

Cooper Kennedy

The base and limbs of the **pancreas** were observed to be largely isoechoic to surrounding omental fat. Pancreatic duct and capsular contour were acceptably normal and parenchyma respected normal curvilinear patterns. No overt evidence of active inflammatory or neoplastic disease was noted.

SPECIES

Canine

ULTRASONOGRAPHIC FINDINGS

BREED

Lab Mix

Undifferentiated mass in the pelvis. Suspect lymph node origin; however, the exact origin cannot be defined.

SEX

Neutered Male

INTERPRETATION OF THE FINDINGS & FURTHER RECOMMENDATIONS

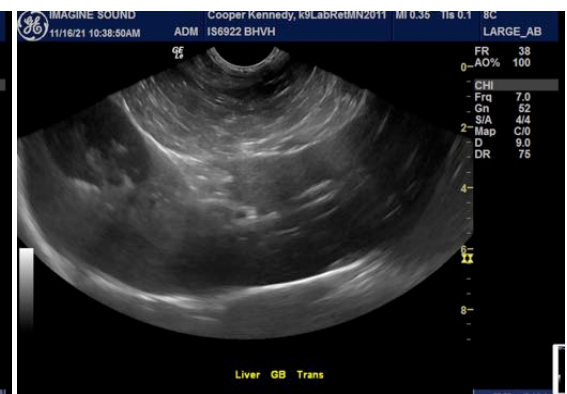
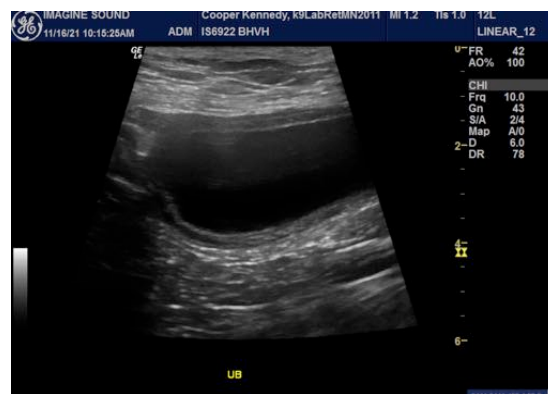Pelvic CT would be ideal. No other organs appear to be affected. Treatment is recommended to be based on cytology results.

AGE

2011

WEIGHT

67.25 lbs

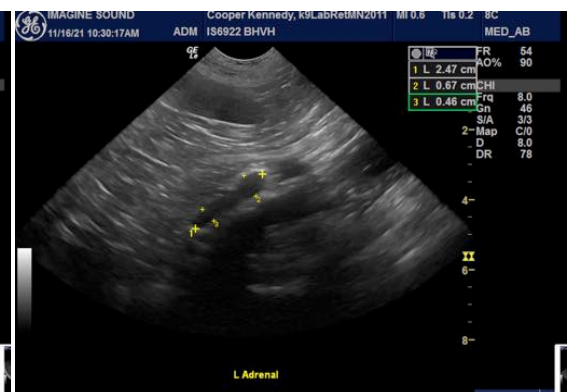
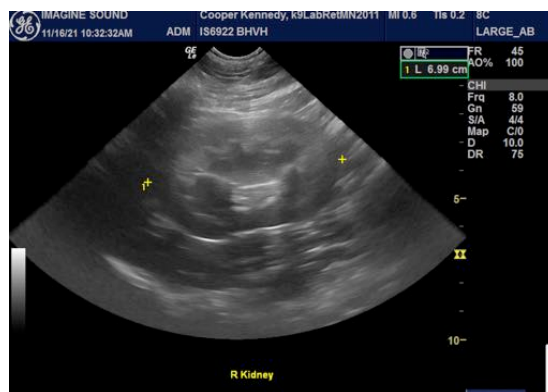


INTERPRETED BY

Eric Lindquist, DMV
DABVP, Cert IVUS

IMAGING PERFORMED BY

Denise Bruno, LVT,
RDMS



HOSPITAL NAME

Brooklyn Heights VH

REFERRING VET

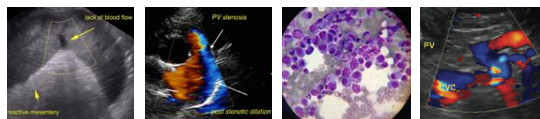
Dr. Thomson

INVOICE

93169

DATE

11/16/21



PATIENT

Cooper Kennedy

SPECIES

Canine

BREED

Lab Mix

SEX

Neutered Male

AGE

2011

WEIGHT

67.25 lbs

INTERPRETED BY

Eric Lindquist, DMV
DABVP, Cert IVUSS

**IMAGING
PERFORMED BY**

Denise Bruno, LVT,
RDMS

HOSPITAL NAME

Brooklyn Heights VH

REFERRING VET

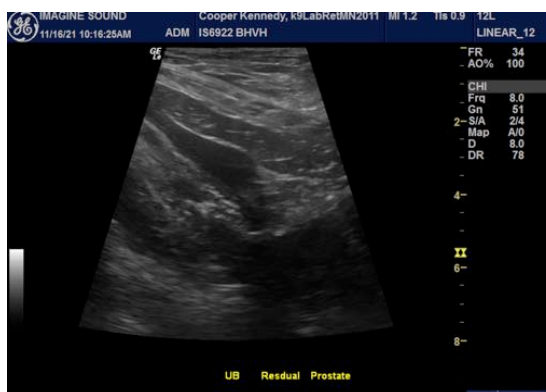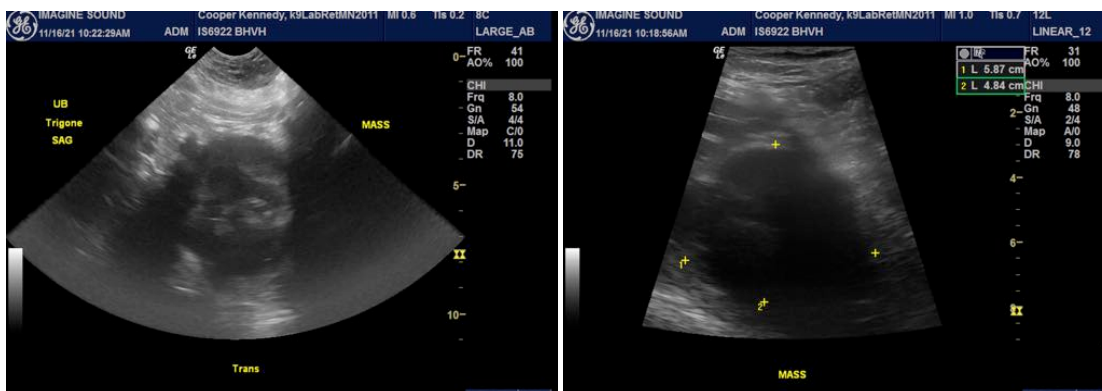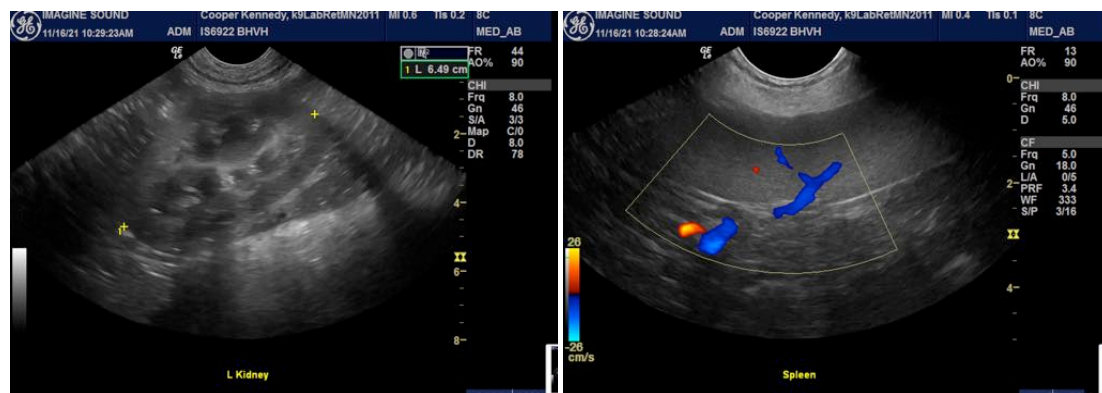Dr. Thomson

INVOICE

93169

DATE

11/16/21



The information and recommendations provided are based on the images presented by the referring veterinarian. No evaluation can be communicated regarding pathology that was not visible in the image/video clips provided.

Thank you for this referral. If the clinical or image interpretation does not parallel your findings or if I can be of any further assistance please contact me.

Eric Lindquist, DMV, DABVP, Cert. IVUSS, CEO of SonoPath.com
Eric.Lindquist@SonoPath.com