



PATIENT PRESENTING CLINICAL SIGNS

Cleo Tam
SPECIES History: Initially presented for coughing 10/26, rads showed large L sided cardiomegaly. Placed on Lasix - initially improved now has increased coughing w/phlegm. Fine crackles 10/26 - none present today.
Canine Abnormal PE/Chem/CBC/UA Results: 10/27 BW: ALBUMIN: 2.5L, CHOLESTEROL: 127L, MONOCYTE: 1732H

BREED ULTRASONOGRAPHIC EXAMINATION OF THE HEART

Chihuahua Mix
SEX The **left atrium** and **left ventricle** presented moderate volume overload. The cranial and caudal **mitral** valve leaflets presented vegetative thickening consistent with endocardiosis. Doppler indicated measurable insufficiency. The **myocardium** presented normal echogenicity without subjective evidence of significant fibrotic or ischemic disease. **Contractility** of the ventricular walls was adequate and in normal range for this patient evidenced by the fractional shortening measurement and subjective evaluation of the different regions of the myocardium. The **left ventricular outflow** tract demonstrated normal laminar flow and subjective structural integrity. The **right atrium** and auricle revealed normal size, structure and content. No evidence of masses was noted or chamber overload. **Tricuspid** valvular assessment demonstrated adequate linear morphology. The **right ventricle** was of normal size (1/3 diameter of LV), chordae structure, myocardial echogenicity and thickness. **Pulmonic** tract assessment revealed normal valve structure, laminar flow, and diameter (approx.1:1 pa/ao ratio). No visible **pericardial** or free pleura fluid was noted. No echographically detectable evidence of infiltrative disease was visible. The cranial **mediastinum** and **pericardial** regions were free of masses in the visible window.
Spayed Female
AGE 10 years
WEIGHT 8.88 lbs

INTERPRETED BY

Eric Lindquist, DMV
DABVP, Cert. IVUSS

IMAGING PERFORMED BY

Dr. Striano Kaplan

HOSPITAL NAME

Ramsey VH

REFERRING VET

Dr. Striano Kaplan

CANINE CARDIAC PARAMETERS	MR VMAX (m/s)	TR VMAX (m/s)	LA/AO (Boon method)	LA/AO (Heart Base; Swe)	FS (%)	EF (%)	EPSS (cm)
NORMAL PARAMETER	4.5-5.5	<2.7	1.3	<1.6	28-40	40-100	<0.6
PATIENT			1.4	2.0	25	50	0.2
CANINE CARDIAC PARAMETERS	HR (BPM)	AV VMAX (m/s)	PV MAX (m/s)	BODY WEIGHT	LA (2D short axis Base view) (cm)	LVIDd (Avg; 2D and m-mode short axis) (cm)	LVIDs (Avg; 2D and m-mode short axis) (cm)
NORMAL PARAMETER	50-100	0.7-1.7	0.7-1.6				
PATIENT		1.3	0.9	8.88 lbs	3.0 max	3.36	

INVOICE ULTRASONOGRAPHIC FINDINGS

93158 Advanced stage B2 valvular disease.

DATE

11/16/21



PATIENT

Cleo Tam

SPECIES

Canine

INTERPRETATION OF THE FINDINGS & FURTHER RECOMMENDATIONS

I recommend adding Pimobendan at 0.3 mg/kg b.i.d., Spironolactone 1-2 mg/kg b.i.d. and continuation of the Lasix therapy. Ace inhibitor therapy can be considered especially if systolic pressure is > 160. A recheck echocardiogram is recommended in 3 weeks. After treatment I recommend assessment of BUN, creatinine, USG, chest radiographs and blood pressure as well as clinical exam is ideal in 7-10 days. Basal respiratory rate should be <20/min.

BREED

Chihuahua Mix

SEX

Spayed Female

AGE

10 years

WEIGHT

8.88 lbs

INTERPRETED BY

Eric Lindquist, DMV
DABVP, Cert. IVUS

IMAGING PERFORMED BY

Dr. Striano Kaplan

HOSPITAL NAME

Ramsey VH

REFERRING VET

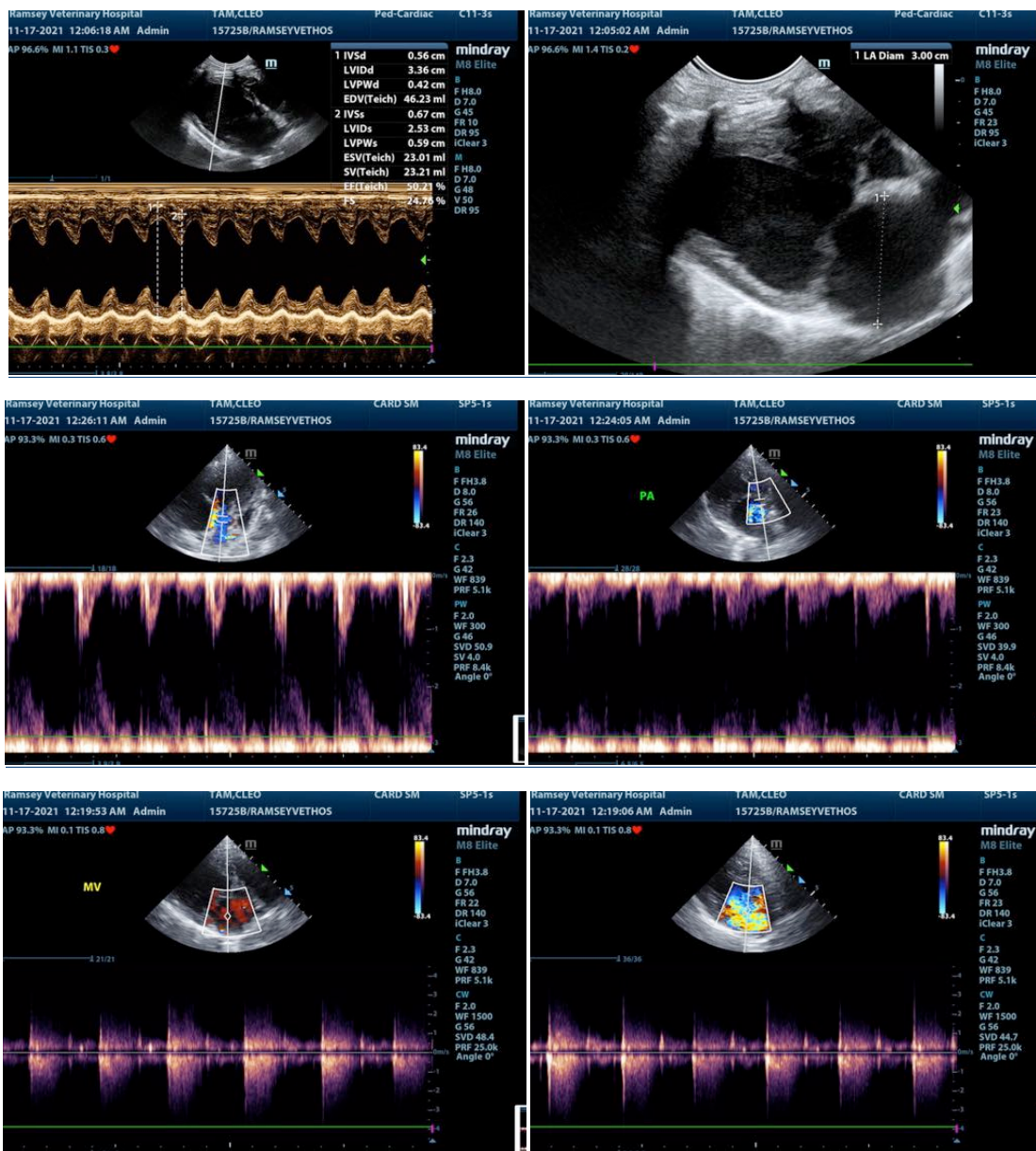
Dr. Striano Kaplan

INVOICE

93158

DATE

11/16/21





PATIENT

Cleo Tam

SPECIES

Canine

BREED

Chihuahua Mix

SEX

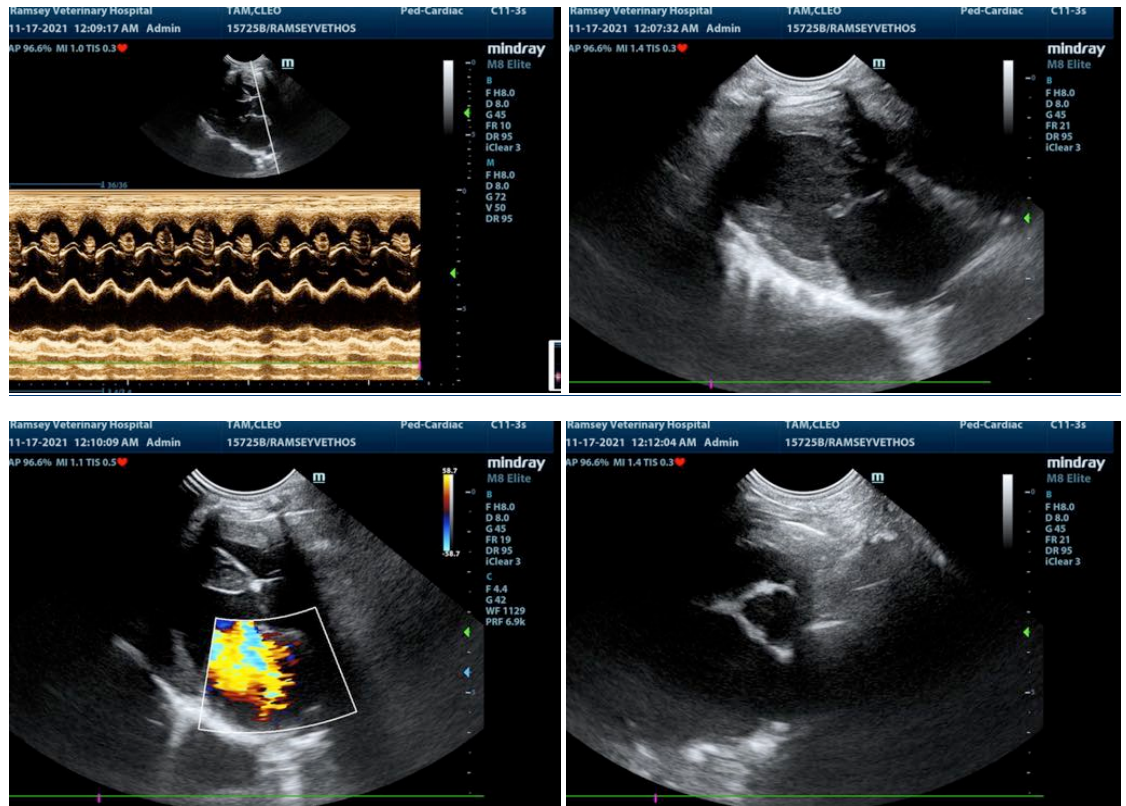
Spayed Female

AGE

10 years

WEIGHT

8.88 lbs



INTERPRETED BY

Eric Lindquist, DMV
DABVP, Cert. IVUSS

IMAGING PERFORMED BY

Dr. Striano Kaplan

HOSPITAL NAME

Ramsey VH

REFERRING VET

Dr. Striano Kaplan

INVOICE

93158

DATE

11/16/21

The information and recommendations provided are based on the images presented by the referring veterinarian. No evaluation can be communicated regarding pathology that was not visible in the image/video clips provided.

Thank you for this referral. If the clinical or image interpretation does not parallel your findings or if I can be of any further assistance please contact me.

Eric Lindquist, DMV, DABVP, Cert. IVUSS, CEO of SonoPath.com
info@SonoPath.com