

PATIENT

Charlie Mauriello

SPECIES

Canine

BREED

Cavalier King Charles

SEX

Neutered male

AGE

10 years

WEIGHT

35.4 lbs

INTERPRETED BY

Eric Lindquist, DMV
DABVP, Cert. IVUSS

IMAGING PERFORMED BY

Kelly Vazquez, CVT

HOSPITAL NAME

Ramapo Valley AH

REFERRING VET

Dr. Duhr

INVOICE

93138

DATE

11/16/21

PRESENTING CLINICAL SIGNS

History: Follow up from echo on 6/4/21 which showed improved cardiac parameters since placing him on 3.75mgs Vetmedin BID.
Abnormal PE/Chem/CBC/UA Results: CBC/Chem: WNL (1/5/21). U/A: WNL, USG 1.016 (1/5/21).

ULTRASONOGRAPHIC EXAMINATION OF THE HEART

The echocardiogram in this patient presented normalized internal volumes of the left atrium and left ventricle. The contractility appeared adequate. Mitral and tricuspid insufficiency are persistent, yet appear to be compensated at this time. Mitral insufficiency on color flow Doppler demonstrated complete filling of the left atrium. This is similar to the prior sonogram. Trivial tricuspid insufficiency was noted and measured 2.0 m/sec. There was no pericardial or pleural effusion.

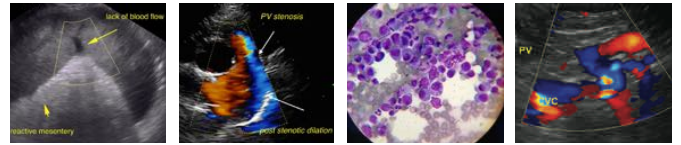
CANINE	MR	TR	LA/AO	LA/AO	FS	EF	EPSS
CARDIAC PARAMETERS	VMAX (m/s)	VMAX (m/s)	(Boon method)	(Heart Base; Swe)	(%)	(%)	(cm)
NORMAL PARAMETER	4.5-5.5	<2.7	1.3	<1.6	28-40	40-100	<0.6
PATIENT	6.5		1.1	1.3	31	59	0.1
CANINE	HR	AV	PV	BODY WEIGHT	LA	LVIDd	LVIDs
CARDIAC PARAMETERS	(BPM)	VMAX (m/s)	MAX (m/s)		2D short axis Base view (cm)	Avg; 2D and m-mode short axis (cm)	Avg; 2D and m-mode short axis (cm)
NORMAL PARAMETER	50-100	0.7-1.7	0.7-1.6				
PATIENT	111		1.1	35.4 lbs	3.26	3.16	

ULTRASONOGRAPHIC FINDINGS

Compensated stage B2 valvular disease on current protocol.

INTERPRETATION OF THE FINDINGS & FURTHER RECOMMENDATIONS

A recheck echocardiogram is recommended in 6-12 months or earlier if murmur grade increases. I recommend to monitor blood pressure measurements and renal values are important in this patient.



PATIENT

Charlie Mauriello

SPECIES

Canine

BREED

Cavalier King Charles

SEX

Neutered male

AGE

10 years

WEIGHT

35.4 lbs

INTERPRETED BY

Eric Lindquist, DMV
DABVP, Cert. IVUSS

IMAGING PERFORMED BY

Kelly Vazquez, CVT

HOSPITAL NAME

Ramapo Valley AH

REFERRING VET

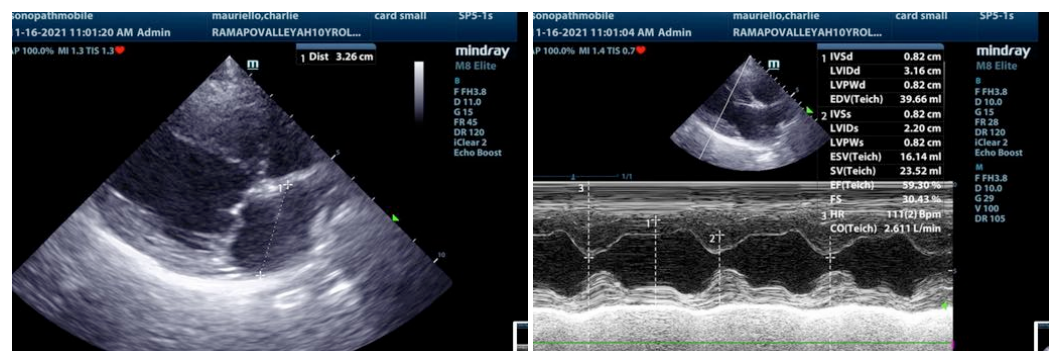
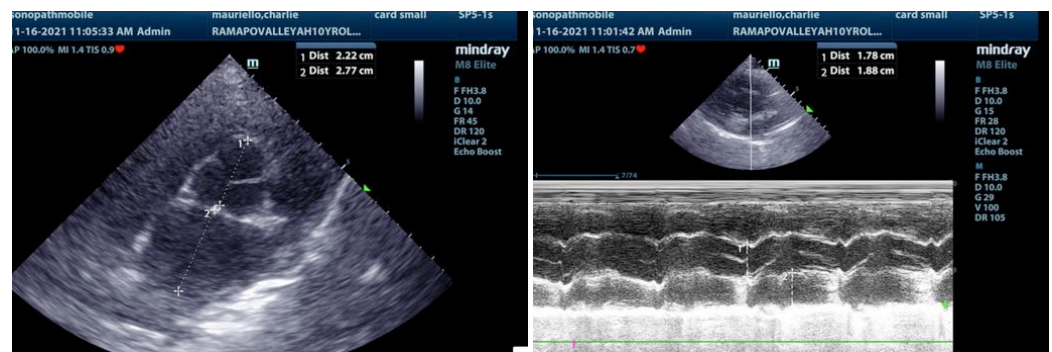
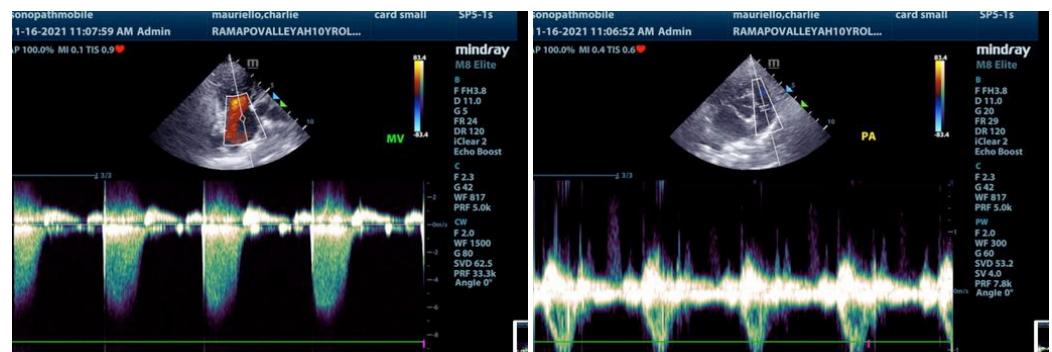
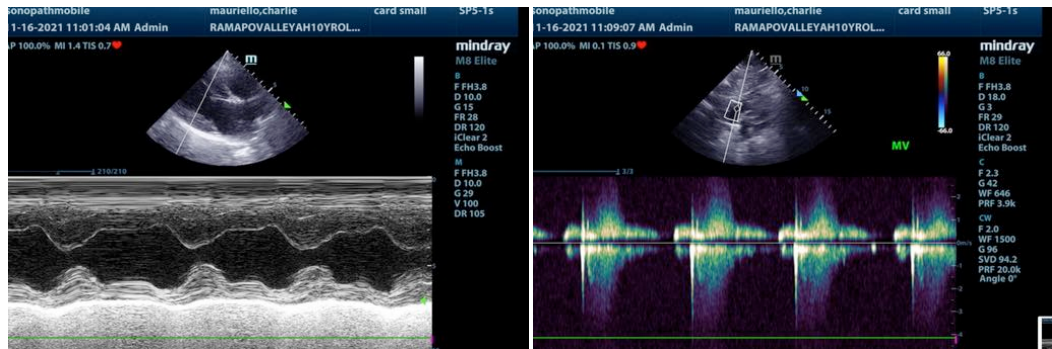
Dr. Duhr

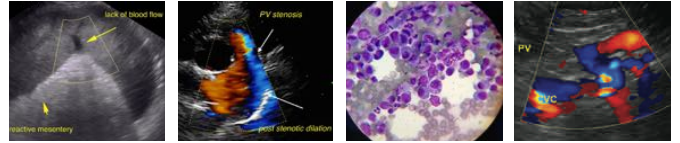
INVOICE

93138

DATE

11/16/21





PATIENT

Charlie Mauriello

SPECIES

Canine

BREED

Cavalier King Charles

SEX

Neutered male

AGE

10 years

WEIGHT

35.4 lbs

INTERPRETED BY

Eric Lindquist, DMV
DABVP, Cert. IVUSS

**IMAGING
PERFORMED BY**

Kelly Vazquez, CVT

HOSPITAL NAME

Ramapo Valley AH

REFERRING VET

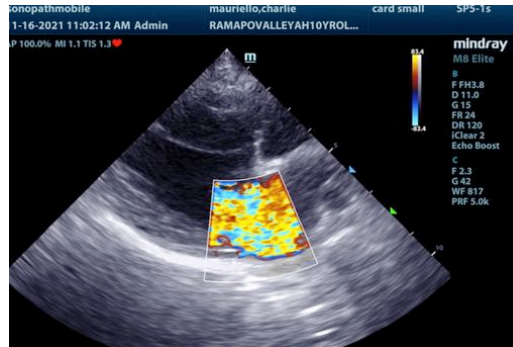
Dr. Duhr

INVOICE

93138

DATE

11/16/21



The information and recommendations provided are based on the images presented by the referring veterinarian. No evaluation can be communicated regarding pathology that was not visible in the image/video clips provided.

Thank you for this referral. If the clinical or image interpretation does not parallel your findings or if I can be of any further assistance please contact me.

Eric Lindquist, DMV, DABVP, Cert. IVUSS, CEO of SonoPath.com
info@SonoPath.com