SonoPath
Clinical Sonography & Telecytology

EDUCATIONAL TELECONSULTATION SERVICES™

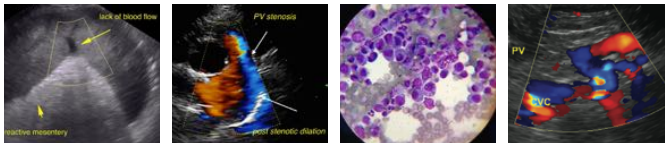

SonoPath.com™
1-800-838-4268 info@sonopath.com

PATIENT

Tebow Graham

SPECIES

Canine

BREED

Cavalier King Charles Spaniel

SEX

Neutered male

AGE

11 years

WEIGHT

15 lbs

INTERPRETED BY

Eric Lindquist, DMV DABVP, Cert. IVUSS

IMAGING PERFORMED BY

Dr. Lanz

HOSPITAL NAME

New Holland VH

REFERRING VET

Dr. Lanz

INVOICE

42531

DATE

11/15/22

PRESENTING CLINICAL SIGNS

History: 11yo MN cavalier king charles spaniel presenting for regurgitation throughout the day for the past 6mo and collapsing yesterday. Grade 3/6 HM auscultated on PE, increased RR >30 during rest. Abnormal PE/Chem/CBC/UA Results: Enlarged heart with tracheal elevation and pulmonary edema. CBC/chem/UA: pending

ULTRASONOGRAPHIC EXAMINATION OF THE ABDOMEN

Urinary System

The **urinary bladder**, trigone, and pelvic urethra presented normal thicknesses and normal tone. The ureters were not visible which is normal. No uroliths or sediment were visualized and anechoic urine was present. No evidence of inflammatory or neoplastic changes was noted. Ureteral papillae were normal.

The residual prostate measured 1.0 cm.

The **right kidney** revealed normal size and structure, corticomedullary definition and ratio for this age. The cortices presented largely uniform texture with normal echogenic relationship to liver and spleen. Medullary structure differed distinctly from the cortex and no evidence of pelvic dilation was present. The capsule was acceptably uniform without significant irregularities. The right kidney measured 3.84 cm. The region of the left kidney was imaged with no evidence of pathology.

Adrenal Glands

The right adrenal gland appeared subnormal in size and measured 0.4 cm. The left adrenal gland was visible at 0.4 cm and appeared somewhat flattened.

Spleen

The visible **spleen** was uniform, yet volume contracted.

Liver

The **liver** images submitted revealed subjectively normal liver size, contour, and structure. Parenchymal echogenicity was naturally coarse and hypoechoic to the spleen. Vascular and biliary tracts were of normal volume with no evidence of congestion. The gallbladder presented acceptably thin walls with primarily anechoic content. The cystic and common bile ducts were normal. No pathological hepatic lymphadenopathy was evident. No overt structural evidence of inflammatory, infiltrative or regenerative pathology was evident. Pleural effusion was noted through the diaphragm.

Gastrointestinal

There was some residual chyme and gas was noted in the **stomach**, yet not pathological. This is consistent with end post prandial presentation. Transit of chyme into the small intestine was normal. The gastric fundus revealed some retention of ingesta obscuring some visibility. Curvilinear patterns were maintained throughout the GI tract. No evidence of pathology. Small and large intestine

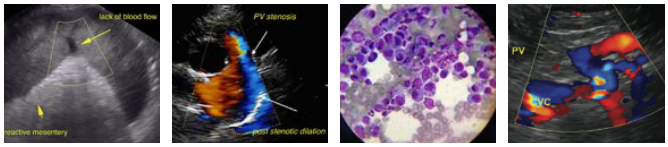

SonoPath.com™
1-800-838-4268 info@sonopath.com

PATIENT

Tebow Graham

SPECIES

Canine

BREED

Cavalier King Charles Spaniel

SEX

Neutered male

AGE

11 years

WEIGHT

15 lbs

INTERPRETED BY

Eric Lindquist, DMV DABVP, Cert. IVUSS

IMAGING PERFORMED BY

Dr. Lanz

HOSPITAL NAME

New Holland VH

REFERRING VET

Dr. Lanz

INVOICE

42531

DATE

11/15/22

demonstrated normal luminal chyme and stool consistency respectively. No obstructive or overt infiltrative disease was noted. No associated abnormal lymphatic activity was noted.

Pancreas

The base and limbs of the **pancreas** were observed to be largely isoechoic to surrounding omental fat. Pancreatic duct and capsular contour were acceptably normal and parenchyma respected normal curvilinear patterns. No overt evidence of active inflammatory or neoplastic disease was noted.

ULTRASONOGRAPHIC FINDINGS

Non-visible left kidney, possible aplasia.

Partially full stomach, likely postprandial presentation.

INTERPRETATION OF THE FINDINGS & FURTHER RECOMMENDATIONS

Given the pleural effusion I recommend thoracic work-up in this patient. There was no obvious abdominal pathology. Chest CT may be the best option in this patient if the echocardiogram does not reveal clinical cardiac disease.

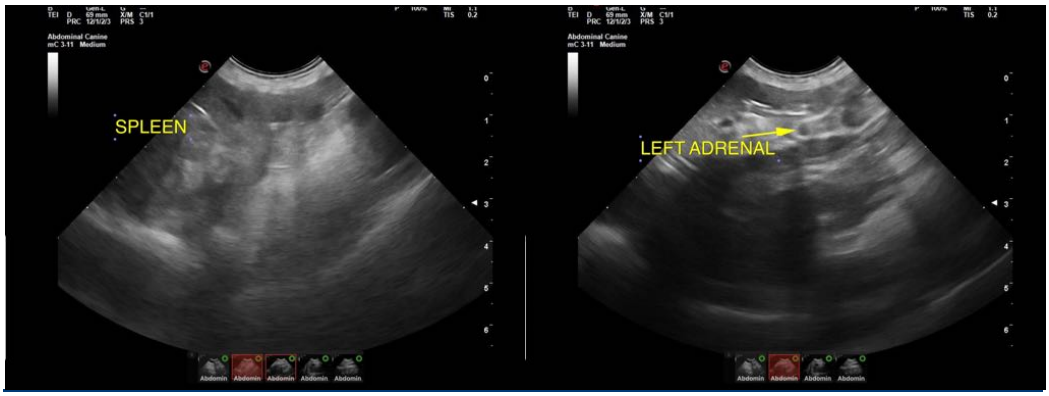

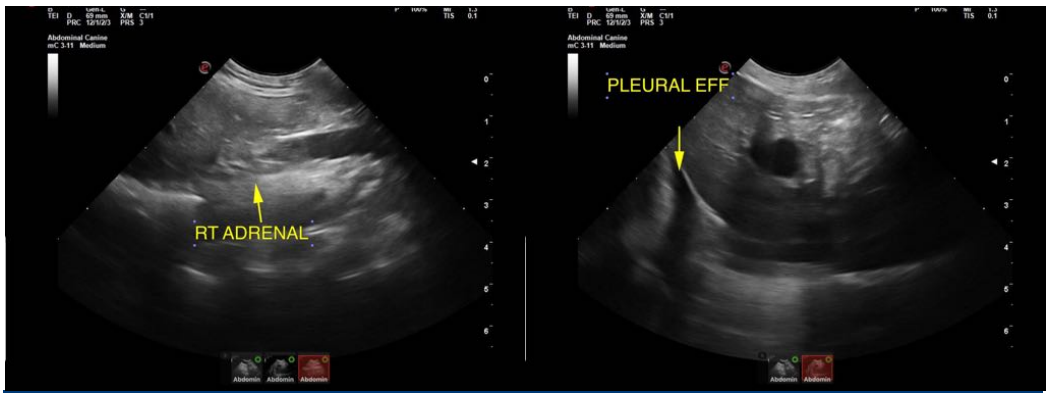

SonoPath
Clinical Sonography & Telecytology

EDUCATIONAL TELECONSULTATION SERVICES™

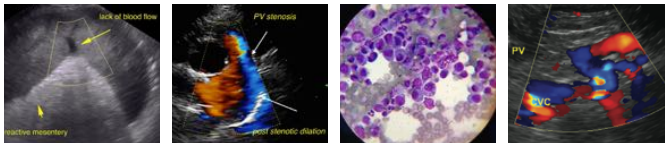

SonoPath.com™
1-800-838-4268 info@sonopath.com

PATIENT

Tebow Graham

SPECIES

Canine

BREED

Cavalier King Charles Spaniel

SEX

Neutered male

AGE

11 years

WEIGHT

15 lbs

INTERPRETED BY

Eric Lindquist, DMV DABVP, Cert. IVUSS

IMAGING PERFORMED BY

Dr. Lanz

HOSPITAL NAME

New Holland VH

REFERRING VET

Dr. Lanz

INVOICE

42531

DATE

11/15/22

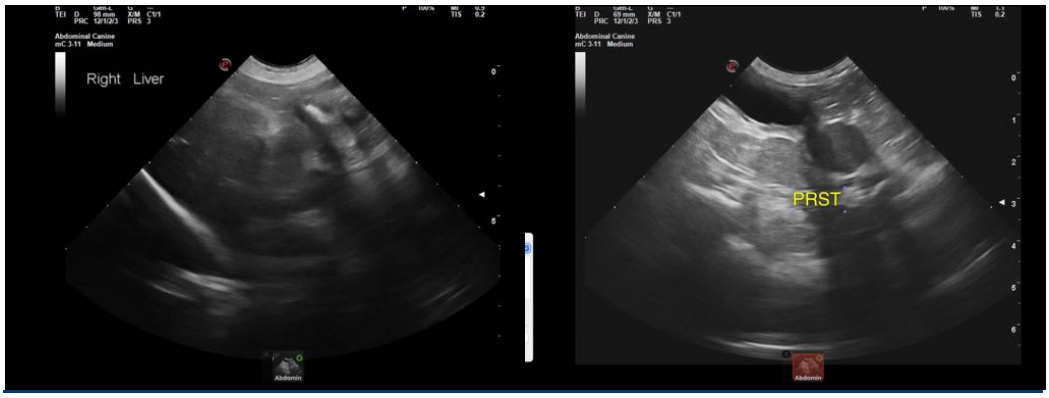

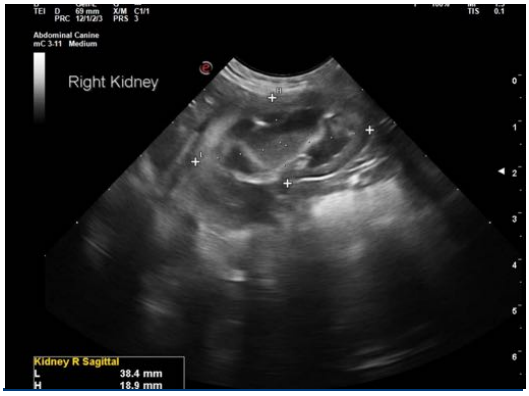

The information and recommendations provided are based on the images presented by the referring veterinarian/sonographer. No evaluation can be communicated regarding pathology that was not visible in the image/video clips provided.

Thank you for this referral. If the clinical or image interpretation does not parallel your findings or if I can be of any further assistance please contact me.

Eric Lindquist, DMV, DABVP, Cert. IVUSS, CEO of SonoPath.com
info@SonoPath.com