



PATIENT

Harry Amoroso

PRESENTING CLINICAL SIGNS

History: -difficult urination

SPECIES

Canine

ULTRASONOGRAPHIC EXAMINATION OF THE ABDOMEN

Urinary System

BREED

Beagle

The **urinary bladder** was over distended at the time of the sonogram. The bladder wall itself was unremarkable. Tissue thickening was noted in the urethral and colonic area. The tissue appeared a bit irregular. The resolution was poor in this region and tissue differential could not be ascertained. Further imaging of the pelvic urethra is indicated.

SEX

Neutered male

The **kidneys** were swollen with minor, subcapsular halo. Otherwise, the kidneys presented mild to moderate degenerative changes. The right kidney measured 6.9 cm with pyelectasia. The left kidney measured 5.5 cm.

AGE

11 years

ULTRASONOGRAPHIC FINDINGS

Tissue thickening in the region of the pelvic urethra and colon.

Pyelectasia of the right kidney.

WEIGHT

37.4 lbs

Over distended bladder.

INTERPRETED BY

Eric Lindquist, DMV
DABVP, Cert. IVUSS

INTERPRETATION OF THE FINDINGS & FURTHER RECOMMENDATIONS

Further imaging is indicated to differentiate the two structures. Power Doppler assessment of this region would also be indicated. Traumatic catheterization could be considered to ensure that prostatic/proximal urethral neoplasia is not an issue.

IMAGING PERFORMED BY

Dr. Barnea

HOSPITAL NAME

Tenafly VC

REFERRING VET

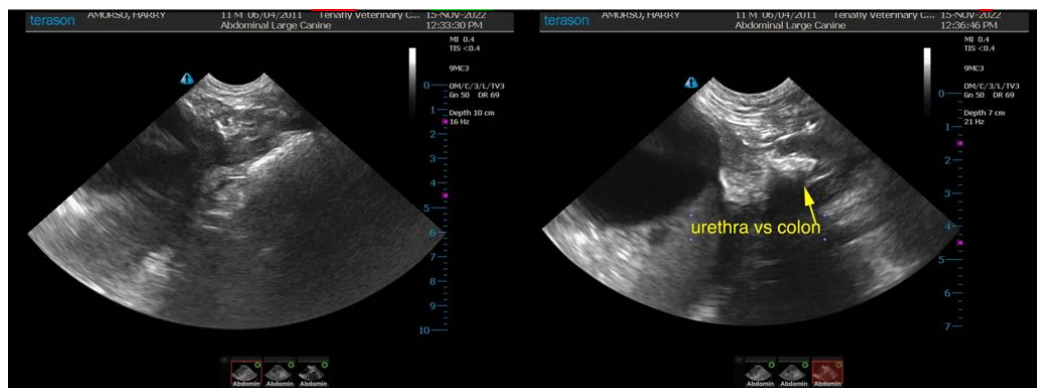
Dr. Barnea

INVOICE

42549

DATE

11/15/22





PATIENT

Harry Amoroso

SPECIES

Canine

BREED

Beagle

SEX

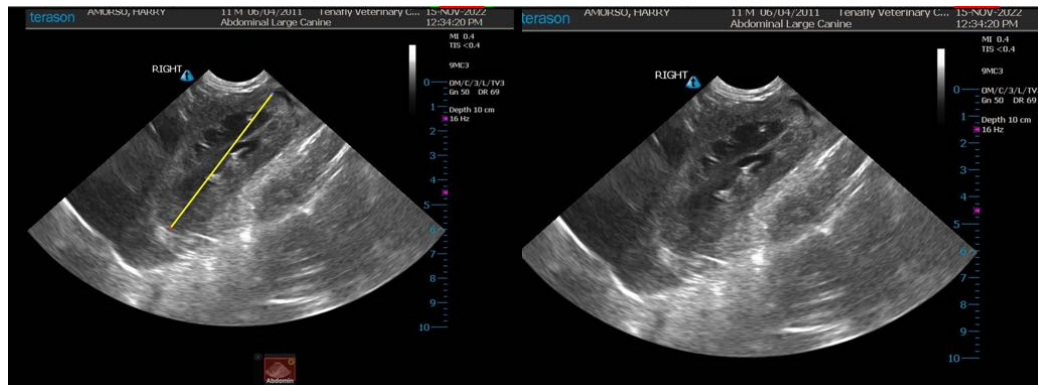
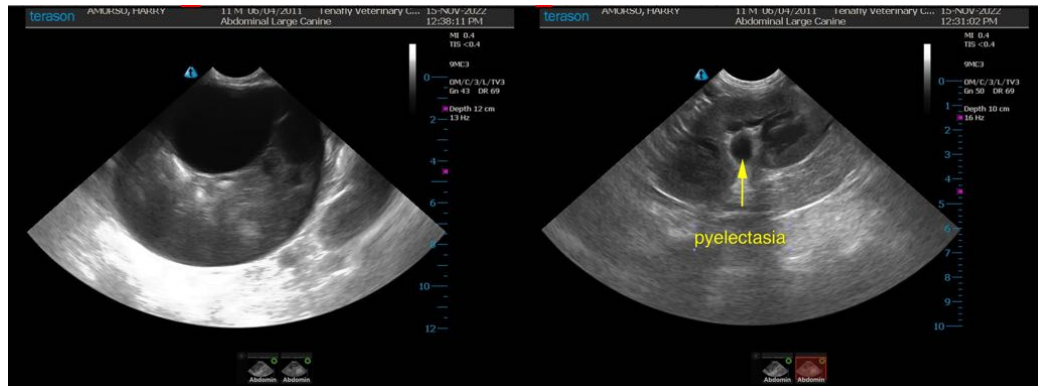
Neutered male

AGE

11 years

WEIGHT

37.4 lbs



INTERPRETED BY

Eric Lindquist, DMV
DABVP, Cert. IVUSS

IMAGING PERFORMED BY

Dr. Barnea

HOSPITAL NAME

Tenaflly VC

REFERRING VET

Dr. Barnea

INVOICE

42549

DATE

11/15/22

The information and recommendations provided are based on the images presented by the referring veterinarian/sonographer. No evaluation can be communicated regarding pathology that was not visible in the image/video clips provided.

Thank you for this referral. If the clinical or image interpretation does not parallel your findings or if I can be of any further assistance please contact me.

Eric Lindquist, DMV, DABVP, Cert. IVUSS, CEO of SonoPath.com
info@SonoPath.com