SonoPath
Clinical Sonography & Telecytology

EDUCATIONAL TELECONSULTATION SERVICES™

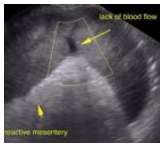

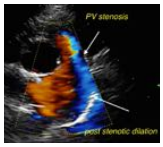

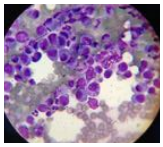
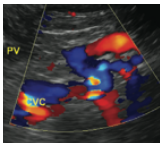

SonoPath.com™
1-800-838-4268 info@sonopath.com

PATIENT
Brandy Markham

SPECIES
Canine

BREED
Golden Retriever

SEX
Spayed female

AGE
11 years

WEIGHT
29.1 kg

INTERPRETED BY
Eric Lindquist, DMV
DABVP, Cert. IVUSS

IMAGING PERFORMED BY
Jessica Morgan RVT

HOSPITAL NAME
Oxford County VH

REFERRING VET
Dr. Halfon

INVOICE
42532

DATE
11/15/22

PRESENTING CLINICAL SIGNS

History: patient presented acutely dull, lethargy, inappetent, no VD, no CS, mm pink, CRT 2 sec, no drooling/salivation; some abdominal pain noted, reluctant to walk, weak hind, but can once up; no neuro deficits, 24 hour duration
Abnormal PE/Chem/CBC/UA Results: Elevated ALT (408) and ALP (237) snap cPL negative, rest of panel normal, no anemia noted, slight monocytosis

ULTRASONOGRAPHIC EXAMINATION OF THE ABDOMEN

Urinary System

The **urinary bladder**, trigone, and pelvic urethra presented normal thicknesses and normal tone. The ureters were not visible which is normal. No uroliths or sediment were visualized and anechoic urine was present. No evidence of inflammatory or neoplastic changes was noted. Ureteral papillae were normal.

The **kidneys** revealed largely normal size and structure, corticomedullary definition and ratio (cortex 1/3 of medulla) were essentially maintained with some age-related loss of curvilinear patterns regarding the capsule and C/M junction. The cortices presented largely uniform texture with some increased echogenicity expected for his age patient. Medullary structure differed distinctly from that of the cortex and no evidence of pelvic dilation was present. The kidneys both measured 6.0 cm.

Adrenal Glands

The regions of the **adrenal glands** were imaged with no evidence of pathology.

Spleen

The **spleen** presented a smooth homogeneous parenchyma hyperechoic to liver and renal cortical parenchyma. The capsule was smooth without noticeable expansion or deviation from within the spleen or adjacent pathology. The splenic vasculature demonstrated normal volume without signs of congestion or thrombosis. No sonographic evidence of acute or chronic inflammatory, neoplastic, or infarctual changes was noted.

Liver

The **liver** images from right and left intercostal as well as subcostal views revealed subjectively normal liver size, contour, and structure. Some age-related parenchymal remodeling was noted but likely not clinically significant at this time. Vascular and biliary tracts were of normal volume and no evidence of congestion was noted. The gallbladder presented some dependent debris with essentially normal contour. The cystic and common bile ducts were normal. No overt evidence of active inflammatory, infiltrative or regenerative pathology was noted but should be paired with current or past LE elevations regarding any clinical significance to this presentation. The hepatic lymph nodes were unremarkable.

SonoPath
Clinical Sonography & Telecytology

EDUCATIONAL TELECONSULTATION SERVICES™

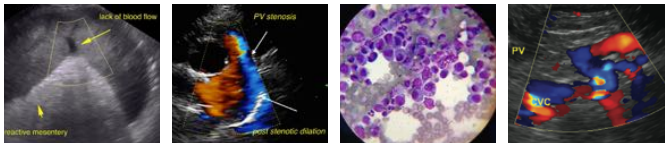

SonoPath.com™
1-800-838-4268 info@sonopath.com

PATIENT

Brandy Markham

SPECIES

Canine

BREED

Golden Retriever

SEX

Spayed female

AGE

11 years

WEIGHT

29.1 kg

INTERPRETED BY

Eric Lindquist, DMV
DABVP, Cert. IVUSS

IMAGING PERFORMED BY

Jessica Morgan RVT

HOSPITAL NAME

Oxford County VH

REFERRING VET

Dr. Halfon

INVOICE

42532

DATE

11/15/22

Gastrointestinal

Examination of the **gastrointestinal tract** revealed a stomach and intestine free of stasis, of normal wall thickness, acceptable curvilinear mural detail, and peristaltic activity. Small and large intestine demonstrated normal luminal chyme and stool consistency respectively. The mesenteric lymph nodes were enlarged and were best represented in video at 3:13:56. The largest node measured 2.0 x 1.0 cm and encompassed the mesenteric artery. There was significant regional inflammation.

Pancreas

The base and limbs of the **pancreas** were observed to be largely isoechoic to surrounding omental fat. Pancreatic duct and capsular contour were acceptably normal and parenchyma respected normal curvilinear patterns. No overt evidence of active inflammatory or neoplastic disease was noted.

ULTRASONOGRAPHIC FINDINGS

Largely geriatric abdomen with mesenteric lymphadenopathy.

INTERPRETATION OF THE FINDINGS & FURTHER RECOMMENDATIONS

Lymphadenitis versus round cell neoplasia are the potentials in this case. Ultrasound-guided FNA of the lymph nodes, cytology and culture is all indicated. The prognosis is guarded. Chest radiographs and full CNS exam is indicated given the patient's history.

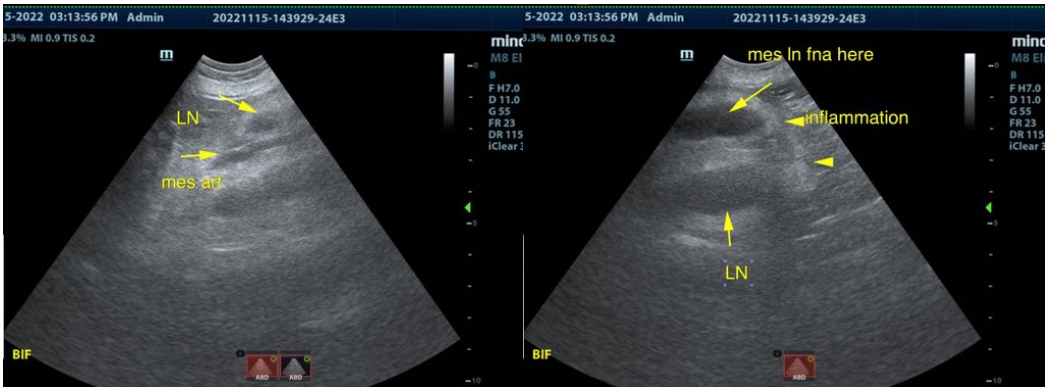

SonoPath

Clinical Sonography & Telecytology

EDUCATIONAL TELECONSULTATION SERVICES™

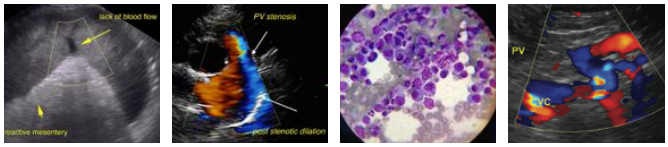

SonoPath.com™
1-800-838-4268 info@sonopath.com

PATIENT

Brandy Markham

SPECIES

Canine

BREED

Golden Retriever

SEX

Spayed female

AGE

11 years

WEIGHT

29.1 kg

INTERPRETED BY

Eric Lindquist, DMV
DABVP, Cert. IVUSS

IMAGING PERFORMED BY

Jessica Morgan RVT

HOSPITAL NAME

Oxford County VH

REFERRING VET

Dr. Halfon

INVOICE

42532

DATE

11/15/22

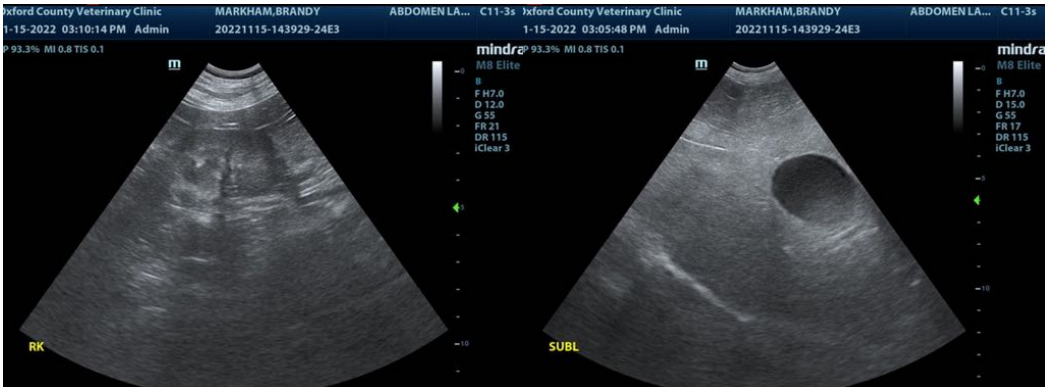

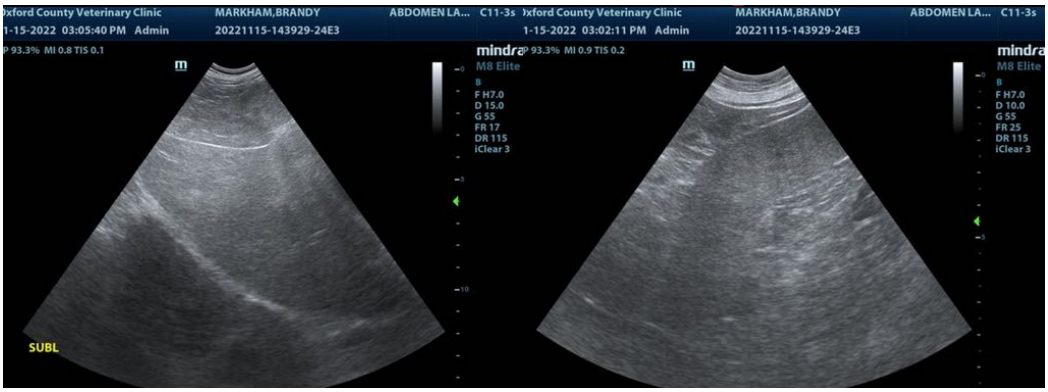

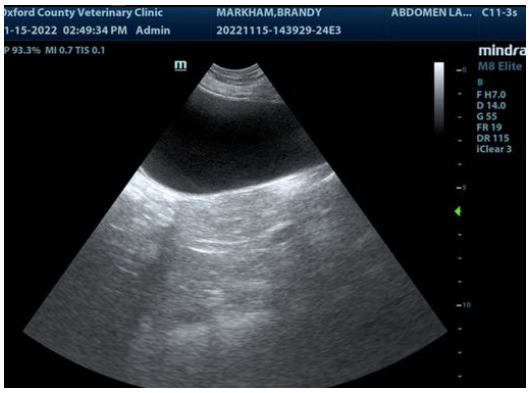

The information and recommendations provided are based on the images presented by the referring veterinarian/sonographer. No evaluation can be communicated regarding pathology that was not visible in the image/video clips provided.

Thank you for this referral. If the clinical or image interpretation does not parallel your findings or if I can be of any further assistance please contact me.

Eric Lindquist, DMV, DABVP, Cert. IVUSS, CEO of SonoPath.com
info@SonoPath.com