



**PATIENT**

Zoey Ganju

**SPECIES**

Canine

**BREED**

Mixed Breed Canine

**SEX**

Spayed Female

**AGE**

7 Years

**WEIGHT**

56 lbs

**INTERPRETED BY**

Eric Lindquist, DMV  
DABVP, Cert. IVUSS

**IMAGING PERFORMED BY**

Kelly Vazquez

**HOSPITAL NAME**

Midland Park VH

**REFERRING VET**

Dr. John Shokoff

**INVOICE**

12543

**DATE**

11/15/21

**PRESENTING CLINICAL SIGNS**

History: Elevated ALT/ALP on blood work, elevated platelets. Current meds: galliprant 50 mgs SID.  
Abnormal PE/Chem/CBC/UA Results: ALT 122, ALP 302. Platelets 490.

**ULTRASONOGRAPHIC EXAMINATION OF THE ABDOMEN**

**Urinary System**

The **urinary bladder**, trigone, and pelvic urethra presented normal thicknesses and normal tone. The ureters were not visible which is normal. No uroliths or sediment were visualized and anechoic urine was present. No evidence of inflammatory or neoplastic changes were noted. Ureteral papillae were normal. The pelvic urethra was imaged 2.0 cm beyond the cystourethral junction.

The **kidneys** revealed normal size and structure, corticomedullary definition and ratio for this age. The cortices presented largely uniform texture with normal echogenic relationship to liver and spleen. Medullary structure differed distinctly from the cortex and no evidence of pelvic dilation was present. The capsules were acceptably uniform without significant irregularities. The left kidney measured 5.67 cm. The right kidney measured 5.67 cm.

**Adrenal Glands**

Both **adrenal glands** were visualized and recognized as having normal shape, size, position and echogenicity for this breed. The phrenic vasculature, glandular echogenicity and detail were unremarkable. Capsule, cortex, and medullary definition were normal for this age patient. The right adrenal gland measured 1.74 cm x 0.46 cm at the caudal pole and 0.61 cm at the cranial pole. The left adrenal gland measured 1.74 cm x 0.47 cm at the caudal pole and 0.39 cm at the cranial pole.

**Spleen**

The **spleen** presented a smooth homogeneous parenchyma hyperechoic to liver and renal cortical parenchyma. The capsule was smooth without noticeable expansion or deviation from within the spleen or adjacent pathology. The splenic vasculature demonstrated normal volume without signs of congestion or thrombosis. No sonographic evidence of acute or chronic inflammatory, neoplastic, or infarctual changes were noted.

**Liver**

The **liver** was diffusely hyperechoic to falciform fat with generalized enlargement. The gallbladder and common bile duct were unremarkable.

**Gastrointestinal**

Examination of the **gastrointestinal tract** revealed a stomach and intestine free of stasis, of normal wall thickness, acceptable curvilinear mural detail, and peristaltic activity. Small and large intestine demonstrated normal luminal chyme and stool consistency respectively. No obstructive or overt infiltrative disease was noted. No associated abnormal lymphatic activity was noted.

**Pancreas**

The base and limbs of the **pancreas** were observed to be largely isoechoic to surrounding omental fat. Pancreatic duct and capsular contour were acceptably normal and parenchyma respected normal curvilinear patterns. No overt evidence of active inflammatory or neoplastic disease was noted.



**PATIENT**

Zoey Ganju

**SPECIES**

Canine

**BREED**

Mixed Breed Canine

**SEX**

Spayed Female

**AGE**

7 Years

**WEIGHT**

56 lbs

**INTERPRETED BY**

Eric Lindquist, DMV  
DABVP, Cert. IVUSS

**IMAGING PERFORMED BY**

Kelly Vazquez

**HOSPITAL NAME**

Midland Park VH

**REFERRING VET**

Dr. John Shokoff

**INVOICE**

12543

**DATE**

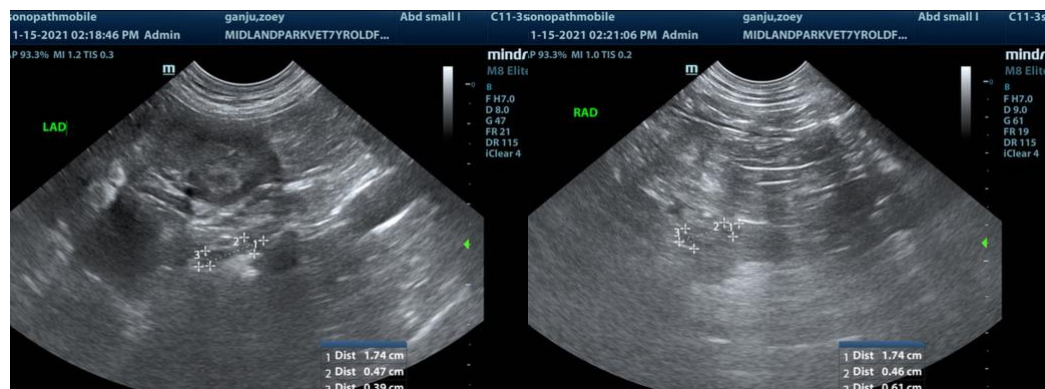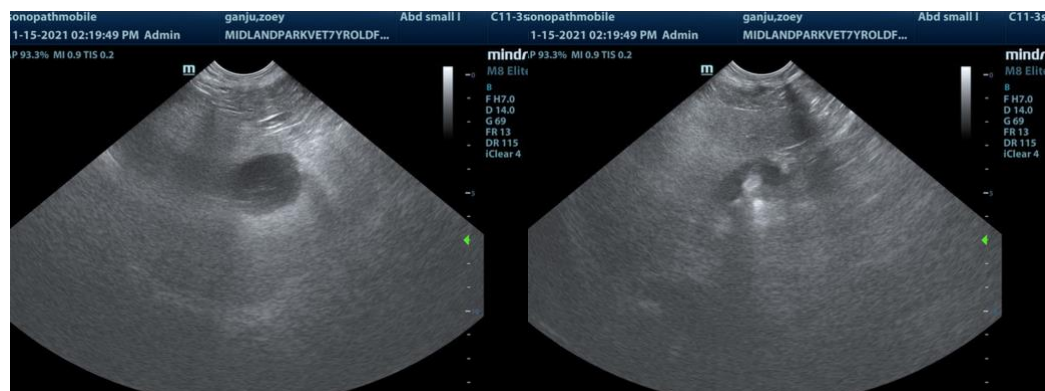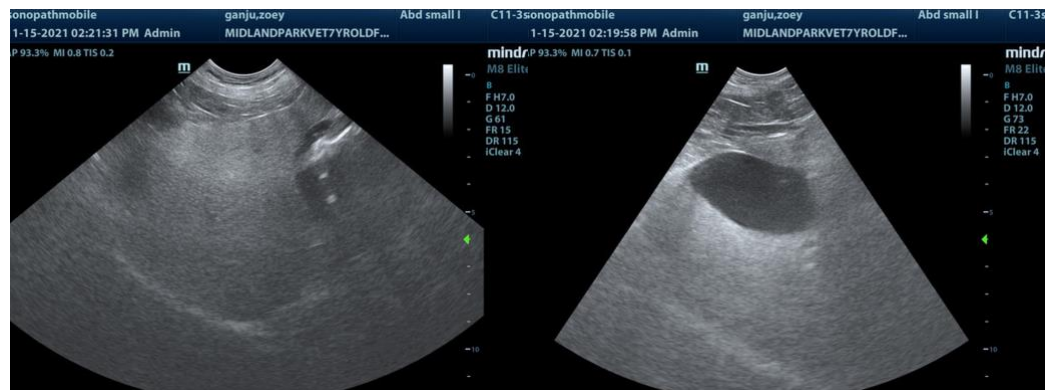
11/15/21

**ULTRASONOGRAPHIC FINDINGS**

- Vacuolar hepatopathy liver pattern, underlying endocrinopathy or breed predisposition likely
- Unremarkable abdomen otherwise

**INTERPRETATION OF THE FINDINGS & FURTHER RECOMMENDATIONS**

FNA could be considered for further definition. No evidence of suspicion of neoplasia.





**PATIENT**

Zoey Ganju

**SPECIES**

Canine

**BREED**

Mixed Breed Canine

**SEX**

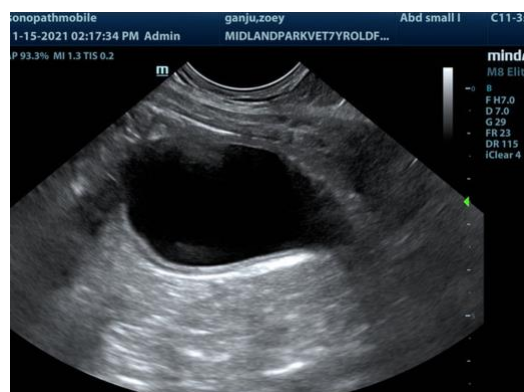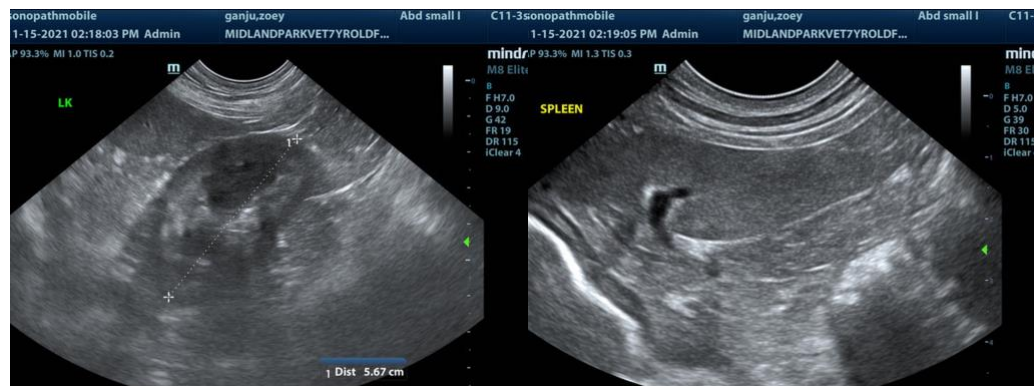Spayed Female

**AGE**

7 Years

**WEIGHT**

56 lbs



**INTERPRETED BY**

Eric Lindquist, DMV  
DABVP, Cert. IVUSS

**IMAGING PERFORMED BY**

Kelly Vazquez

**HOSPITAL NAME**

Midland Park VH

**REFERRING VET**

Dr. John Shokoff

**INVOICE**

12543

**DATE**

11/15/21

The information and recommendations provided are based on the images presented by the referring veterinarian. No evaluation can be communicated regarding pathology that was not visible in the image/video clips provided.

Thank you for this referral. If the clinical or image interpretation does not parallel your findings or if I can be of any further assistance please contact me.

**Eric Lindquist**, DMV, DABVP, Cert. IVUSS, CEO of SonoPath.com  
info@SonoPath.com