



PATIENT

Mr. Buddy Garrett

SPECIES

Feline

BREED

DSH

SEX

Neutered Male

AGE

8 Years

WEIGHT

14.75 Lbs

INTERPRETED BY

Eric Lindquist, DMV
DABVP, Cert. IVUSS

IMAGING PERFORMED BY

Jenna Walsh

HOSPITAL NAME

West Eugene AH

REFERRING VET

Dr. Sundholm

INVOICE

12555

DATE

11/15/21

PRESENTING CLINICAL SIGNS

History: Mr. Buddy has a history of grade 3/6 heart murmur and mild/moderate HCM diagnosed via echo in 2017 (done through Animal Sounds). On exam 11/8/21, Mr. Buddy did not have a heart murmur. He has been doing well clinically.

Abnormal PE/Chem/CBC/UA Results:

ULTRASONOGRAPHIC EXAMINATION OF THE HEART

FELINE CARDIAC PARAMETERS	BODY WEIGHT (kg)	HR (BPM)	IVSd (cm)	LVIDd (cm)	LVWd (cm)	FS (%)	EF (%)
NORMAL PARAMETER	-----	150-240	0.3-0.6	1.0-2.1	0.25-0.6	35-67	80-100
PATIENT	--	211	0.45	1.77	0.47	55	88
FELINE CARDIAC PARAMETERS	LA/AO (Boon)	LA/AO HEART BASE (Sisson)	LA 2D 4-chamber long axis AS to FW (Sisson) (cm)	LVOT VEL. (m/s)	RVOT VEL. (m/s)	IVRT (m/)	
NORMAL PARAMETER	<1.5	0.88-1.79	0.7-1.7	<1.6	<1.3	40-60	
PATIENT	1.35	1.66	--	1.01	.85	NM	
Adapted from June Boon, Veterinary Echocardiography, 1998 Sisson D et al. JVIM 1991; 5: 232, Jacobs et al. Am J Vet Res 1985; 46:1705							

Cardiac Presentation

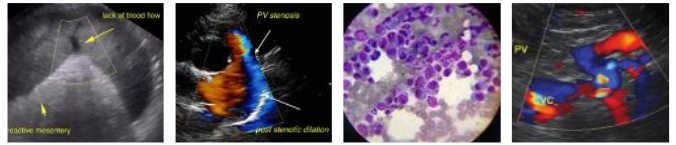
The heart in this patient presented minor sectorial hypertrophy of the left ventricular septum and papillary muscle with myocardial remodeling. However, function and contractility as well as internal volumes are acceptable. No significant insufficiency or functional cardiac disease noted in this patient.

ULTRASONOGRAPHIC FINDINGS

- Minor sectorial hypertrophy and myocardial remodeling, benign stable form of hypertrophic cardiomyopathy

INTERPRETATION OF THE FINDINGS & FURTHER RECOMMENDATIONS

No therapy recommended at this time. Recheck echo in 1 year as long as the patient is stable. Blood pressures and thyroid assessment warranted (if not already performed).



PATIENT

Mr. Buddy Garrett

SPECIES

Feline

BREED

DSH

SEX

Neutered Male

AGE

8 Years

WEIGHT

14.75 Lbs

INTERPRETED BY

Eric Lindquist, DMV
DABVP, Cert. IVUSS

**IMAGING
PERFORMED BY**

Jenna Walsh

HOSPITAL NAME

West Eugene AH

REFERRING VET

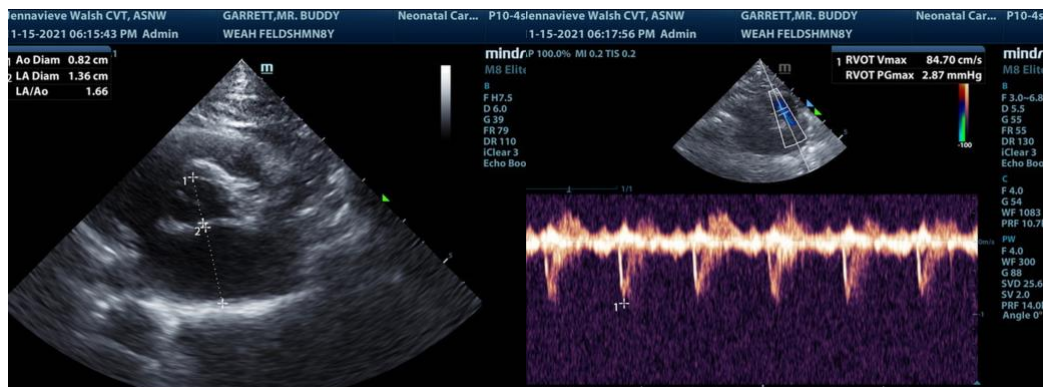
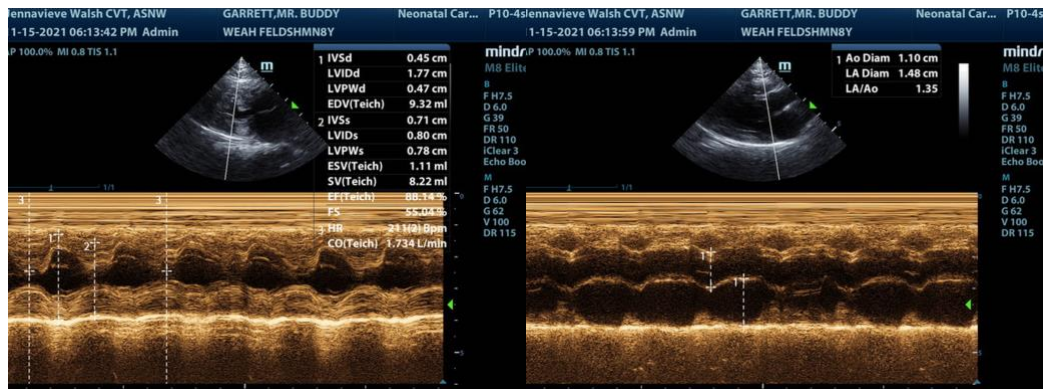
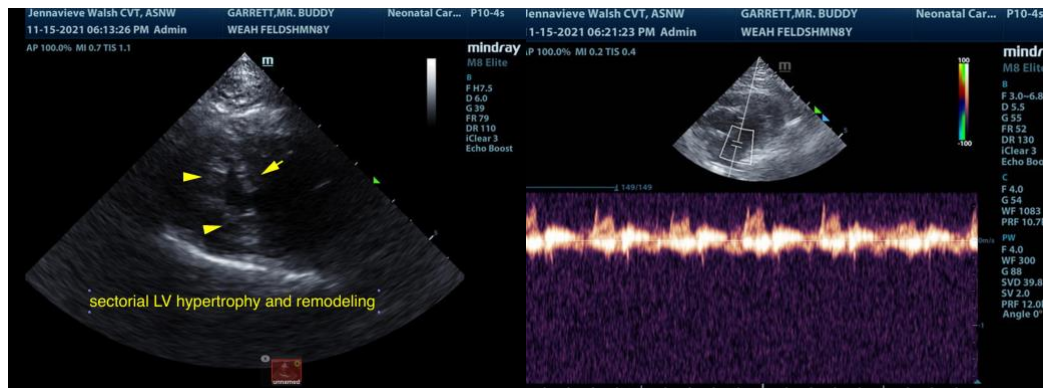
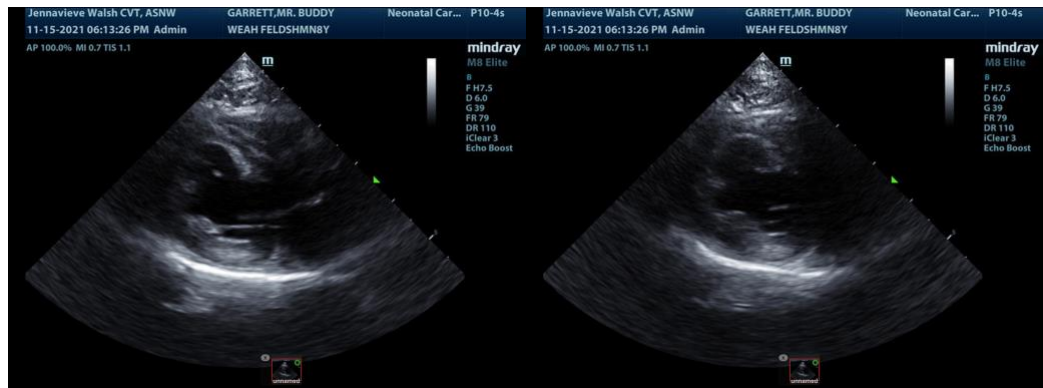
Dr. Sundholm

INVOICE

12555

DATE

11/15/21





PATIENT

Mr. Buddy Garrett

SPECIES

Feline

BREED

DSH

SEX

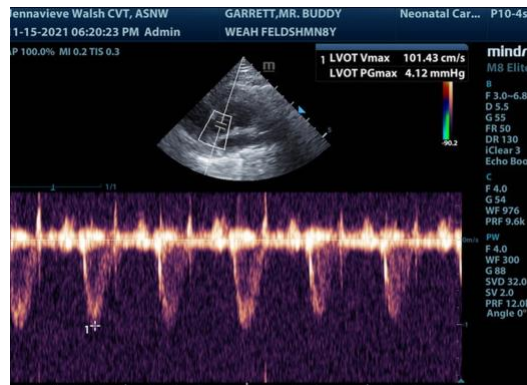
Neutered Male

AGE

8 Years

WEIGHT

14.75 Lbs



The information and recommendations provided are based on the images presented by the referring veterinarian. No evaluation can be communicated regarding pathology that was not visible in the image/video clips provided.

Thank you for this referral. If the clinical or image interpretation does not parallel your findings or if I can be of any further assistance please contact me.

Eric Lindquist, DMV, DABVP, Cert. IVUSS, CEO of SonoPath.com

Eric.Lindquist@SonoPath.com

INTERPRETED BY

Eric Lindquist, DMV
DABVP, Cert. IVUSS

IMAGING PERFORMED BY

Jenna Walsh

HOSPITAL NAME

West Eugene AH

REFERRING VET

Dr. Sundholm

INVOICE

12555

DATE

11/15/21