



PATIENT

Jake Maloney

SPECIES

Canine

BREED

Hound x

SEX

Neutered Male

AGE

6 Years

WEIGHT

41.8 lbs

INTERPRETED BY

Eric Lindquist, DMV,
DABVP (CFM), Cert.
IVUSS

IMAGING PERFORMED BY

Dr. Striegel

HOSPITAL NAME

Veterinary Center of
Hardyston

REFERRING VET

Dr. Striegel

INVOICE

71801

DATE

11/14/25

PRESENTING CLINICAL SIGNS

Vomiting, Diarrhea, Lethargy, Anorexia on and off since October. Weight loss
Abnormal PE/Chem/CBC/UA Results: 11/10- Alb 2.6 Calcium 8.6 Monocytes 1188

ULTRASONOGRAPHIC EXAMINATION OF THE ABDOMEN

Urinary System

The **urinary bladder**, trigone, and pelvic urethra presented normal thicknesses and normal tone. The ureters were not visible which is normal. No uroliths or sediment were visualized and anechoic urine was present. No evidence of inflammatory or neoplastic changes were noted. Ureteral papillae were normal.

The **kidneys** revealed normal size and structure, corticomedullary definition and ratio for this age. The cortices presented largely uniform texture with normal echogenic relationship to liver and spleen. Medullary structure differed distinctly from the cortex and no evidence of pelvic dilation was present. The capsules were acceptably uniform without significant irregularities. The left kidney measured 5.4 cm. The right kidney measured 5.0 cm.

Adrenal Glands

Both **adrenal glands** were visualized and recognized as having normal shape, size, position and echogenicity for this breed. The phrenic vasculature, glandular echogenicity and detail were unremarkable. Capsule, cortex, and medullary definition were normal for this age patient. The left adrenal gland measured 0.60 cm.

Spleen

The **spleen** presented a smooth homogeneous parenchyma hyperechoic to liver and renal cortical parenchyma. The capsule was smooth without noticeable expansion or deviation from within the spleen or adjacent pathology. The splenic vasculature demonstrated normal volume without signs of congestion or thrombosis. No sonographic evidence of acute or chronic inflammatory, neoplastic, or infarctual changes were noted.

Liver

The **liver** images submitted revealed subjectively normal liver size, contour, and structure. Parenchymal echogenicity was naturally coarse and hypoechoic to the spleen. Vascular and biliary tracts were of normal volume with no evidence of congestion. The gallbladder presented acceptably thin walls with primarily anechoic content. The cystic and common bile ducts were normal. No pathological hepatic lymphadenopathy was evident. No overt structural evidence of inflammatory, infiltrative or regenerative pathology was evident.

Gastrointestinal

The **stomach** itself was unremarkable. The distal small intestine was dilated with stasis followed by empty small intestine, creating an obstructive pattern. Hyperperistalsis noted with a 3.0+ cm shadowing foreign body. Variable intestinal thickening noted as well. Regional lymph nodes were slightly enlarged, reactive, measuring up to 2.0 cm.



PATIENT

Jake Maloney

SPECIES

Canine

BREED

Hound x

SEX

Neutered Male

AGE

6 Years

WEIGHT

41.8 lbs

INTERPRETED BY

Eric Lindquist, DMV,
DABVP (CFM), Cert.
IVUSS

IMAGING PERFORMED BY

Dr. Striegel

HOSPITAL NAME

Veterinary Center of
Hardyston

REFERRING VET

Dr. Striegel

INVOICE

71801

DATE

11/14/25

Pancreas

The base and limbs of the **pancreas** were observed to be largely isoechoic to surrounding omental fat. Pancreatic duct and capsular contour were acceptably normal and parenchyma respected normal curvilinear patterns. No overt evidence of active inflammatory or neoplastic disease was noted.

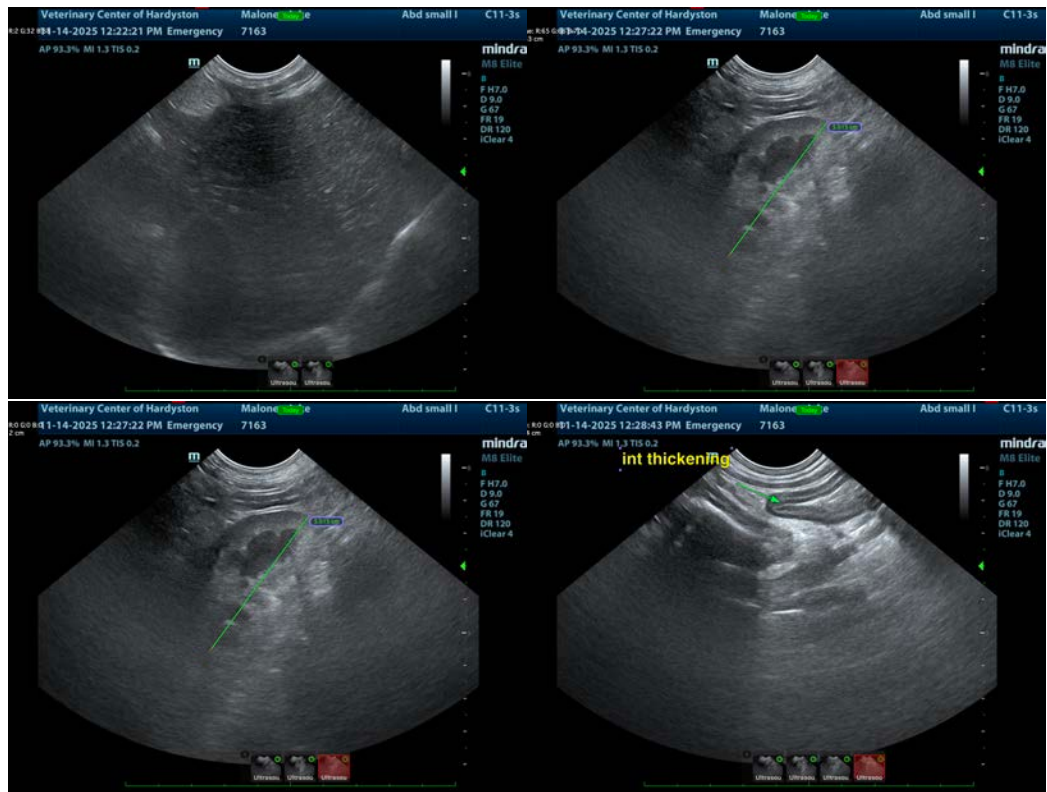
ULTRASONOGRAPHIC FINDINGS

- Obstructive intestinal pattern with suspected foreign body and chronic intestinal disease.

INTERPRETATION OF THE FINDINGS & FURTHER RECOMMENDATIONS

Enterotomy and GI biopsies warranted.

According to SonoPath research presented at ECVIM 2016 (Stockholm, Sweden), Advances in Small Animal Medicine and Surgery (May 2017), and EVDI 2017 (Verona, Italy), concurrent underlying chronic inflammatory neoplastic intestinal disease can often reside in PICA patients. Therefore, surgical biopsies are essential in this case regardless of the exploratory findings.





PATIENT

Jake Maloney

SPECIES

Canine

BREED

Hound x

SEX

Neutered Male

AGE

6 Years

WEIGHT

41.8 lbs

INTERPRETED BY

Eric Lindquist, DMV,
DABVP (CFM), Cert.
IVUSS

**IMAGING
PERFORMED BY**

Dr. Striegel

HOSPITAL NAME

Veterinary Center of
Hardyston

REFERRING VET

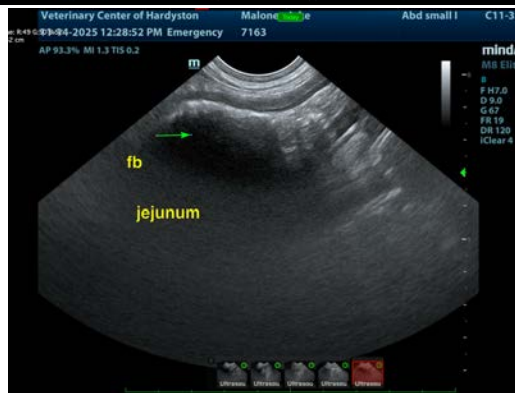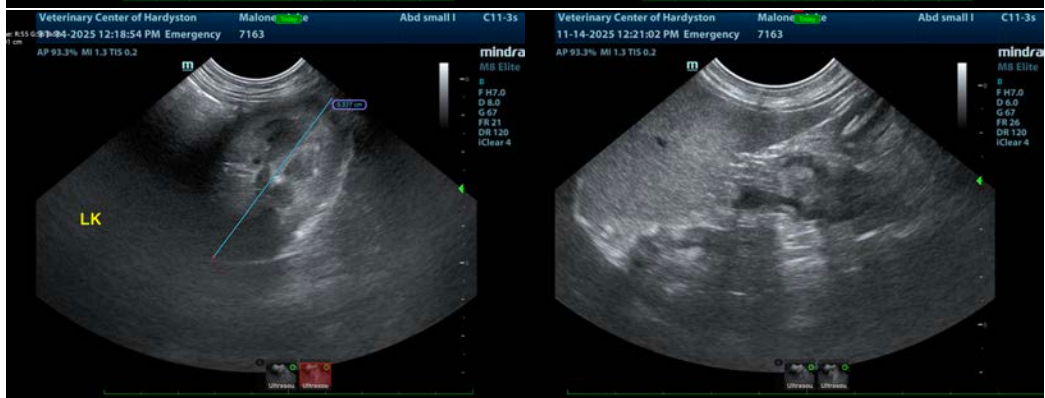
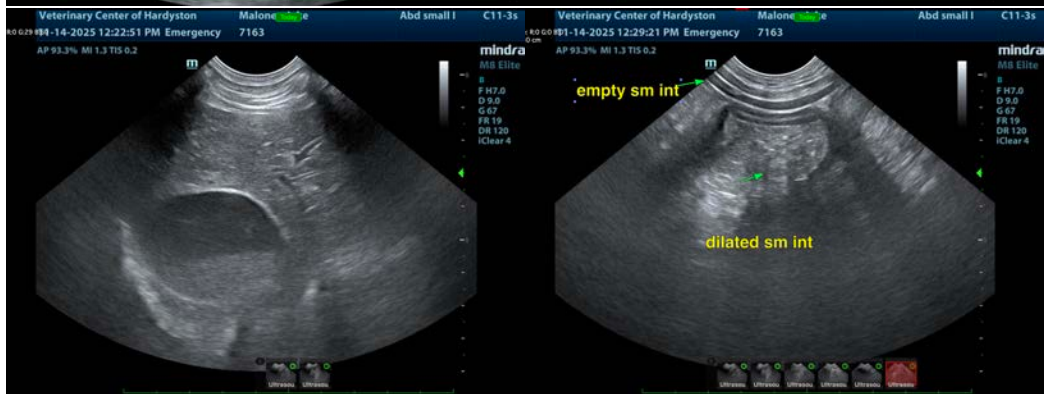
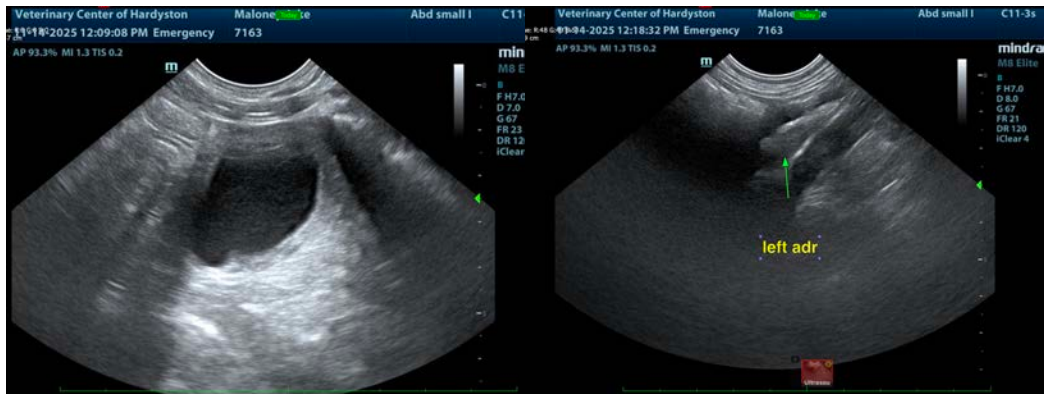Dr. Striegel

INVOICE

71801

DATE

11/14/25





PATIENT

Jake Maloney

The information and recommendations provided are based on the images presented by the referring veterinarian/sonographer. No evaluation can be communicated regarding pathology that was not visible in the image/video clips provided.

SPECIES

Canine

Thank you for this referral. If the clinical or image interpretation does not parallel your findings or if I can be of any further assistance please contact me.

BREED

Hound x

Eric Lindquist, DMV, DABVP(CFM), Cert. IVUSS,
CEO, Owner, Founder -- SonoPath.com
info@SonoPath.com

SEX

Neutered Male

AGE

6 Years

WEIGHT

41.8 lbs

INTERPRETED BY

Eric Lindquist, DMV,
DABVP (CFM), Cert.
IVUSS

IMAGING PERFORMED BY

Dr. Striegel

HOSPITAL NAME

Veterinary Center of
Hardyston

REFERRING VET

Dr. Striegel

INVOICE

71801

DATE

11/14/25