



PATIENT

Holly Ledford

SPECIES

Canine

BREED

Chihuahua Mix

SEX

Spayed female

AGE

14 years

WEIGHT

13.4 lbs

INTERPRETED BY

Eric Lindquist, DMV
DABVP, Cert. IVUSS

IMAGING PERFORMED BY

Dr. Whitesell

HOSPITAL NAME

Dickson AC

REFERRING VET

Dr. Whitesell

INVOICE

68683

DATE

11/13/25

PRESENTING CLINICAL SIGNS

History: PU/PD

ULTRASONOGRAPHIC EXAMINATION OF THE ABDOMEN

Urinary System

The **bladder** in this patient was mildly thickened with slight echogenic mural changes. No calculi or masses were noted. Slight micropolypoid changes were noted. This is a frequent finding in older animals and may be linked to a history of chronic urinary tract infection or active urinary tract infection. Urinalysis would be recommended with culture if any evidence of inflammatory sediment is present. The region of the trigone and visible pelvic urethra were normal.

The **kidneys** revealed largely normal size and structure, corticomedullary definition and ratio (cortex 1/3 of medulla) were essentially maintained with some age-related loss of curvilinear patterns regarding the capsule and C/M junction. The cortices presented largely uniform texture with some increased echogenicity expected for this age patient. Medullary structure differed distinctly from that of the cortex. Slight cortical cysts were noted in the left kidney. The left kidney measured 4.13 cm with slight pyelectasia. The right kidney measured 4.27 cm with slight pyelectasia and microcystic cortical changes

Adrenal Glands

Both **adrenal glands** were visualized and recognized as having normal shape, size, position and echogenicity for this breed. The phrenic vasculature, glandular echogenicity and detail were unremarkable. Capsule, cortex, and medullary definition were normal for this age patient. The left adrenal gland measured 0.65 cm at the caudal pole and 0.52 cm at the cranial pole.

Spleen

The **spleen** was normal size and relatively normal contour with multifocal hyperechoic areas of mineralization. This is a benign change; however, can be related to Cushing's disease or other endocrinopathies.

Liver

The **liver** was mildly enlarged with swollen contour. Diffuse hyperechogenicity and mild coarse architecture. The gallbladder was mildly over distended with striating bile. This is consistent with emerging mucocele.

Gastrointestinal



PATIENT

Holly Ledford

SPECIES

Canine

BREED

Chihuahua Mix

SEX

Spayed female

AGE

14 years

WEIGHT

13.4 lbs

INTERPRETED BY

Eric Lindquist, DMV
DABVP, Cert. IVUSS

IMAGING PERFORMED BY

Dr. Whitesell

HOSPITAL NAME

Dickson AC

REFERRING VET

Dr. Whitesell

INVOICE

68683

DATE

11/13/25

Examination of the **gastrointestinal tract** revealed a stomach and intestine free of stasis, of normal wall thickness, acceptable curvilinear mural detail, and peristaltic activity. Small and large intestine demonstrated normal luminal chyme and stool consistency respectively. No obstructive or overt infiltrative disease was noted. No associated abnormal lymphatic activity was noted.

Pancreas

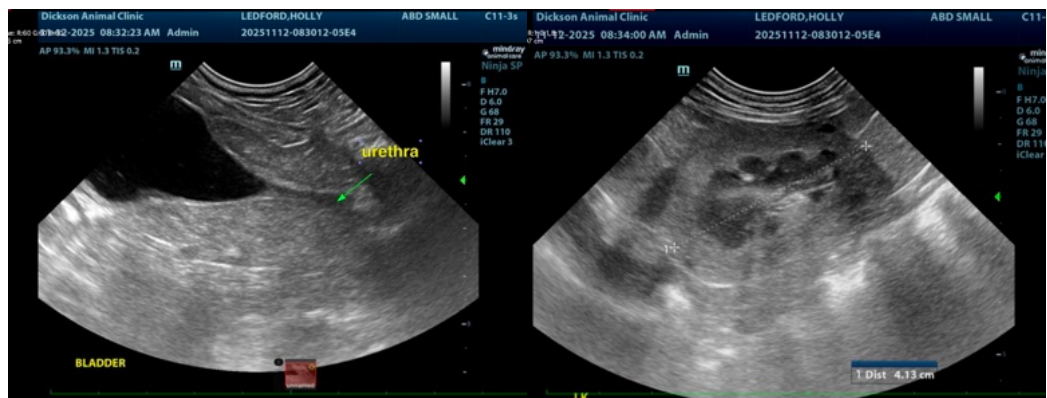
The base and limbs of the **pancreas** were observed to be largely isoechoic to surrounding omental fat. Pancreatic duct and capsular contour were acceptably normal and parenchyma respected normal curvilinear patterns. No overt evidence of active inflammatory or neoplastic disease was noted.

ULTRASONOGRAPHIC FINDINGS

- Moderate chronic degenerative renal changes with slight pyelectasia, potential embedded UTI.
- Minor bladder thickening.
- Metabolic hepatopathy with emerging mucocele.
- Structurally normal adrenal glands.

INTERPRETATION OF THE FINDINGS & FURTHER RECOMMENDATIONS

Ursodiol therapy is recommended over a 6-8 week period and/or gallbladder motility study would be ideal. Urine culture and sensitivity is warranted if any inflammatory sediment is present.





PATIENT

Holly Ledford

SPECIES

Canine

BREED

Chihuahua Mix

SEX

Spayed female

AGE

14 years

WEIGHT

13.4 lbs

INTERPRETED BY

Eric Lindquist, DMV
DABVP, Cert. IVUSS

IMAGING PERFORMED BY

Dr. Whitesell

HOSPITAL NAME

Dickson AC

REFERRING VET

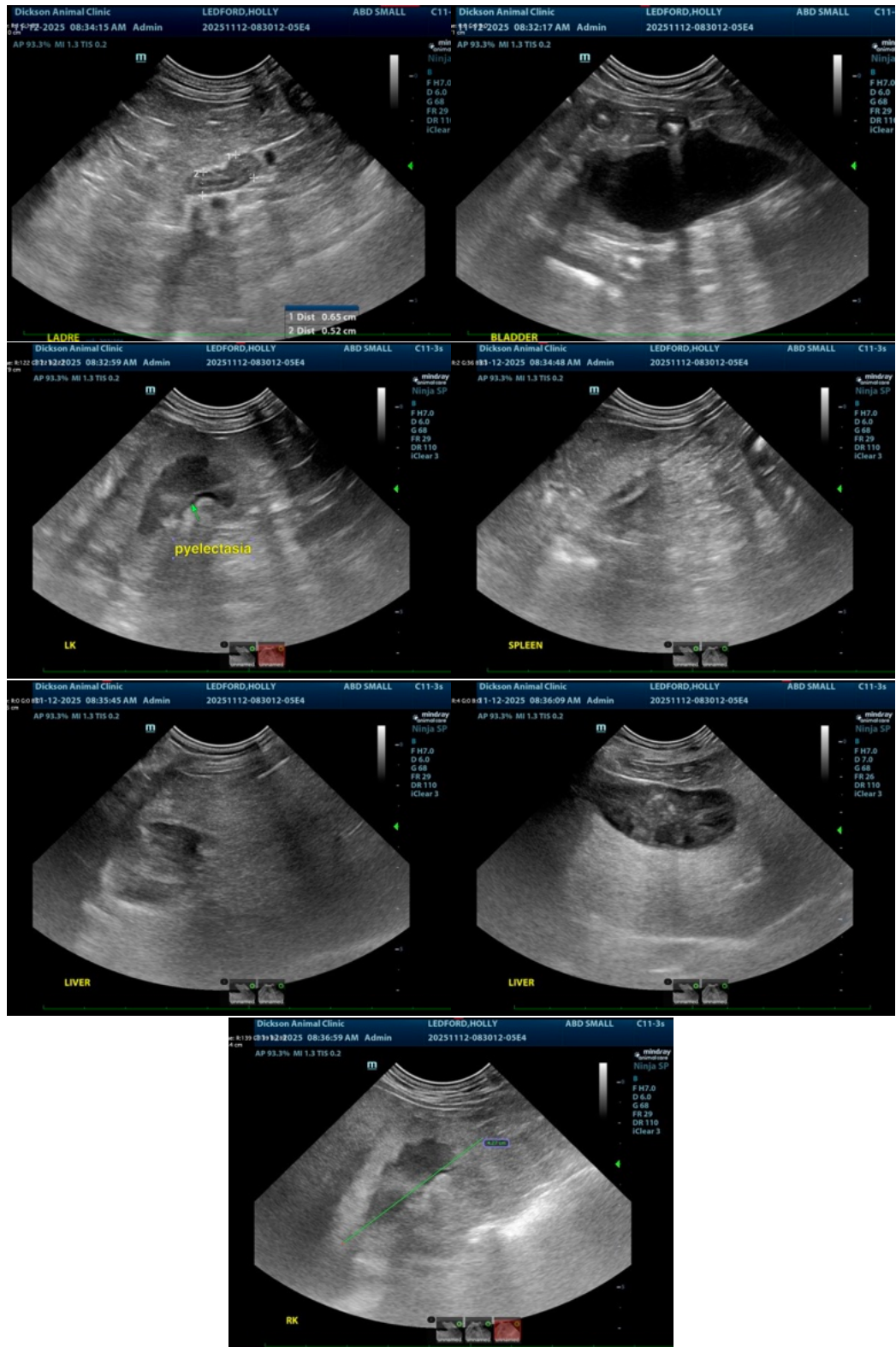
Dr. Whitesell

INVOICE

68683

DATE

11/13/25





PATIENT

Holly Ledford

SPECIES

Canine

BREED

Chihuahua Mix

SEX

Spayed female

AGE

14 years

WEIGHT

13.4 lbs

INTERPRETED BY

Eric Lindquist, DMV
DABVP, Cert. IVUSS

IMAGING PERFORMED BY

Dr. Whitesell

HOSPITAL NAME

Dickson AC

REFERRING VET

Dr. Whitesell

INVOICE

68683

DATE

11/13/25

The information and recommendations provided are based on the images presented by the referring veterinarian/sonographer. No evaluation can be communicated regarding pathology that was not visible in the image/video clips provided.

Thank you for this referral. If the clinical or image interpretation does not parallel your findings or if I can be of any further assistance please contact me.

Eric Lindquist, DMV, DABVP (CFM), Cert. IVUSS, CEO of SonoPath.com

info@SonoPath.com