



## PATIENT

Dylan Simbeck

## SPECIES

Canine

## BREED

Flat Coated Retriever

## SEX

Neutered male

## AGE

6 years

## WEIGHT

75 lbs

## INTERPRETED BY

Eric Lindquist, DMV  
DABVP, Cert. IVUSS

## IMAGING PERFORMED BY

Dr. Lincoski

## HOSPITAL NAME

University Drive VH

## REFERRING VET

Dr. Lincoski

## INVOICE

68674

## DATE

11/13/25

## PRESENTING CLINICAL SIGNS

History: Patient has been losing weight, NuQ cancer test was positive for nucleosomes. CBC/CS/T4 all normal. Normal thoracic radiographs, and no evidence of melanoma (even nailbeds, oral cavity) or anal gland masses.

Abnormal PE/Chem/CBC/UA Results: Thin, otherwise wnl.

## ULTRASONOGRAPHIC EXAMINATION OF THE ABDOMEN

### Urinary System

The **urinary bladder** presented a relatively uniform thickening of the cranioventral and craniodorsal mucosae with micropolypoid mucosal changes without involvement of the submucosae. The urine presented some echogenicity consistent with suspended debris. No evidence of urethral pathology was present. This presentation is most consistent with chronic cystitis. Technically transitional cell carcinoma cannot be ruled out without histopathological review but is not overtly suspected based on this pattern. Cystocentesis and urine culture +/- pathological review of urine cytology would be warranted. No overt calculi were present at this time.

The **kidneys** revealed largely normal size and structure, corticomedullary definition and ratio (cortex 1/3 of medulla) were essentially maintained with some age-related loss of curvilinear patterns regarding the capsule and C/M junction. The cortices presented largely uniform texture with some increased echogenicity expected for this age patient. Medullary structure differed distinctly from that of the cortex and no evidence of pelvic dilation was present. The right kidney measured 6.5 cm. The left kidney measured 6.5 cm.

### Adrenal Glands

Both **adrenal glands** were visualized and recognized as having normal shape, size, position and echogenicity for this breed. The phrenic vasculature, glandular echogenicity and detail were unremarkable. Capsule, cortex, and medullary definition were normal for this age patient. The right adrenal gland measured 0.5 cm at the caudal pole and 1.0 cm at the cranial pole. The left adrenal gland measured 0.5 cm.

### Spleen

The **spleen** presented a smooth homogeneous parenchyma hyperechoic to liver and renal cortical parenchyma. The capsule was smooth without noticeable expansion or deviation from within the spleen or adjacent pathology. The splenic vasculature demonstrated normal volume without signs of congestion or thrombosis. No sonographic evidence of acute or chronic inflammatory, neoplastic, or infarctual changes was noted.



## PATIENT

Dylan Simbeck

## SPECIES

Canine

## BREED

Flat Coated Retriever

## SEX

Neutered male

## AGE

6 years

## WEIGHT

75 lbs

## INTERPRETED BY

Eric Lindquist, DMV  
DABVP, Cert. IVUSS

## IMAGING PERFORMED BY

Dr. Lincoski

## HOSPITAL NAME

University Drive VH

## REFERRING VET

Dr. Lincoski

## INVOICE

68674

## DATE

11/13/25

## Liver

The **liver** images submitted revealed subjectively normal liver size, contour, and structure. Parenchymal echogenicity was naturally coarse and hypoechoic to the spleen. Vascular and biliary tracts were of normal volume with no evidence of congestion. The gallbladder presented acceptably thin walls with primarily anechoic content. The cystic and common bile ducts were normal. No pathological hepatic lymphadenopathy was evident. No overt structural evidence of inflammatory, infiltrative or regenerative pathology was evident.

## Gastrointestinal

The **gastrointestinal** presentation revealed mild uniform prominence of the gastric mucosa as well as areas of "ropy" small intestinal wall with slight disruption of the normal 1:3 muscularis/mucosal ratio. The intestinal submucosa was slightly irregular, thickened and hyperechoic suggestive of low grade, chronic disease. The mesenteric lymph nodes were reactive and measured up to 2.0 x 0.5 cm.

## Pancreas

The base and limbs of the **pancreas** were observed to be largely isoechoic to surrounding omental fat. Pancreatic duct and capsular contour were acceptably normal and parenchyma respected normal curvilinear patterns. No overt evidence of active inflammatory or neoplastic disease was noted.

## Heart

Rapid view of the heart revealed no evidence of pathology in the right atrium or right auricle. The volumes appeared normal and contractility was normal for a patient that was sedated with Dexdomitor.

## ULTRASONOGRAPHIC FINDINGS

- IBD GI pattern.

## INTERPRETATION OF THE FINDINGS & FURTHER RECOMMENDATIONS

There was no evidence of neoplasia.

Maldigestion panel, three view chest radiographs and full CNS examination is recommended to examine for occult disease that could be responsible for the weight loss. Evaluation for competitive eating environments should also be considered.



**PATIENT**

Dylan Simbeck

**SPECIES**

Canine

**BREED**

Flat Coated Retriever

**SEX**

Neutered male

**AGE**

6 years

**WEIGHT**

75 lbs

**INTERPRETED BY**

Eric Lindquist, DMV  
DABVP, Cert. IVUSS

**IMAGING PERFORMED BY**

Dr. Lincoski

**HOSPITAL NAME**

University Drive VH

**REFERRING VET**

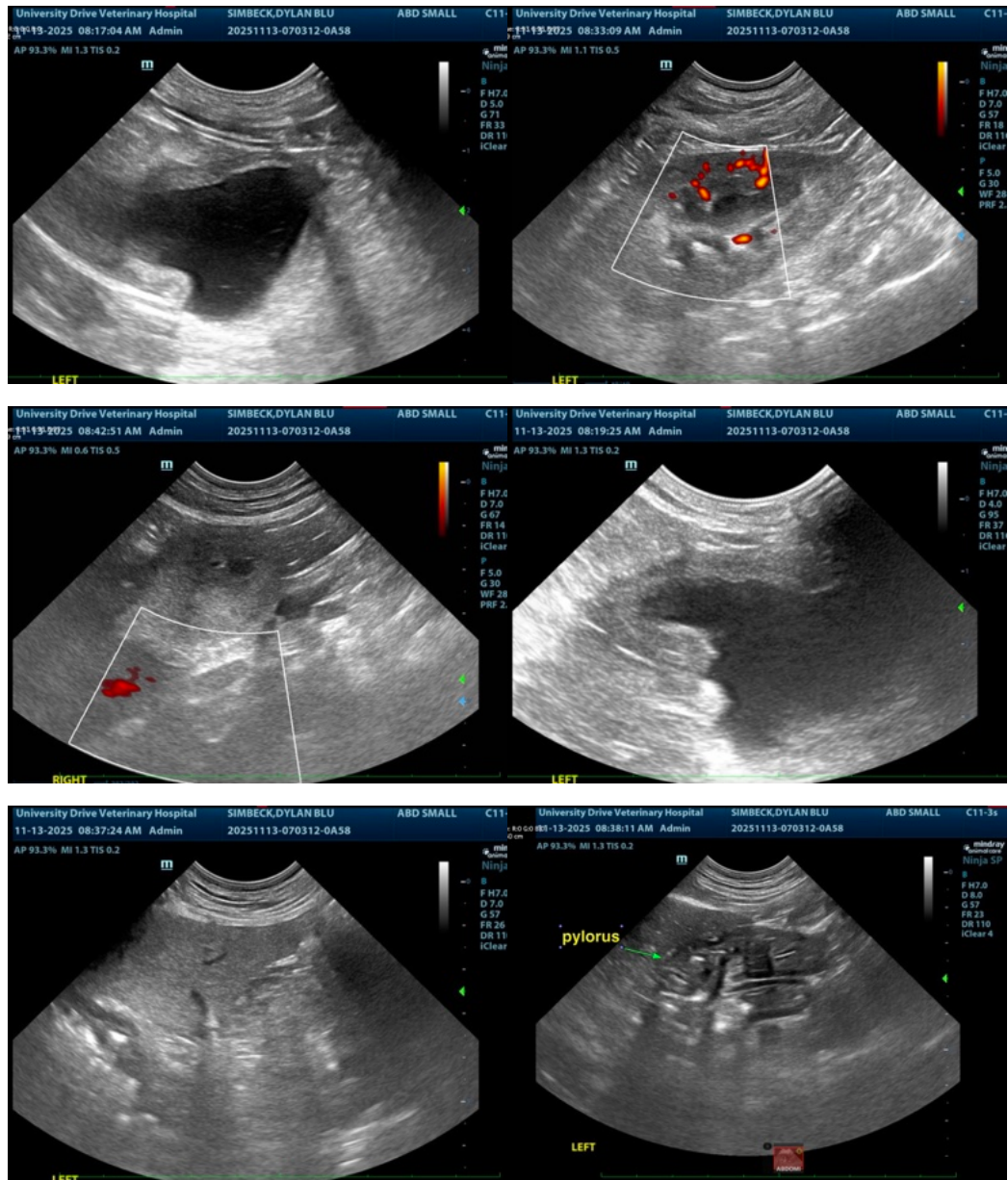
Dr. Lincoski

**INVOICE**

68674

**DATE**

11/13/25





## PATIENT

Dylan Simbeck

## SPECIES

Canine

## BREED

Flat Coated Retriever

## SEX

Neutered male

## AGE

6 years

## WEIGHT

75 lbs

## INTERPRETED BY

Eric Lindquist, DMV  
DABVP, Cert. IVUSS

## IMAGING PERFORMED BY

Dr. Lincoski

## HOSPITAL NAME

University Drive VH

## REFERRING VET

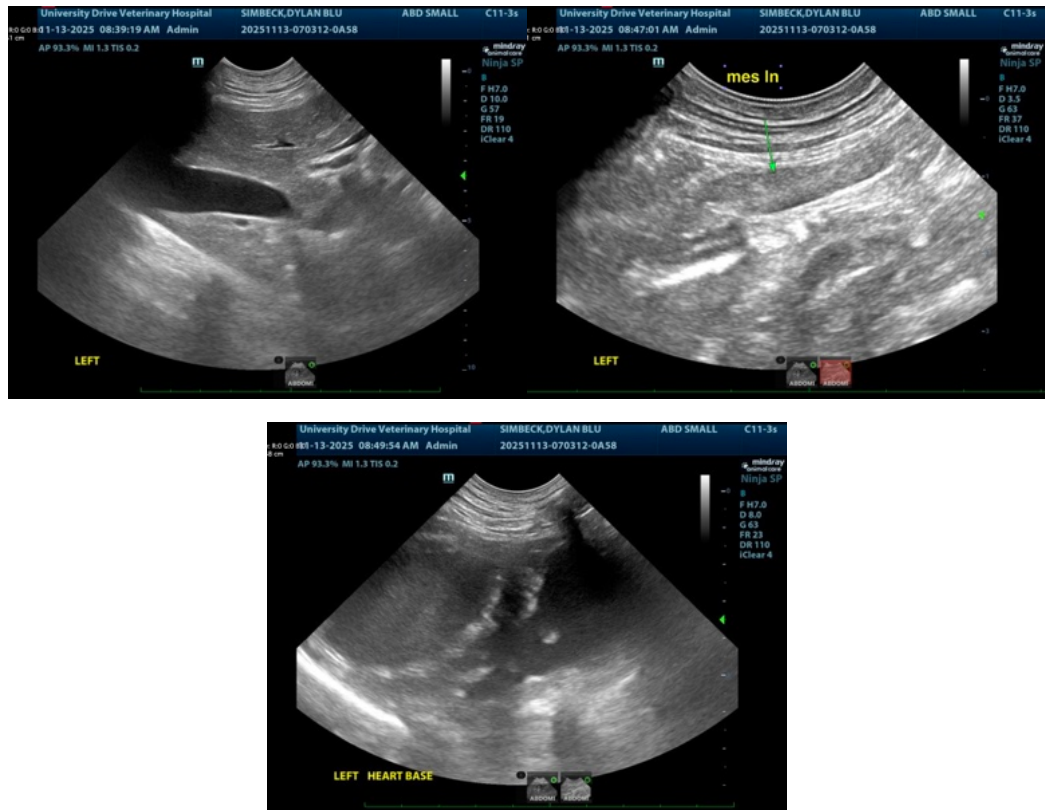
Dr. Lincoski

## INVOICE

68674

## DATE

11/13/25



The information and recommendations provided are based on the images presented by the referring veterinarian/sonographer. No evaluation can be communicated regarding pathology that was not visible in the image/video clips provided.

Thank you for this referral. If the clinical or image interpretation does not parallel your findings or if I can be of any further assistance please contact me.

Eric Lindquist, DMV, DABVP (CFM), Cert. IVUSS, CEO of SonoPath.com

[info@SonoPath.com](mailto:info@SonoPath.com)