



PATIENT

Chin Soderquist

SPECIES

Canine

BREED

Chinese Crested

SEX

Neutered male

AGE

12 years

WEIGHT

17.8 lbs

INTERPRETED BY

Eric Lindquist, DMV
DABVP, Cert. IVUSS

PRESENTING CLINICAL SIGNS

History: - P presented for echo to verify safe to undergo a dental for an infected tooth - P has grade 5/6 pansystolic murmur, P is not symptomatic - BAR, No C/S/V/D - Is P a candidate for Pimobendan? - VHS - 11.25
Abnormal PE/Chem/CBC/UA Results: 11/7/25 - ALKP - 392, ALT - 171

ULTRASONOGRAPHIC EXAMINATION OF THE HEART

The echocardiogram in this patient demonstrated enlarged **left atrial** size based on 3 different LA measurement methods. Chamber volumes and echogenicity were normal. The cranial and caudal **mitral** valve leaflets presented vegetative thickening consistent with endocardiosis. Doppler indicated measurable insufficiency. The **left ventricle** presented normal thicknesses with linear contour and was not dilated nor restricted. The **myocardium** presented normal echogenicity without subjective evidence of significant fibrotic or ischemic disease. **Contractility** of the ventricular walls was adequate and in normal range for this patient evidenced by the fractional shortening measurement and subjective evaluation of the different regions of the myocardium. The **left ventricular outflow** tract demonstrated normal laminar flow and subjective structural integrity. The **right atrium** and auricle revealed normal size, structure and content. No evidence of masses was noted or chamber overload. **Tricuspid** valvular assessment demonstrated adequate linear morphology. The **right ventricle** was of normal size (1/3 diameter of LV), chordae structure, myocardial echogenicity and thickness. **Pulmonic** tract assessment revealed normal valve structure, laminar flow, and diameter (approx. 1:1 pa/ao ratio). No visible **pericardial** or free pleura fluid was noted. No echographically detectable evidence of infiltrative disease was visible. The cranial **mediastinum and pericardial regions** were free of masses in the visible window.

IMAGING PERFORMED BY

Christina CVT

HOSPITAL NAME

Animal Health VC

REFERRING VET

Dr. Collazos

INVOICE

68613

DATE

11/13/25

CANINE CARDIAC PARAMETERS	MR VMAX (m/s)	TR VMAX (m/s)	LA/AO	LA/AO (Heart Base)	FS (%)	EF (%)	EPSS (cm)
NORMAL PARAMETER	4.5-5.5	<2.7	1.3	<1.6	28-40	40-100	<0.6
PATIENT	-	-	1.4	1.6	57	88	0.1
CANINE CARDIAC PARAMETERS	HR (BPM)	AV VMAX (m/s)	PV MAX (m/s)	BODY WEIGHT (kg)	LA 2D short axis Base view (cm)	LVIDd Avg; 2D and m-mode short axis (cm)	LVIDs Avg; 2D and m-mode short axis (cm)
NORMAL PARAMETER	50-100	0.7-1.7	0.7-1.6	BELOW	BELOW	BELOW	BELOW
PATIENT	80	-	-	17.8 lbs	3.8	3.57	

ULTRASONOGRAPHIC FINDINGS

- Stage B2 valvular disease.



PATIENT

Chin Soderquist

SPECIES

Canine

BREED

Chinese Crested

SEX

Neutered male

AGE

12 years

WEIGHT

17.8 lbs

INTERPRETED BY

Eric Lindquist, DMV
DABVP, Cert. IVUSS

IMAGING PERFORMED BY

Christina CVT

HOSPITAL NAME

Animal Health VC

REFERRING VET

Dr. Collazos

INVOICE

68613

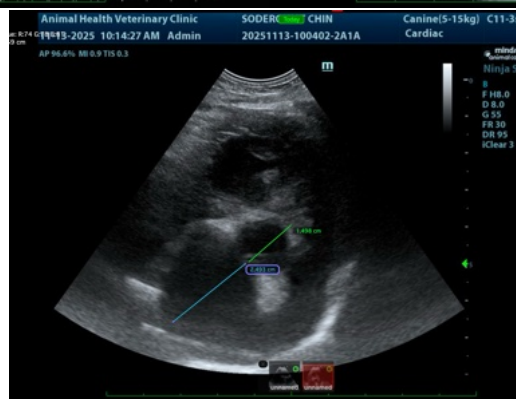
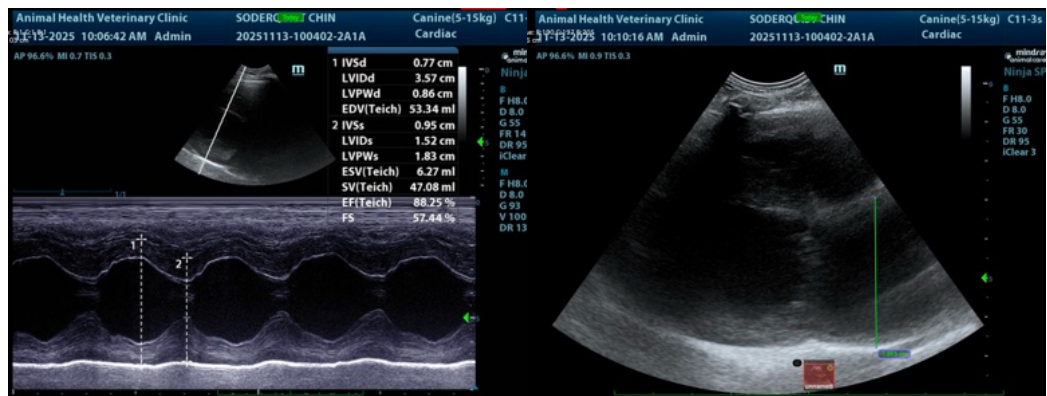
DATE

11/13/25

INTERPRETATION OF THE FINDINGS & FURTHER RECOMMENDATIONS

I recommend initiating Pimobendan at 0.3 mg/kg b.i.d. A recheck echocardiogram is recommended in 1 week. Serial blood pressure measurements are warranted if systolic pressure is > 160 then Telmisartan or ace inhibitor therapy is indicated. There is a mild anesthetic risk as is, if anesthesia is absolutely necessary then Torbutrol premed, Propofol induction and Isoflurane maintenance is recommended with minimal anesthetic time is recommended.

The heart has minor volume overload and is working to compensate for the valvular insufficiency. Target respiratory rate is < 20 resp/minute after therapy. After initiating or adjusting therapy, I recommend recheck on the clinical exam, BUN, Creatinine, USG, Chest radiographs & Blood pressure in 5-7 days. Recheck echo in 3-6 months, earlier if clinical decompensation is occurring. Minor anesthetic risk for a brief procedure at this time. Repeat preanesthetic echo is ideal if anesthesia is eventually necessary. A suggested anesthetic combination would involve Torbutrol premed, propofol induction, Isoflurane maintenance or equivalent protocol.



The information and recommendations provided are based on the images presented by the referring veterinarian/sonographer. No evaluation can be communicated regarding pathology that was not visible in the image/video clips provided.

Thank you for this referral. If the clinical or image interpretation does not parallel your findings or if I can be of any further assistance please contact me.

Eric Lindquist, DMV, DABVP (CFM), Cert. IVUSS, CEO of SonoPath.com



PATIENT

info@SonoPath.com

Chin Soderquist

SPECIES

Canine

BREED

Chinese Crested

SEX

Neutered male

AGE

12 years

WEIGHT

17.8 lbs

INTERPRETED BY

Eric Lindquist, DMV
DABVP, Cert. IVUSS

**IMAGING
PERFORMED BY**

Christina CVT

HOSPITAL NAME

Animal Health VC

REFERRING VET

Dr. Collazos

INVOICE

68613

DATE

11/13/25