



PATIENT

Katie Myers

SPECIES

Canine

BREED

Bloodhound

SEX

Spayed Female

AGE

9 Years

WEIGHT

81.7 lbs

INTERPRETED BY

Eric Lindquist, DMV
DABVP, Cert. IVUSS

IMAGING PERFORMED BY

Sarah Green

HOSPITAL NAME

Healing Spirit AW

REFERRING VET

Sarah Green

INVOICE

93095*

DATE

11/13/21

PRESENTING CLINICAL SIGNS

History: subdued behavior 2 days duration

Abnormal PE/Chem/CBC/UA Results: palpable splenomegaly, NAF otherwise. CBC - WNL, Chemistry: ALT=124 (10-118) U/L, NSF otherwise

ULTRASONOGRAPHIC EXAMINATION OF THE ABDOMEN

Urinary System

The **urinary bladder**, trigone, and pelvic urethra presented normal thicknesses and normal tone. The ureters were not visible which is normal. No uroliths or sediment were visualized and anechoic urine was present. No evidence of inflammatory or neoplastic changes were noted. Ureteral papillae were normal.

The left kidney revealed an anechoic cyst at the caudal pole. This may be what is being palpated. The cyst measured 4.0 cm. The right kidney was normal in size and contour measuring 6.0 cm.

Adrenal Glands

The left **adrenal gland** was visualized and recognized as having normal shape, size, position and echogenicity for this breed. The phrenic vasculature, glandular echogenicity and detail were unremarkable. Capsule, cortex, and medullary definition were normal for this age patient. The left adrenal gland measured 0.5 cm. The right of the right adrenal gland was imaged with no evidence of pathology.

Spleen

The **spleen** itself was unremarkable and uniform, yet folded upon itself cranially.

Liver

The **liver** was uniformly swollen with minor, excessive gallbladder debris and over distension with dependent and suspended bile without evidence of overt mucocele formation. However, excessive sludge was present. The liver presented coarse architecture with mildly increased portal markings and subtle, mixed echogenic changes. This is consistent with vacuolar hepatopathy and some level of remodeling and history of inflammatory component. There was no overt suspicion of neoplasia.

Gastrointestinal

The stomach was filled with progressively shadowing material. Prandial timing should be evaluated in this patient. A large amount of GI artifact was present. Small and large intestine demonstrated normal luminal chyme and stool consistency respectively.



PATIENT

Pancreas

Katie Myers

The base and limbs of the **pancreas** were observed to be largely isoechoic to surrounding omental fat. Pancreatic duct and capsular contour were acceptably normal and parenchyma respected normal curvilinear patterns. No overt evidence of active inflammatory or neoplastic disease was noted.

SPECIES

Canine

ULTRASONOGRAPHIC FINDINGS

BREED

Left renal cyst.
Full stomach.
Vacuolar hepatopathy pattern.

Bloodhound

SEX

INTERPRETATION OF THE FINDINGS & FURTHER RECOMMENDATIONS

Spayed Female

The left renal cyst is adjacent to the caudal pole of the spleen. The cranial pole of the spleen is folding and may be creating a fullness or mass effect, yet is not neoplastic. Screening for Addison's is warranted as the right adrenal gland was not overtly visible. Assessment for cardiogenic, orthopedic or CNS disease should be considered.

AGE

9 Years

WEIGHT

81.7 lbs

INTERPRETED BY

Eric Lindquist, DMV
DABVP, Cert. IVUSS

IMAGING PERFORMED BY

Sarah Green

HOSPITAL NAME

Healing Spirit AW

REFERRING VET

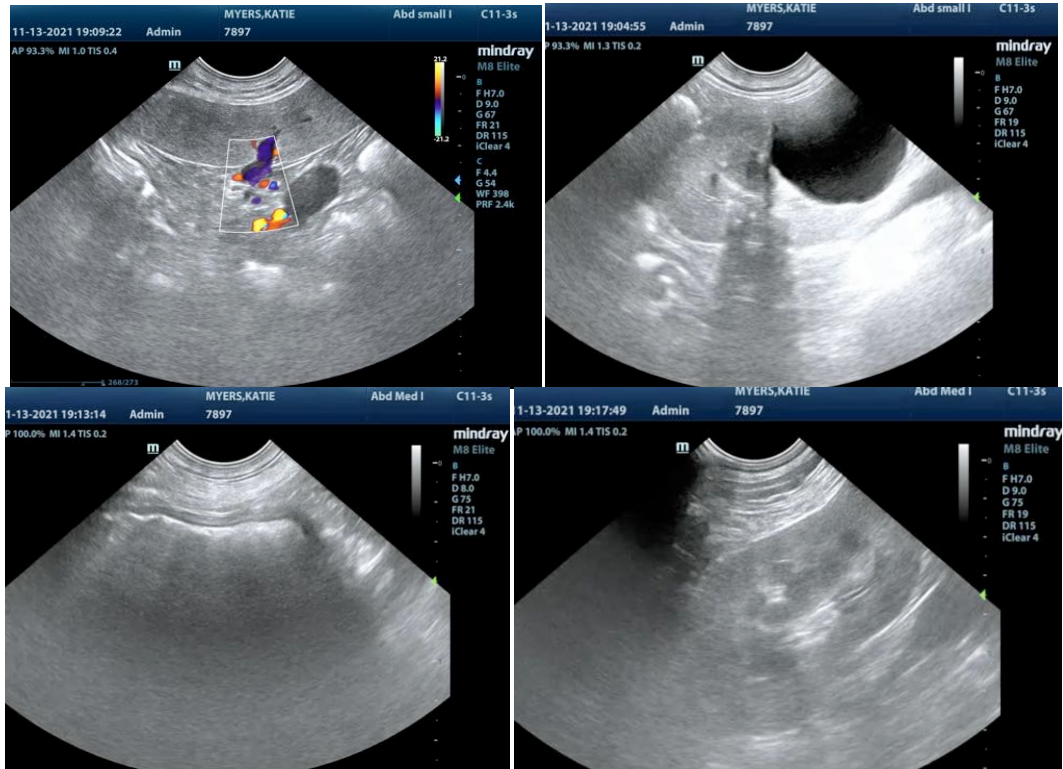
Sarah Green

INVOICE

93095*

DATE

11/13/21



The information and recommendations provided are based on the images presented by the referring veterinarian. No evaluation can be communicated regarding pathology that was not visible in the image/video clips provided.

Thank you for this referral. If the clinical or image interpretation does not parallel your findings or if I



PATIENT

can be of any further assistance please contact me.

Katie Myers

Eric Lindquist, DMV, DABVP, Cert. IVUSS, CEO of SonoPath.com
info@SonoPath.com

SPECIES

Canine

BREED

Bloodhound

SEX

Spayed Female

AGE

9 Years

WEIGHT

81.7 lbs

INTERPRETED BY

Eric Lindquist, DMV
DABVP, Cert. IVUSS

**IMAGING
PERFORMED BY**

Sarah Green

HOSPITAL NAME

Healing Spirit AW

REFERRING VET

Sarah Green

INVOICE

93095*

DATE

11/13/21