



PATIENT

Gracie Riles

SPECIES

Canine

BREED

Dachshund Mix

SEX

Spayed Female

AGE

13 Years

WEIGHT

7.5 kg

INTERPRETED BY

Eric Lindquist, DMV
DABVP, Cert. IVUSS

IMAGING PERFORMED BY

Dr. Woodside

HOSPITAL NAME

Sherwood FPC

REFERRING VET

Dr. Schlimgen

INVOICE

12522

DATE

11/13/21

PRESENTING CLINICAL SIGNS

History: Presented for annual exam without concerns by owner. Severity of heart murmur was considered increased so bloodwork, including proBNP was completed. Elevation of liver enzymes noted so abdominal ultrasound recommended.

Abnormal PE/Chem/CBC/UA Results: BCS 4/9, Grade V/VI systolic murmur, moderate dental calculus. ALT 258, ALP 183. proBNP 2285

ULTRASONOGRAPHIC EXAMINATION OF THE ABDOMEN

Urinary System

The **bladder** in this patient was mildly thickened with slight echogenic mural changes. No calculi or masses were noted. Anechoic urine present. Slight micropolypoid changes were noted. This is a frequent finding in older animals and may be linked to a history of chronic urinary tract infection or active urinary tract infection. Urinalysis would be recommended with culture if any evidence of inflammatory sediment is present. The region of the trigone and visible pelvic urethra were normal. This is a moderate change. No evidence of neoplasia. The pelvic urethra was imaged 2.0 cm beyond the cystourethral junction.

The **kidneys** revealed largely normal size and structure, corticomedullary definition and ratio (cortex 1/3 of medulla) were essentially maintained with some moderate age-related loss of curvilinear patterns regarding the capsule and C/M junction. The cortices presented largely uniform texture with some increased echogenicity expected for his age patient. Medullary structure differed distinctly from that of the cortex and no evidence of pelvic dilation was present. The right kidney measured 4.45 cm. Cortical cysts and infarcts noted. The left kidney measured 3.8 cm.

Adrenal Glands

Both **adrenal glands** were visualized and recognized as having normal shape, size, position and echogenicity for this breed. The phrenic vasculature, glandular echogenicity and detail were unremarkable. Capsule, cortex, and medullary definition were normal for this age patient. The left adrenal gland measured 0.55 cm. The right adrenal gland measured 0.76 cm.

Spleen

The **spleen** presented a smooth homogeneous parenchyma hyperechoic to liver and renal cortical parenchyma. The capsule was smooth without noticeable expansion or deviation from within the spleen or adjacent pathology. The splenic vasculature demonstrated normal volume without signs of congestion or thrombosis. No sonographic evidence of acute or chronic inflammatory, neoplastic, or infarctual changes were noted.

Liver

The **liver** was uniformly swollen with minor, excessive gallbladder debris and over distension with dependent and suspended bile without evidence of overt mucocele formation. However, excessive sludge was present. The liver presented coarse architecture with mildly increased portal markings and subtle, mixed echogenic changes. This is consistent with vacuolar hepatopathy and some level of remodeling and history of inflammatory component. There was no overt suspicion of neoplasia. This is a mild change.



PATIENT

Gracie Riles

SPECIES

Canine

BREED

Dachshund Mix

SEX

Spayed Female

AGE

13 Years

WEIGHT

7.5 kg

INTERPRETED BY

Eric Lindquist, DMV
DABVP, Cert. IVUSS

IMAGING PERFORMED BY

Dr. Woodside

HOSPITAL NAME

Sherwood FPC

REFERRING VET

Dr. Schlimgen

INVOICE

12522

DATE

11/13/21

Gastrointestinal

Examination of the **gastrointestinal tract** revealed a stomach and intestine free of stasis, of normal wall thickness, acceptable curvilinear mural detail, and peristaltic activity. Small and large intestine demonstrated normal luminal chyme and stool consistency respectively. No obstructive or overt infiltrative disease was noted. No associated abnormal lymphatic activity was noted.

Pancreas

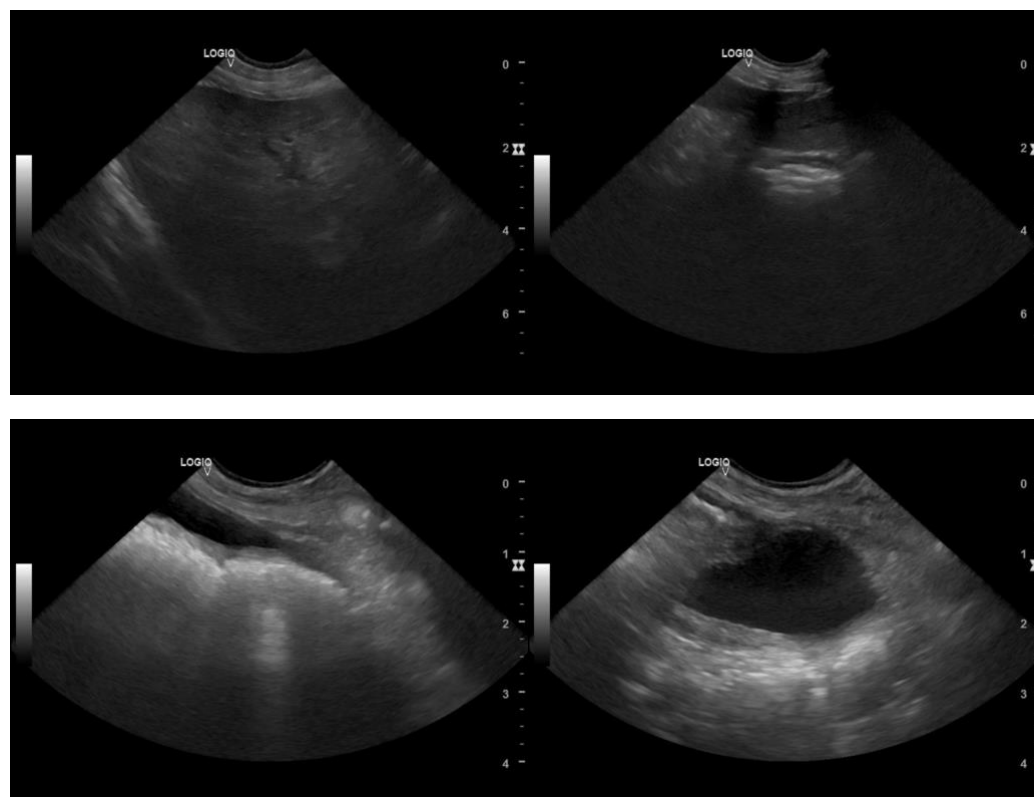
The base and limbs of the **pancreas** were observed to be largely isoechoic to surrounding omental fat. Pancreatic duct and capsular contour were acceptably normal and parenchyma respected normal curvilinear patterns. No overt evidence of active inflammatory or neoplastic disease was noted.

ULTRASONOGRAPHIC FINDINGS

- Moderate chronic degenerative renal changes with cysts and infarcts
- Age-related urinary bladder changes
- Subjectively benign vacuolar hepatopathy/with inflammatory component- FNA could be considered.

INTERPRETATION OF THE FINDINGS & FURTHER RECOMMENDATIONS

No evidence of neoplasia. Renal parameters should be monitored carefully in this patient long-term.





PATIENT

Gracie Riles

SPECIES

Canine

BREED

Dachshund Mix

SEX

Spayed Female

AGE

13 Years

WEIGHT

7.5 kg

INTERPRETED BY

Eric Lindquist, DMV
DABVP, Cert. IVUSS

IMAGING PERFORMED BY

Dr. Woodside

HOSPITAL NAME

Sherwood FPC

REFERRING VET

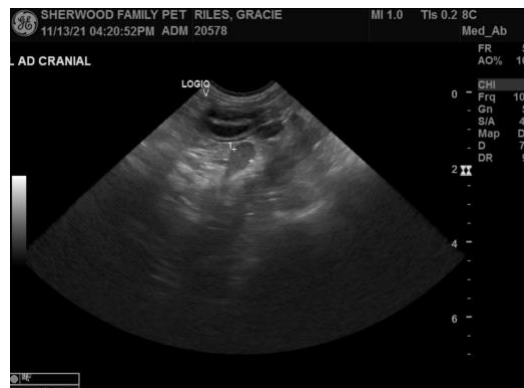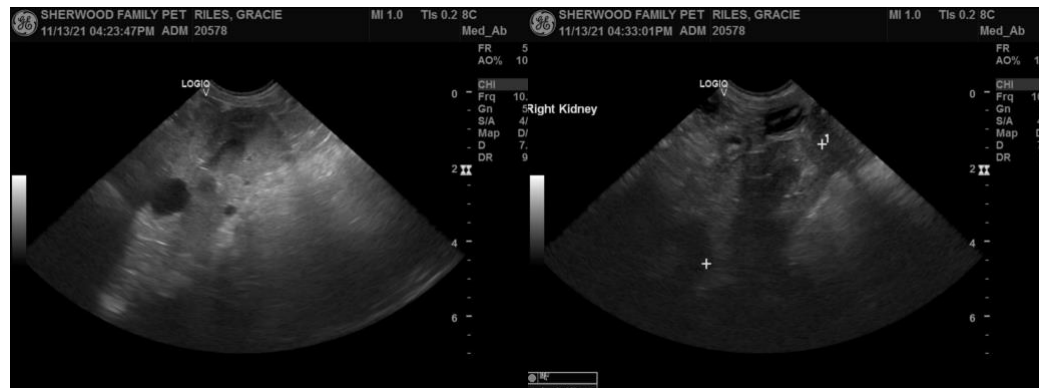Dr. Schlimgen

INVOICE

12522

DATE

11/13/21



The information and recommendations provided are based on the images presented by the referring veterinarian. No evaluation can be communicated regarding pathology that was not visible in the image/video clips provided.

Thank you for this referral. If the clinical or image interpretation does not parallel your findings or if I can be of any further assistance please contact me.

Eric Lindquist, DMV, DABVP, Cert. IVUSS, CEO of SonoPath.com
info@SonoPath.com