



## PATIENT

Kai Baker

## SPECIES

Feline

## BREED

Maine Coon

## SEX

Neutered male

## AGE

1 year

## WEIGHT

15.3 lbs

## INTERPRETED BY

Eric Lindquist, DMV  
DABVP, Cert. IVUSS

## IMAGING PERFORMED BY

Dr. Anleu

## HOSPITAL NAME

Ellwood AH

## REFERRING VET

Dr. Maro

## INVOICE

68630

## DATE

11/12/25

## PRESENTING CLINICAL SIGNS

History: Pet has been slow to gain weight. Vomited hairball 1 week ago- suspect overbarbering on ventral abdomen. Owner reports pet is losing a lot of fur / shedding more than usual for the past 3 weeks.

Abnormal PE/Chem/CBC/UA Results: Suspect enlarged mesenteric lymph nodes on abd ultrasound. Elevated HPT and TK1- suspect IBD.

## ULTRASONOGRAPHIC EXAMINATION OF THE ABDOMEN

### Urinary System

The **urinary bladder**, trigone, and pelvic urethra presented normal thicknesses and normal tone. The ureters were not visible which is normal. No uroliths or sediment were visualized and anechoic urine was present. No evidence of inflammatory or neoplastic changes was noted. Ureteral papillae were normal.

The **kidneys** revealed normal size and structure, corticomedullary definition and ratio for this age. The cortices presented largely uniform texture with normal echogenic relationship to liver and spleen. Medullary structure differed distinctly from the cortex and no evidence of pelvic dilation was present. The capsules were acceptably uniform without significant irregularities. The right kidney measured 4.45 cm and the left kidney measured 4.16 cm.

### Adrenal Glands

Both **adrenal glands** were visualized and recognized as having normal shape, size, position and echogenicity for this breed. The phrenic vasculature, glandular echogenicity and detail were unremarkable. Capsule, cortex, and medullary definition were normal for this age patient.

### Spleen

The **spleen** presented a smooth homogeneous parenchyma hyperechoic to liver and renal cortical parenchyma. The capsule was smooth without noticeable expansion or deviation from within the spleen or adjacent pathology. The splenic vasculature demonstrated normal volume without signs of congestion or thrombosis. No sonographic evidence of acute or chronic inflammatory, neoplastic, or infarctual changes was noted.

### Liver

The **liver** images submitted revealed subjectively normal liver size, contour, and structure. Parenchymal echogenicity was naturally coarse and hypoechoic to the spleen. Vascular and biliary tracts were of normal volume with no evidence of congestion. The gallbladder presented acceptably thin walls with primarily anechoic content. The cystic and common bile ducts were normal. No pathological hepatic lymphadenopathy was evident. No overt structural evidence of inflammatory, infiltrative or regenerative pathology was evident.



## PATIENT

Kai Baker

## SPECIES

Feline

## BREED

Maine Coon

## SEX

Neutered male

## AGE

1 year

## WEIGHT

15.3 lbs

## INTERPRETED BY

Eric Lindquist, DMV  
DABVP, Cert. IVUSS

## IMAGING PERFORMED BY

Dr. Anleu

## HOSPITAL NAME

Ellwood AH

## REFERRING VET

Dr. Maro

## INVOICE

68630

## DATE

11/12/25

## *Gastrointestinal*

Examination of the **gastrointestinal tract** revealed a stomach and intestine free of stasis, of normal wall thickness, acceptable curvilinear mural detail, and peristaltic activity. Small and large intestine demonstrated normal luminal chyme and stool consistency respectively. The mesenteric lymph nodes were reactive and juvenile measuring 1.5 x 1.0 cm.

## *Pancreas*

The base and limbs of the **pancreas** were observed to be largely isoechoic to surrounding omental fat. Pancreatic duct and capsular contour were acceptably normal and parenchyma respected normal curvilinear patterns. No overt evidence of active inflammatory or neoplastic disease was noted.

## ULTRASONOGRAPHIC FINDINGS

- Structurally unremarkable abdomen.
- Reactive mesenteric lymph node, yet essentially normal for this type of patient.

## INTERPRETATION OF THE FINDINGS & FURTHER RECOMMENDATIONS

There was no evidence of pathology. Malassimilation of nutrients should be rule out as a potential, yet structurally the abdomen appears unremarkable.

Internal medicine consult can be utilized through SonoPath.com. You can select the internal medicine drop down at <http://spa.sonopath.com/>.

One of the world's top internists & SonoPath associate Dr. Remo Lobetti BVSc, MMedVet, PhD, DECVIM can evaluate your case through SonoPath. <https://sonopath.com/resources/sonopath-services/internal-medicine-teleconsultation-services>



**PATIENT**

Kai Baker

**SPECIES**

Feline

**BREED**

Maine Coon

**SEX**

Neutered male

**AGE**

1 year

**WEIGHT**

15.3 lbs

**INTERPRETED BY**

Eric Lindquist, DMV  
DABVP, Cert. IVUSS

**IMAGING PERFORMED BY**

Dr. Anleu

**HOSPITAL NAME**

Ellwood AH

**REFERRING VET**

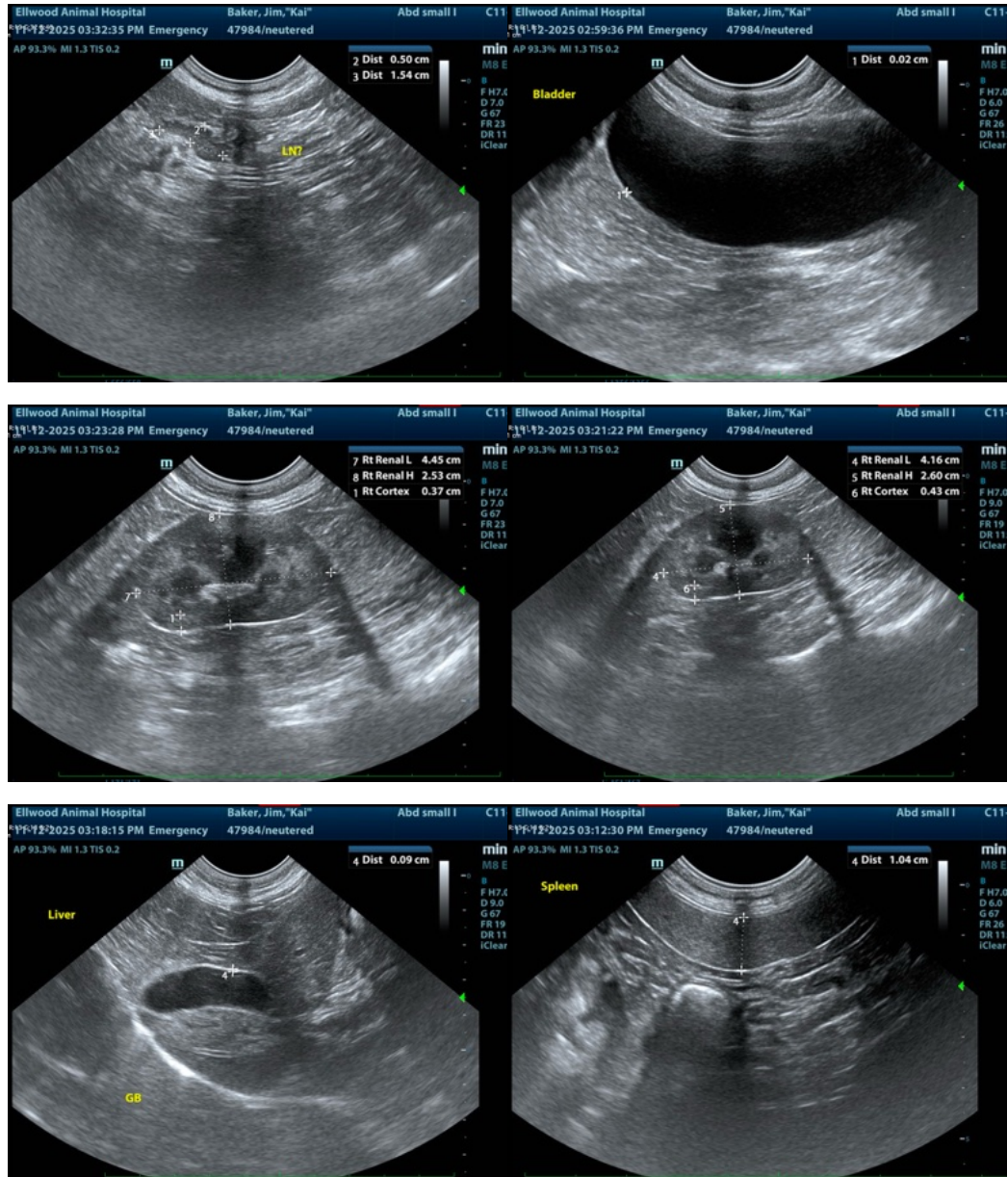
Dr. Maro

**INVOICE**

68630

**DATE**

11/12/25





## PATIENT

Kai Baker

## SPECIES

Feline

## BREED

Maine Coon

## SEX

Neutered male

## AGE

1 year

## WEIGHT

15.3 lbs

## INTERPRETED BY

Eric Lindquist, DMV  
DABVP, Cert. IVUSS

## IMAGING PERFORMED BY

Dr. Anleu

## HOSPITAL NAME

Ellwood AH

## REFERRING VET

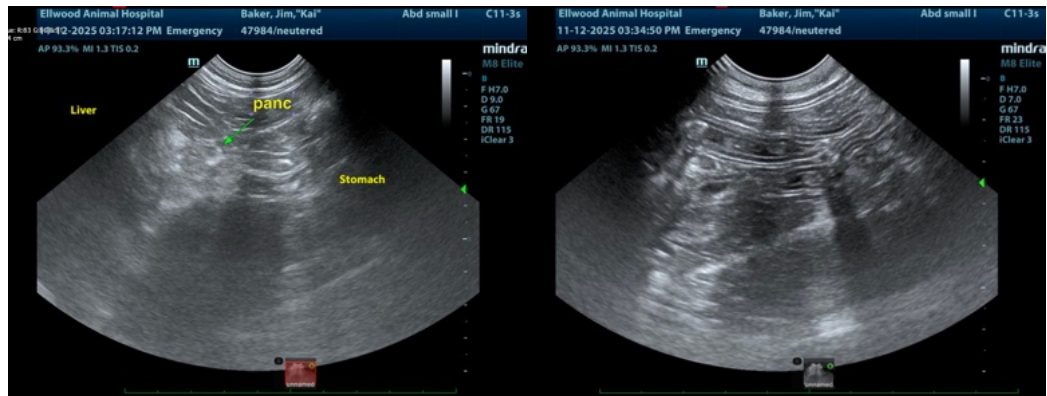
Dr. Maro

## INVOICE

68630

## DATE

11/12/25



The information and recommendations provided are based on the images presented by the referring veterinarian/sonographer. No evaluation can be communicated regarding pathology that was not visible in the image/video clips provided.

Thank you for this referral. If the clinical or image interpretation does not parallel your findings or if I can be of any further assistance please contact me.

Eric Lindquist, DMV, DABVP (CFM), Cert. IVUSS, CEO of SonoPath.com

[info@SonoPath.com](mailto:info@SonoPath.com)