



PATIENT PRESENTING CLINICAL SIGNS

PATIENT Sam Long
SPECIES Feline
 History: P presented on 11/2 for hiding and lethargy- O declined diagnostics and started Cerenia which helped. Presented again on 11/6 for vomiting with blood- declined diagnostics again and received Cerenia. Started eating and not vomiting. on 11/6, Went to rDVM where BW was performed (results listed). rDVM gave Convenia. P has been eating until today and vomited brown/bloody material today..
 Indoor only, lethargic. Unsure about diarrhea due to another cat in the household. Was diabetic last year but went into remission after 3m of treatment

BREED Manx
 Abnormal PE/Chem/CBC/UA Results: rDVM BW performed on 11/08: BUN 55 (16-36), SDMA 15 (0-14), Amylase 1618 (0-1500), Eos 1.3 (0.1-0.79) BW performed today: FPL positive, PT/aPTT NSF, Potassium 3.3 (3.6-5.6), BUN 74 (15-32), Glucose 215 (63-133), Creat 2.14 (0.5-1.9)

SEX ULTRASONOGRAPHIC EXAMINATION OF THE ABDOMEN

Neutered Male **Urinary System**

AGE 10 Pounds
 The **urinary bladder**, trigone, and pelvic urethra presented normal thicknesses and normal tone. The ureters were not visible which is normal. No uroliths or sediment were visualized and anechoic urine was present. No evidence of inflammatory or neoplastic changes were noted. Ureteral papillae were normal.

WEIGHT 5 kg
 The **kidneys** presented a relatively uniform cortical hyperechogenicity when compared to the renal medulla, spleen and liver. No overt masses were noted. Corticomedullary definition was nebulous and the ratio favored the cortex slightly. The ureters were not visible and assumed to be normal. These changes are most consistent with chronic interstitial nephritis yet infiltrative disease could not be entirely ruled out without biopsy though neoplasia is not suspected. These are mild to moderate changes. The left kidney measured 3.4 cm. Slight corticomedullary mineralization was noted in the right kidney. The right kidney measured 3.5 cm.

INTERPRETED BY

Eric Lindquist, DMV
 DABVP, Cert. IVUSS

Adrenal Glands

IMAGING PERFORMED BY The regions of the **adrenal glands** revealed no evident pathology.

Spleen

Kathleen Massa, DVM

HOSPITAL NAME

Animal Emergency
 Hospital

The **spleen** presented a smooth homogeneous parenchyma hyperechoic to liver and renal cortical parenchyma. The capsule was smooth without noticeable expansion or deviation from within the spleen or adjacent pathology. The splenic vasculature demonstrated normal volume without signs of congestion or thrombosis. No sonographic evidence of acute or chronic inflammatory, neoplastic, or infarctual changes were noted.

REFERRING VET

Kathleen Massa, DVM

Liver

The **liver** was normal in size and contour with slight increased portal markings. The gallbladder wall was slightly echogenic. A history of cholangitis is likely in this patient. Minor gallbladder polyps and gallbladder mineralizations were noted. Lobar mineralizations were noted.

INVOICE

17936

Gastrointestinal

DATE

11/12/22

The **gastrointestinal** presentation revealed mild uniform prominence of the gastric mucosa as well as areas of "ropy" small intestinal wall with slight disruption of the normal 1:3 muscularis/mucosal ratio. The intestinal submucosa was slightly irregular, thickened and hyperechoic suggestive of low grade,



PATIENT chronic disease. No concerning lymphadenopathy was visible. No evidence of obstruction was present. Chronic inflammatory bowel disease is likely with a low possibility of an early neoplastic event such as lymphoma. Full thickness tissue biopsies via open laparotomy, ideally guided by intraoperative ultrasound in order to obtain the most representative mural sample, would be necessary to rule out this possibility. This is a mild change.

Sam Long

SPECIES

Feline **Pancreas**

BREED

Manx

SEX

Neutered Male

AGE

10 Pounds

The base and limbs of the **pancreas** were observed to be largely isoechoic to surrounding omental fat. Some parenchymal remodeling, however, with mild deviation from curvilinear normalcy was observed. Pancreatic duct and capsular irregularities were present consistent with age related changes. If pain upon imaging (+ Murphy sign) was present or if the patient is focally painful in subxyphoid palpation then low-grade smoldering chronic pancreatitis should be suspected.

ULTRASONOGRAPHIC FINDINGS

- Chronic cholangitis liver pattern, likely owing to prior episodes of inflammatory events
- IBD GI pattern
- Mild chronic pancreatic changes
- Moderate chronic degenerative renal changes/interstitial nephrosis pattern

INTERPRETATION OF THE FINDINGS & FURTHER RECOMMENDATIONS

WEIGHT

5 kg

No evidence of neoplastic criteria in any organ system. I recommend a fresh fecal smear and fecal floatation analysis. A clinical trial of the following may prove effective. IV fluid support is recommended to treat the azotemia.

INTERPRETED BY

Eric Lindquist, DMV
DABVP, Cert. IVUSS

Triaditis/Pancreatitis protocol

Part or all of this protocol may be considered based on your clinical impression of the patient:

IMAGING PERFORMED BY

Kathleen Massa, DVM

HOSPITAL NAME

Animal Emergency
Hospital

REFERRING VET

Kathleen Massa, DVM

Recommend pain management when anorexic with **Buprenorphine** (0.01-0.02 mg/kg IM or SC), clinical trial of **Zithromax** (50 mg sid/cat x 10 days, 3 weeks if bartonella +), **Prednisolone** (0.5-2 mg/kg tapering over 1 week to minimal effective dose), and **B12 injections** if weight loss (Cyanobalamine 250 mcg sub-q once-weekly x six weeks, then every other week for six weeks and then once-monthly, long-term if necessary), **novel-protein or hydrolyzed diet** (*Hydrolyzed diets have been shown to be more effective in dietary intolerance case management compared to hypoallergenic diets*) or the **magical Purina DM** (changing protein source is crucial and may need rotation every 6 months if clinical signs recur) Diet trials is a whatever works phenomenon. If vomiting becomes a persistent issue then endoscopy would be warranted and/or recheck sonogram to assess more emerging disease. One diet does not work for all patients so different trials may be necessary or protein source rotation every 6 months as new sensitivities develop.

INVOICE

17936

DATE

11/12/22



PATIENT

Sam Long

SPECIES

Feline

BREED

Manx

SEX

Neutered Male

AGE

10 Pounds

WEIGHT

5 kg

INTERPRETED BY

Eric Lindquist, DMV
DABVP, Cert. IVUSS

IMAGING PERFORMED BY

Kathleen Massa, DVM

HOSPITAL NAME

Animal Emergency
Hospital

REFERRING VET

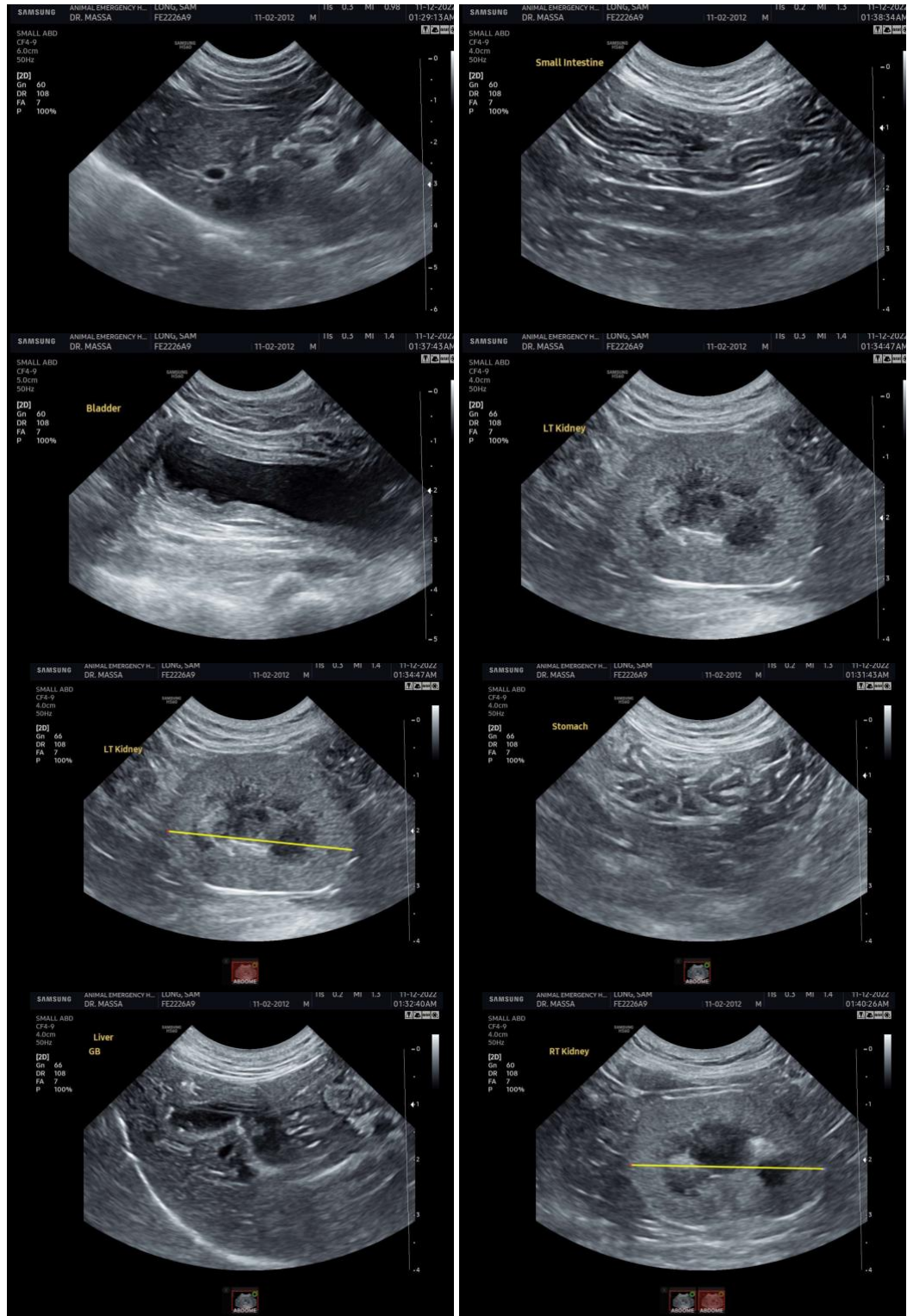
Kathleen Massa, DVM

INVOICE

17936

DATE

11/12/22





PATIENT

Sam Long

SPECIES

Feline

BREED

Manx

SEX

Neutered Male

AGE

10 Pounds

WEIGHT

5 kg

INTERPRETED BY

Eric Lindquist, DMV
DABVP, Cert. IVUSS

IMAGING PERFORMED BY

Kathleen Massa, DVM

HOSPITAL NAME

Animal Emergency
Hospital

REFERRING VET

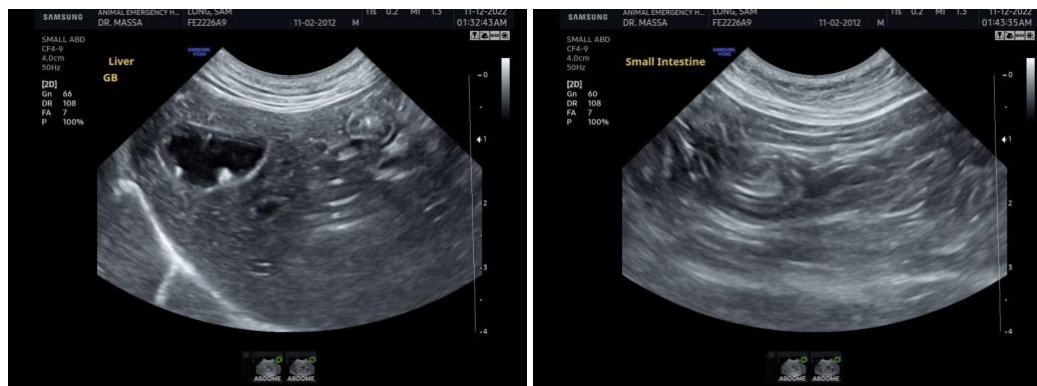
Kathleen Massa, DVM

INVOICE

17936

DATE

11/12/22



The information and recommendations provided are based on the images presented by the referring veterinarian. No evaluation can be communicated regarding pathology that was not visible in the image/video clips provided.

Thank you for this referral. If the clinical or image interpretation does not parallel your findings or if I can be of any further assistance please contact me.

Eric Lindquist, DMV, DABVP, Cert. IVUSS, CEO of SonoPath.com
info@SonoPath.com