



PATIENT

Satchel Nolan

PRESENTING CLINICAL SIGNS

acute onset vomiting; lethargy
Abnormal PE/Chem/CBC/UA Results: nsf

SPECIES

Feline

ULTRASONOGRAPHIC EXAMINATION OF THE ABDOMEN

Urinary System

BREED

DSH

The **urinary bladder**, trigone, and pelvic urethra presented normal thicknesses and normal tone. The ureters were not visible which is normal. No uroliths or sediment were visualized and anechoic urine was present. No evidence of inflammatory or neoplastic changes were noted. Ureteral papillae were normal.

SEX

Neutered Male

Iliac lymph nodes were enlarged, rounded and hypoechoic, measuring 1.5 cm.

AGE

13 Years

The **kidneys** presented a relatively uniform cortical hyperechogenicity when compared to the renal medulla, spleen and liver. No overt masses were noted. Corticomedullary definition was nebulous and the ratio favored the cortex slightly. The ureters were not visible and assumed to be normal. These changes are most consistent with chronic interstitial nephritis yet infiltrative disease could not be entirely ruled out without biopsy though neoplasia is not suspected. The left kidney measured 4.24 cm with multifocal pinpoint mineralizations, non-obstructive. The right kidney measured 4.1 cm.

WEIGHT

5.2 Pounds

Adrenal Glands

The **right adrenal gland** was uniform, yet bilaterally swollen and hypoechoic. This is most consistent with stress-induced hyperplasia. The right adrenal gland measured 0.62 cm. The region of the **left adrenal gland** was imaged, no evident pathology.

INTERPRETED BY

Eric Lindquist, DMV
DABVP, Cert. IVUSS

Spleen

The **spleen** was enlarged and irregular with scalloping contour, measuring 1.5 cm.

Liver

The **liver** presented multifocal cysts with disrupted architecture. Hepatic lymphadenopathy present. The gallbladder was unremarkable.

IMAGING PERFORMED BY

Diane McFadden

Gastrointestinal

HOSPITAL NAME

Rockaway AH

Examination of the **gastrointestinal tract** revealed a stomach and intestine free of stasis, of normal wall thickness, acceptable curvilinear mural detail, and peristaltic activity. Small and large intestine demonstrated normal luminal chyme and stool consistency respectively. No obstructive or overt infiltrative disease was noted. No associated abnormal lymphatic activity was noted.

REFERRING VET

Dr. Maniar

Pancreas

The base and limbs of the **pancreas** were observed to be largely isoechoic to surrounding omental fat. Pancreatic duct and capsular contour were acceptably normal and parenchyma respected normal curvilinear patterns. No overt evidence of active inflammatory or neoplastic disease was noted.

INVOICE

29785

Free Abdomen

DATE

11/12/21

Free fluid noted in the abdomen. Multifocal hypoechoic, distorted, rounded lymph nodes present up to 2.0 cm. Enhanced surrounding mesentery noted.



PATIENT

Satchel Nolan

ULTRASONOGRAPHIC FINDINGS

- Multifocal round cell neoplasia pattern involving the spleen, lymph nodes and possibly liver

SPECIES

Feline

INTERPRETATION OF THE FINDINGS & FURTHER RECOMMENDATIONS

FNA spleen and lymph nodes recommended. Prognosis is poor. Immediate chemotherapeutic intervention likely necessary.

BREED

DSH

SEX

Neutered Male

AGE

13 Years

WEIGHT

5.2 Pounds

INTERPRETED BY

Eric Lindquist, DMV
DABVP, Cert. IVUSS

IMAGING PERFORMED BY

Diane McFadden

HOSPITAL NAME

Rockaway AH

REFERRING VET

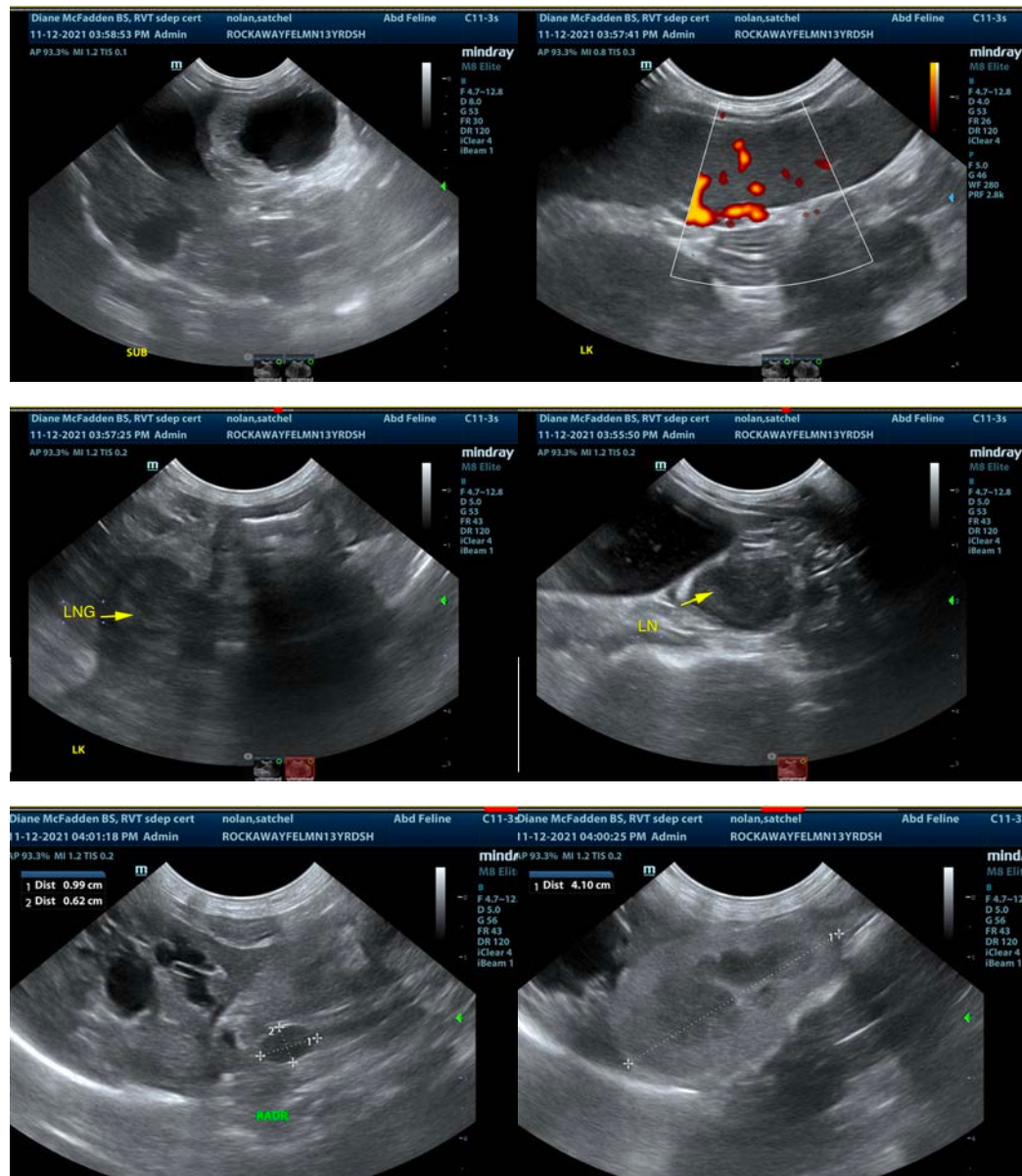
Dr. Maniar

INVOICE

29785

DATE

11/12/21





PATIENT

Satchel Nolan

SPECIES

Feline

BREED

DSH

SEX

Neutered Male

AGE

13 Years

WEIGHT

5.2 Pounds

INTERPRETED BY

Eric Lindquist, DMV
DABVP, Cert. IVUSS

**IMAGING
PERFORMED BY**

Diane McFadden

HOSPITAL NAME

Rockaway AH

REFERRING VET

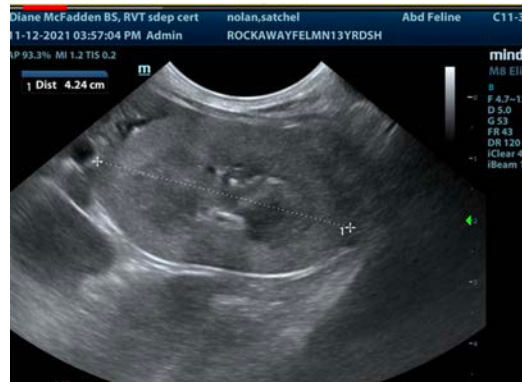Dr. Maniar

INVOICE

29785

DATE

11/12/21



The information and recommendations provided are based on the images presented by the referring veterinarian. No evaluation can be communicated regarding pathology that was not visible in the image/video clips provided.

Thank you for this referral. If the clinical or image interpretation does not parallel your findings or if I can be of any further assistance please contact me.

Eric Lindquist, DMV, DABVP, Cert. IVUSS, CEO of SonoPath.com
info@SonoPath.com