

**DATE PRESENTING CLINICAL SIGNS**

11/12/21

History: Referral for Continued Care, Not Eating, & Vomiting

PATIENT

Date: 11-12-2021 Notes: referral-- vomiting about 1 days rads rdvm large gas-- colon vs other referral for continued care, repeat film, to go back to RDVM for surgery if necessary.

Major Ingraio

SPECIES

Current Medications: Metronidazole 5mg/mL Injection (Per mL), Pantoprazole (Protonix) 40mg/vial Injection (Per mL), Buprenorphine 0.6mg/mL

Canine

Lab Results: Attached

BREED

Date of Previous IntraPet Ultrasound: No previous.

Catahoula

Sedation: IV sedative utilized for scan.

Stat Report: Not requested.

ULTRASONOGRAPHIC EXAMINATION OF THE ABDOMEN**SEX****Urinary System**

Neutered Male

The **urinary bladder**, trigone, and pelvic urethra presented normal thicknesses and normal tone. The ureters were not visible which is normal. No uroliths or sediment were visualized and anechoic urine was present. No evidence of inflammatory or neoplastic changes were noted. Ureteral papillae were normal.

AGE

2016

The **kidneys** revealed normal size and structure, corticomedullary definition and ratio for this age. The cortices presented largely uniform texture with normal echogenic relationship to liver and spleen. Medullary structure differed distinctly from the cortex and no evidence of pelvic dilation was present. The capsules were acceptably uniform without significant irregularities. The right kidney measured 6.26 cm. The left kidney measured 6.9 cm.

WEIGHT

66.7 lbs

Adrenal Glands**INTERPRETED BY**

Both **adrenal glands** were visualized and recognized as having normal shape, size, position and echogenicity for this breed. The phrenic vasculature, glandular echogenicity and detail were unremarkable. Capsule, cortex, and medullary definition were normal for this age patient. The right adrenal gland measured 2.56 cm x 0.98 cm at the cranial pole and 0.76 cm at the caudal pole. The left adrenal gland measured 2.62 cm x 0.83 cm at the caudal pole and 0.67 cm at the cranial pole.

Eric Lindquist, DMV
DABVP, Cert. IVUSS**IMAGING PERFORMED BY**

Rachel Brillhart RDMS

Spleen

The **spleen** presented a smooth homogeneous parenchyma hyperechoic to liver and renal cortical parenchyma. The capsule was smooth without noticeable expansion or deviation from within the spleen or adjacent pathology. The splenic vasculature demonstrated normal volume without signs of congestion or thrombosis. No sonographic evidence of acute or chronic inflammatory, neoplastic, or infarctual changes were noted.

HOSPITAL NAME

Animal Emergency H

Liver

The **liver** images submitted revealed subjectively normal liver size, contour, and structure. Parenchymal echogenicity was naturally coarse and hypoechoic to the spleen. Vascular and biliary tracts were of normal volume with no evidence of congestion. The gallbladder presented acceptably thin walls with primarily anechoic content. The cystic and common bile ducts were normal. No pathological hepatic lymphadenopathy was evident. No overt structural evidence of inflammatory, infiltrative or regenerative pathology was evident.

REFERRING VET

Dr. King

Gastrointestinal**INVOICE**

12502

The **stomach** itself was unremarkable. Soft stool and gas were noted in the colon. No evidence of foreign body.

Pancreas

The base and limbs of the **pancreas** were observed to be largely isoechoic to surrounding omental fat. Pancreatic duct and capsular contour were acceptably normal and parenchyma respected normal curvilinear patterns. No overt evidence of active inflammatory or neoplastic disease was noted.

Free Abdomen

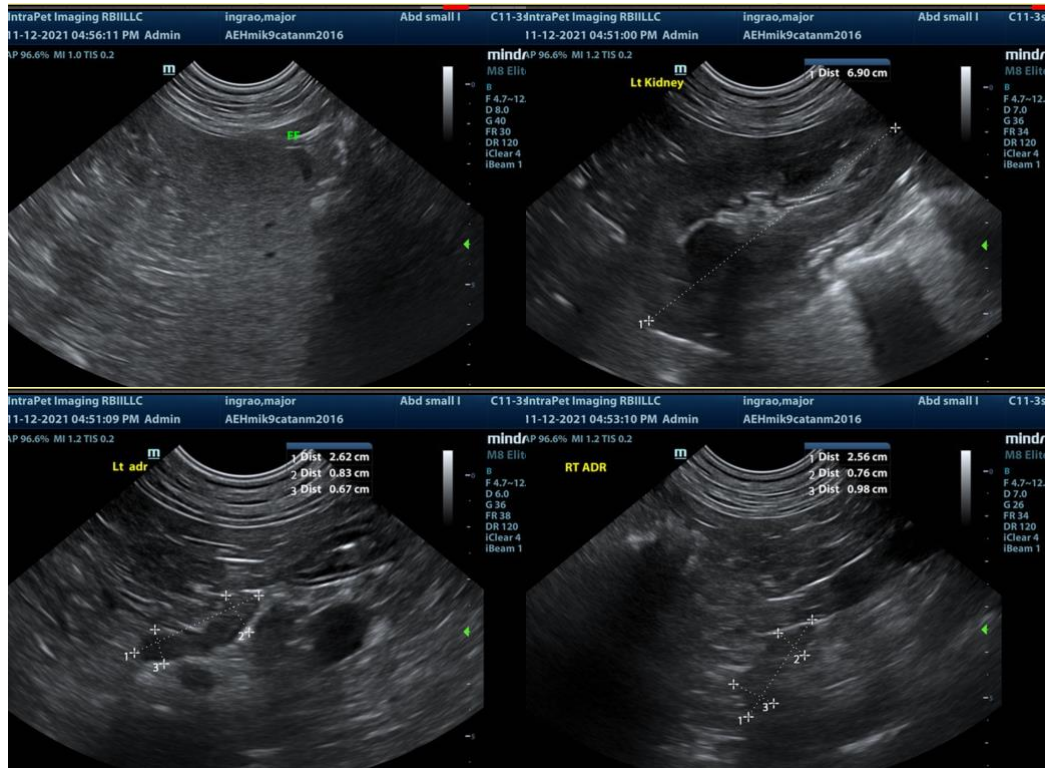
Trace amounts of free fluid were noted.

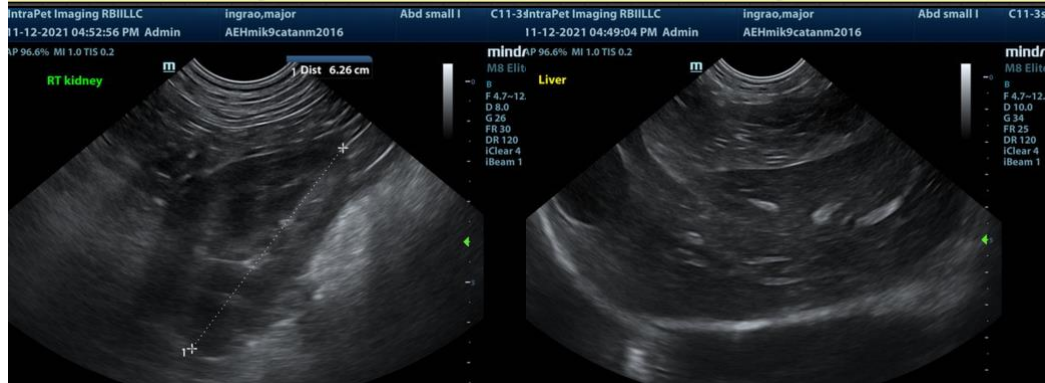
ULTRASONOGRAPHIC FINDINGS

- Resolving gastroenteritis

INTERPRETATION OF THE FINDINGS & FURTHER RECOMMENDATIONS

No evidence of surgical pathology.





The information and recommendations provided are based on the images presented by the referring veterinarian. No evaluation can be communicated regarding pathology that was not visible in the image/video clips provided.

Thank you for this referral. If the clinical or image interpretation does not parallel your findings or if I can be of any further assistance please contact me.

Eric Lindquist, DMV, DABVP, Cert. IVUSS, CEO of SonoPath.com
Eric.Lindquist@SonoPath.com