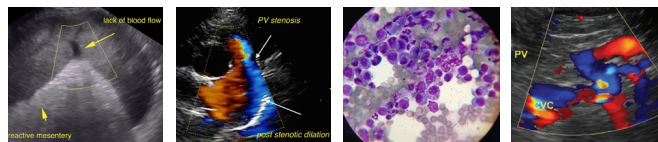


<b>PATIENT</b>	<b>PRESENTING CLINICAL SIGNS</b>
Elvis FJAH	T 100.5, HR 112, RR 32, BCS 3.5/5, PS 0/4, FAS green.
<b>SPECIES</b>	<b>ULTRASONOGRAPHIC EXAMINATION OF THE ABDOMEN</b>
Canine	<b>Urinary System</b>
<b>BREED</b>	The <b>urinary bladder</b> , trigone, and pelvic urethra presented normal thicknesses and normal tone. The ureters were not visible which is normal. No uroliths or sediment were visualized and anechoic urine was present. No evidence of inflammatory or neoplastic changes was noted. Ureteral papillae were normal.
Germand Shepherd	
<b>SEX</b>	The <b>kidneys</b> revealed normal size and structure, corticomedullary definition and ratio for this age. The cortices presented largely uniform texture with normal echogenic relationship to liver and spleen. Medullary structure differed distinctly from the cortex and no evidence of pelvic dilation was present. The capsules were acceptably uniform without significant irregularities.
Neutered male	
<b>AGE</b>	<b>Adrenal Glands</b>
10 years	Both <b>adrenal glands</b> were visualized and recognized as having normal shape, size, position and echogenicity for this breed. The phrenic vasculature, glandular echogenicity and detail were unremarkable. Capsule, cortex, and medullary definition were normal for this age patient.
<b>WEIGHT</b>	
69 lbs	
<b>INTERPRETED BY</b>	<b>Spleen</b>
Eric Lindquist, DMV DABVP, Cert. IVUSS	The <b>spleen</b> presented a smooth homogeneous parenchyma hyperechoic to liver and renal cortical parenchyma. The capsule was smooth without noticeable expansion or deviation from within the spleen or adjacent pathology. The splenic vasculature demonstrated normal volume without signs of congestion or thrombosis. No sonographic evidence of acute or chronic inflammatory, neoplastic, or infarctual changes was noted.
<b>HOSPITAL NAME</b>	
SDEP Lab	
<b>INVOICE</b>	<b>Liver</b>
93062	The <b>liver</b> images submitted revealed subjectively normal liver size, contour, and structure. Parenchymal echogenicity was naturally coarse and hypoechoic to the spleen. Vascular and biliary tracts were of normal volume with no evidence of congestion. The gallbladder presented acceptably thin walls with primarily anechoic content. The cystic and common bile ducts were normal. No pathological hepatic lymphadenopathy was evident. No overt structural evidence of inflammatory, infiltrative or regenerative pathology was evident.
<b>DATE</b>	
11/12/21	<b>Gastrointestinal</b>
	Examination of the <b>gastrointestinal tract</b> revealed a stomach and intestine free of stasis, of normal wall thickness, acceptable curvilinear mural detail, and peristaltic activity. Small and large intestine demonstrated normal luminal chyme and stool consistency respectively. No obstructive or overt infiltrative disease was noted. No associated abnormal lymphatic activity was noted.



**PATIENT**

Elvis FJAH

**Pancreas**

**SPECIES**

Canine

The base and limbs of the **pancreas** were observed to be largely isoechoic to surrounding omental fat. Pancreatic duct and capsular contour were acceptably normal and parenchyma respected normal curvilinear patterns. No overt evidence of active inflammatory or neoplastic disease was noted.

**BREED**

German Shepherd

**ULTRASONOGRAPHIC EXAMINATION OF THE HEART**

**SEX**

Neutered male

The echocardiogram in this patient demonstrated normal **left atrial** size based on 3 separate methods of LA evaluation. The cranial and caudal **mitral** valve leaflets presented normal linear structure, extension in systole, and union in diastole with normal kinesis. The **left ventricle** presented thicknesses with linear contour and was not dilated nor restricted. The **myocardium** presented normal echogenicity without subjective evidence of significant fibrotic or ischemic disease. **Contractility** of the ventricular walls was adequate and in normal range for this patient evidenced by the fractional shortening measurement and subjective evaluation of the different regions of the myocardium. The **left ventricular outflow** tract demonstrated normal laminar flow and subjective structural integrity. The **right atrium** and auricle revealed normal size, structure and content. No evidence of masses was noted. **Tricuspid** valvular assessment demonstrated adequate linear morphology and kinesis. The **right ventricle** was of normal size (1/3 diameter of LV), chordae structure, myocardial echogenicity and thickness. **Pulmonary outflow** tract assessment revealed normal valve structure, laminar flow, and diameter (approx.1:1 pa/ao ratio). No visible **pericardial** or free pleura fluid was noted. The cranial **mediastinum and pericardial and extra-cardiac regions** were free of masses in the visible window.

**AGE**

10 years

**WEIGHT**

69 lbs

**INTERPRETED BY**

Eric Lindquist, DMV  
DABVP, Cert. IVUSS

**ULTRASONOGRAPHIC FINDINGS**

Normal abdomen.

Normal echocardiogram.

**HOSPITAL NAME**

SDEP Lab

**INTERPRETATION OF THE FINDINGS & FURTHER RECOMMENDATIONS**

No specific therapy is recommended at this time.

**INVOICE**

93062

The information and recommendations provided are based on the images presented by the referring veterinarian. No evaluation can be communicated regarding pathology that was not visible in the image/video clips provided.

**DATE**

11/12/21

Thank you for this referral. If the clinical or image interpretation does not parallel your findings or if I can be of any further assistance please contact me.

**Eric Lindquist, DMV, DABVP, Cert. IVUSS, CEO of SonoPath.com**  
Eric.Lindquist@SonoPath.com