

**DATE PRESENTING CLINICAL SIGNS**

11/12/21

History: Presented on 10/26/21 for urinating during sleep and dribbling urine while walking, UA showed hematuria (25 Ery/uL) started on Clavamox 62.5mg 1/2 tab PO BID x 1 week. PE was wnl.

**PATIENT**

Recheck on 11/2/21, urinating while walking has resolved, will still urinate while sleeping. No accidents during the day.

Charlotte Hylock

Current Medications: nothing current.

Date of Previous IntraPet Ultrasound: No previous.

Sedation: Not required for a urinary ultrasound.

Stat Report: Not requested.

**SPECIES**

Canine

**LIMITED ULTRASONOGRAPHIC EXAMINATION****BREED**

Bichon Frise X

The **urinary bladder**, trigone, and pelvic urethra presented normal thicknesses and normal tone. The ureters were not visible which is normal. No uroliths or sediment were visualized and anechoic urine was present. No evidence of inflammatory or neoplastic changes were noted. Ureteral papillae were normal.

**SEX**

Intact Female

The **kidneys** revealed idiopathic hyperechoic medullary rim with mineralization. Vascularity appeared normal. The left kidney measured 3.35 cm. The right kidney measured 3.5 cm. No evidence of ectopic ureters.

**AGE**

7/13/21

The uterus measured 2.0 mm.

**ULTRASONOGRAPHIC FINDINGS****WEIGHT**

5.8 Pounds

- Idiopathic medullary rim kidney – may be a form of primary dysplasia, however this is common in this breed.

**INTERPRETATION OF THE FINDINGS & FURTHER RECOMMENDATIONS****INTERPRETED BY**

Eric Lindquist, DMV  
DABVP, Cert. IVUSS

No evidence of ectopic ureters, yet could not be completely ruled out. If ectopic ureter is suspected despite supportive care, CT with contrast would be appropriate. Cystoscopy could be considered as well to fully rule out ectopic ureters. However, the ureteral papillae were clearly visible and appeared to be intact.

**IMAGING PERFORMED BY**

Stephanie Pearce  
RDCS, RVT

**HOSPITAL NAME**

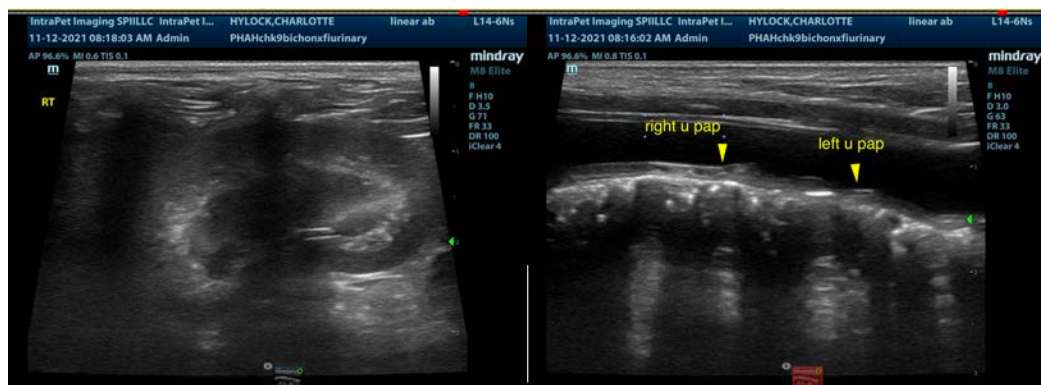
Perry Hall AH

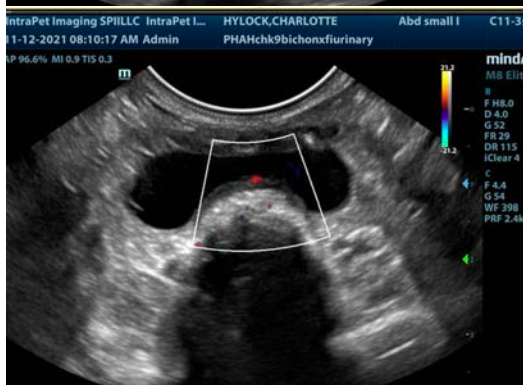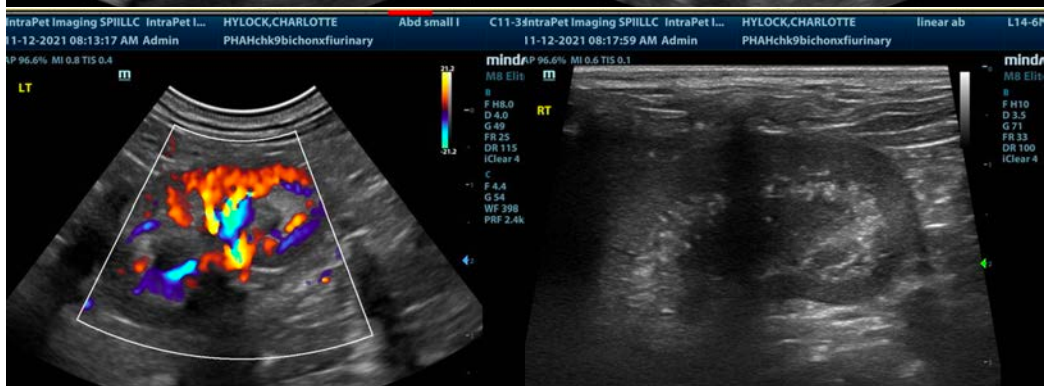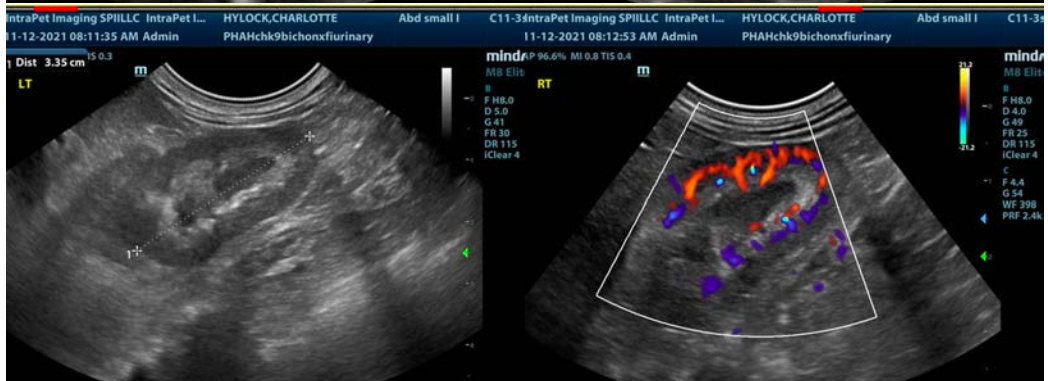
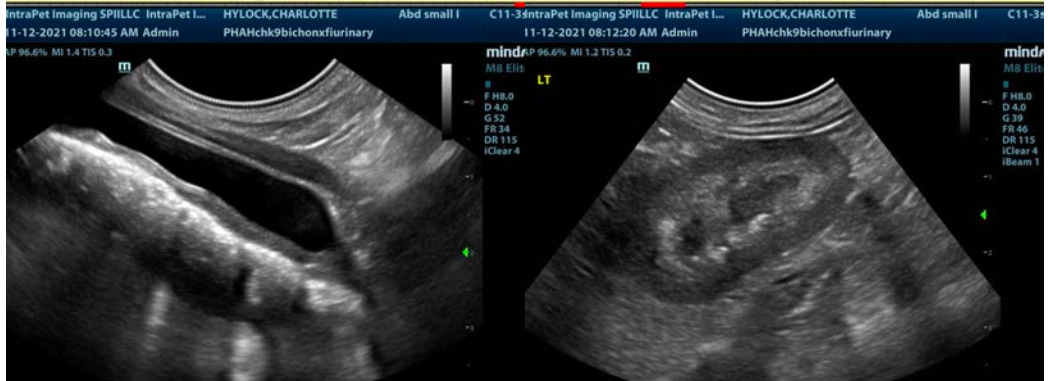**REFERRING VET**

Dr. Baer

**INVOICE**

29813





**The information and recommendations provided are based on the images presented by the referring veterinarian. No evaluation can be communicated regarding pathology that was not visible in the image/video clips provided.**

Thank you for this referral. If the clinical or image interpretation does not parallel your findings or if I can be of any further assistance please contact me.

**Eric Lindquist**, DMV, DABVP, Cert. IVUSS, CEO of SonoPath.com  
Eric.Lindquist@SonoPath.com