



**PATIENT**

Cannoli Sommers

**PRESENTING CLINICAL SIGNS**

vomiting bile

**SPECIES**

Canine

**ULTRASONOGRAPHIC EXAMINATION OF THE ABDOMEN**

**Urinary System**

The **urinary bladder**, trigone, and pelvic urethra presented normal thicknesses and normal tone. The ureters were not visible which is normal. No uroliths or sediment were visualized and anechoic urine was present. No evidence of inflammatory or neoplastic changes were noted. Ureteral papillae were normal.

**BREED**

Corgi

**SEX**

Neutered Male

The **kidneys** revealed normal size and structure, corticomedullary definition and ratio for this age. The cortices presented largely uniform texture with normal echogenic relationship to liver and spleen. Medullary structure differed distinctly from the cortex and no evidence of pelvic dilation was present. The capsules were acceptably uniform without significant irregularities. The right kidney measured 5.05 cm. The left kidney measured 4.62 cm.

**AGE**

1.5 Years

**Adrenal Glands**

Both **adrenal glands** were visualized and recognized as having normal shape, size, position and echogenicity for this breed. The phrenic vasculature, glandular echogenicity and detail were unremarkable. Capsule, cortex, and medullary definition were normal for this age patient. The left adrenal gland measured 1.73 cm x 0.49 cm at the caudal pole and 0.35 cm at the cranial pole. The right adrenal gland measured 2.17 cm x 0.45 cm at the caudal pole and 0.70 cm at the cranial pole.

**WEIGHT**

35 Pounds

**Spleen**

The **spleen** presented a smooth homogeneous parenchyma hyperechoic to liver and renal cortical parenchyma. The capsule was smooth without noticeable expansion or deviation from within the spleen or adjacent pathology. The splenic vasculature demonstrated normal volume without signs of congestion or thrombosis. No sonographic evidence of acute or chronic inflammatory, neoplastic, or infarctual changes were noted.

**INTERPRETED BY**

Eric Lindquist, DMV  
DABVP, Cert. IVUSS

**IMAGING PERFORMED BY**

Diane McFadden

**Liver**

The **liver** itself was uniform with no evidence of pathology. The gallbladder wall was edematous.

**HOSPITAL NAME**

Rockaway AH

**Gastrointestinal**

Examination of the **gastrointestinal tract** revealed a stomach and intestine free of stasis, of normal wall thickness, acceptable curvilinear mural detail, and peristaltic activity. Small and large intestine demonstrated normal luminal chyme and stool consistency respectively. No obstructive or overt infiltrative disease was noted. No associated abnormal lymphatic activity was noted. No evidence of foreign body.

**REFERRING VET**

Dr. Maniar

**Pancreas**

Minor enhanced mesentery noted in the right **pancreatic** limb.

**INVOICE**

29790

**ULTRASONOGRAPHIC FINDINGS**

- Gastritis/minor pancreatitis right limb
- Cholangitis

**DATE**

11/12/21



**PATIENT**

Cannoli Sommers

**SPECIES**

Canine

**BREED**

Corgi

**SEX**

Neutered Male

**AGE**

1.5 Years

**WEIGHT**

35 Pounds

**INTERPRETED BY**

Eric Lindquist, DMV  
DABVP, Cert. IVUSS

**IMAGING PERFORMED BY**

Diane McFadden

**HOSPITAL NAME**

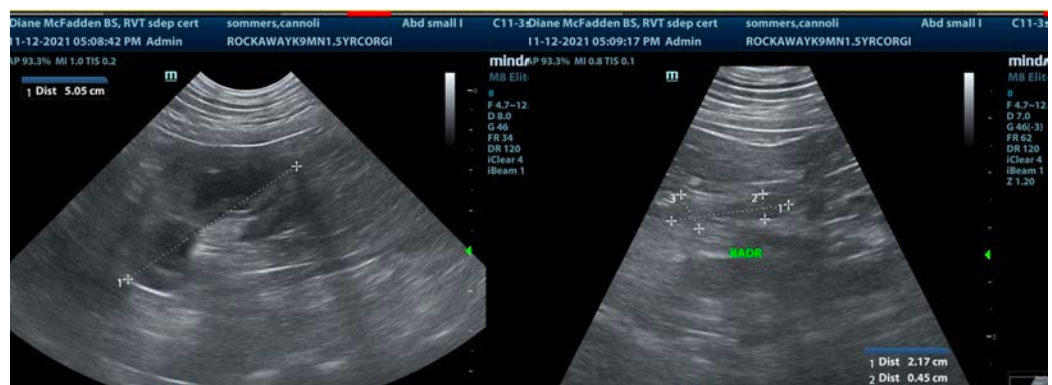
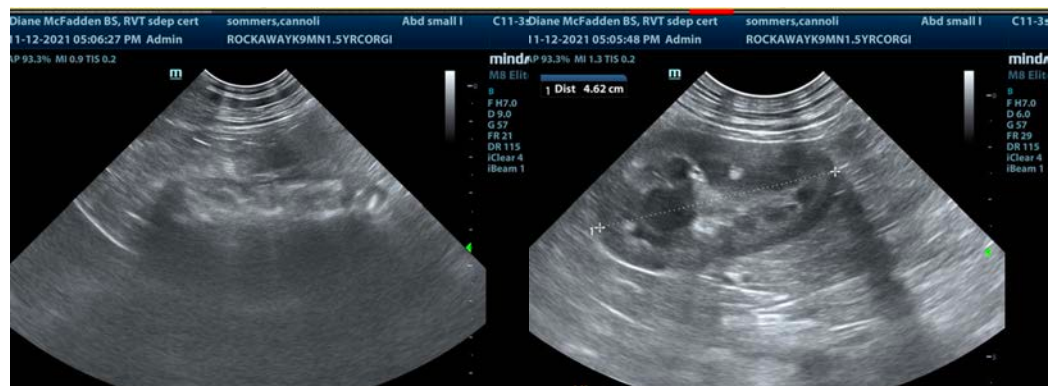
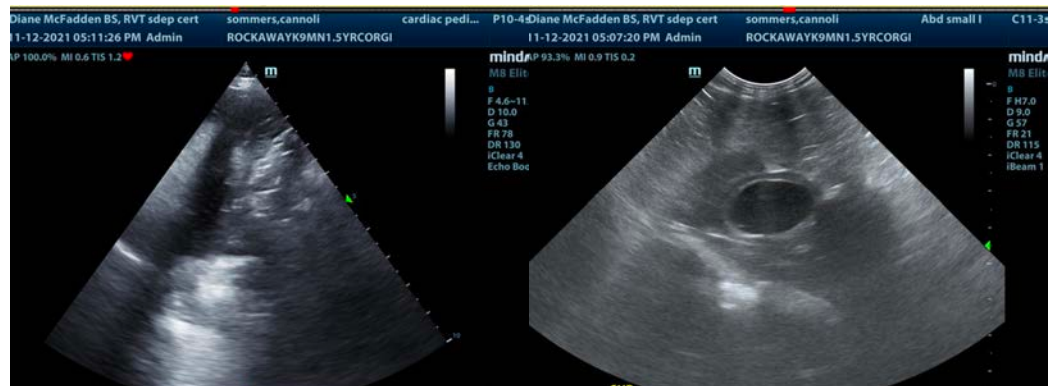
Rockaway AH

**REFERRING VET**

Dr. Maniar

**INTERPRETATION OF THE FINDINGS & FURTHER RECOMMENDATIONS**

GI protectant protocol with Enrofloxacin/Metronidazole combination recommended. 24-hour NPO and reassessment of the clinical signs recommended. Recheck sonogram in 48-72 hours. No evidence of foreign body.



**INVOICE**

29790

**DATE**

11/12/21



**PATIENT**

Cannoli Sommers

**SPECIES**

Canine

**BREED**

Corgi

**SEX**

Neutered Male

**AGE**

1.5 Years

**WEIGHT**

35 Pounds

**INTERPRETED BY**

Eric Lindquist, DMV  
DABVP, Cert. IVUSS

**IMAGING PERFORMED BY**

Diane McFadden

**HOSPITAL NAME**

Rockaway AH

**REFERRING VET**

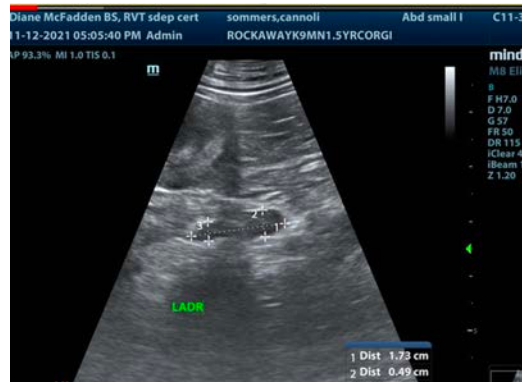Dr. Maniar

**INVOICE**

29790

**DATE**

11/12/21



The information and recommendations provided are based on the images presented by the referring veterinarian. No evaluation can be communicated regarding pathology that was not visible in the image/video clips provided.

Thank you for this referral. If the clinical or image interpretation does not parallel your findings or if I can be of any further assistance please contact me.

Eric Lindquist, DMV, DABVP, Cert. IVUSS, CEO of SonoPath.com  
[info@SonoPath.com](mailto:info@SonoPath.com)