



PATIENT

Moxie Moore

SPECIES

Feline

BREED

DSH

SEX

Neutered Male

AGE

16 Years

WEIGHT

6.8 lbs

PRESENTING CLINICAL SIGNS

Heart murmur

ULTRASONOGRAPHIC EXAMINATION OF THE HEART

FELINE CARDIAC PARAMETERS	BODY WEIGHT (lbs)	HR (BPM)	IVSd (cm)	LVIDd (cm)	LVWd (cm)	FS (%)	EF (%)
NORMAL PARAMETER	-----	150-240	0.3-0.6	1.0-2.1	0.25-0.6	35-67	80-100
PATIENT	6.8	NM	0.49	1.6	0.54	30	80
FELINE CARDIAC PARAMETERS	LA/AO (M-mode)	LA/AO HEART BASE (Sisson)	LAD LA MAX 4 Chamber	LVOT VEL. (m/s)	RVOT VEL. (m/s)	IVRT (m)	
NORMAL PARAMETER	<1.5	1.6	0.7-1.7	<1.6	<1.3	40-60	
PATIENT	2.8	>2.5	2.0	0.92	0.5	NM	

Adapted from June Boon, Veterinary Echocardiography, 1998
Sisson D et al. JVIM 1991; 5: 232, Jacobs et al. Am J Vet Res 1985; 46:1705

INTERPRETED BY

Eric Lindquist, DMV, DABVP (CFM), Cert. IVUSS

IMAGING PERFORMED BY

Rebecca Hamilton

HOSPITAL NAME

Companion Animal Hospital Parsippany

REFERRING VET

Dr. Wolf

INVOICE

71703

DATE

11/11/25

Cardiac Presentation

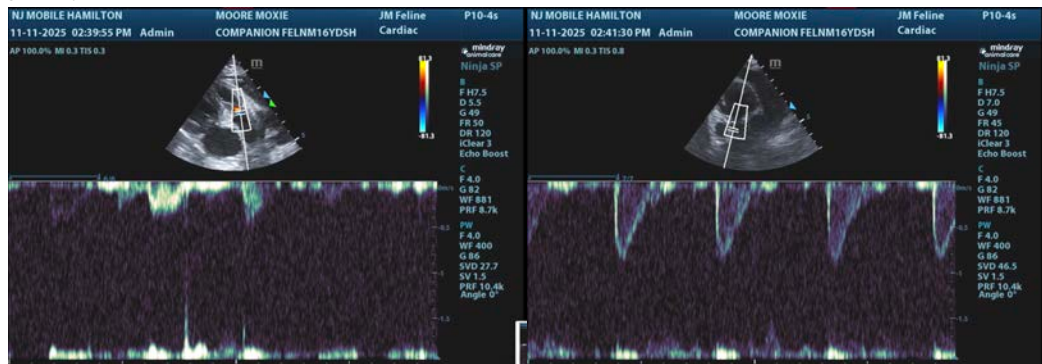
The cardiac presentation revealed volume overload in all four chambers. Mitral and tricuspid insufficiency noted. Septal and free wall thicknesses were measurably normal, yet contractility was poor. Pleural effusion noted as well as slight pericardial effusion.

ULTRASONOGRAPHIC FINDINGS

- Left and right-sided heart failure, unclassified cardiomyopathy.

INTERPRETATION OF THE FINDINGS & FURTHER RECOMMENDATIONS

Recommend triple therapy in this patient with Pimobendan 0.3 mg/kg BID, Lasix at 6.25-12.5 mg BID, and ACE inhibitor 0.5 mg/kg SID. Plavix therapy also indicated. Recheck echo in one months. Prognosis is guarded.





PATIENT

Moxie Moore

SPECIES

Feline

BREED

DSH

SEX

Neutered Male

AGE

16 Years

WEIGHT

6.8 lbs

INTERPRETED BY

Eric Lindquist, DMV,
 DABVP (CFM), Cert. IVUSS

IMAGING PERFORMED BY

Rebecca Hamilton

HOSPITAL NAME

Companion Animal
 Hospital Parsippany

REFERRING VET

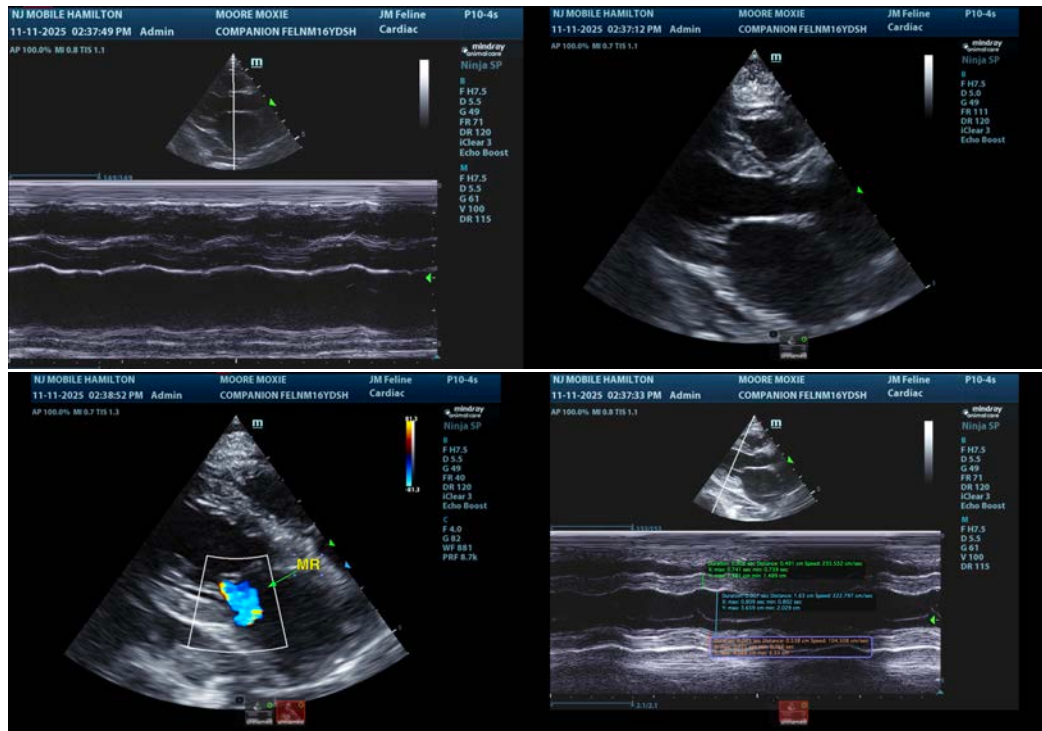
Dr. Wolf

INVOICE

71703

DATE

11/11/25



The information and recommendations provided are based on the images presented by the referring veterinarian/sonographer. No evaluation can be communicated regarding pathology that was not visible in the image/video clips provided.

Thank you for this referral. If the clinical or image interpretation does not parallel your findings or if I can be of any further assistance please contact me.

Eric Lindquist, DMV, DABVP(CFM), Cert. IVUSS,
 CEO, Owner, Founder -- SonoPath.com
info@SonoPath.com