



PATIENT

Hastings Barnard

SPECIES

Feline

BREED

DSH

SEX

Neutered Male

AGE

10 Years

WEIGHT

16.8

INTERPRETED BY

Eric Lindquist, DMV,
DABVP (CFM), Cert.
IVUSS

IMAGING PERFORMED BY

JK

HOSPITAL NAME

Hamburg Veterinary
Clinic

REFERRING VET

Dr. Martens

INVOICE

71694

DATE

11/11/25

PRESENTING CLINICAL SIGNS

Possible kidney stone seen on xray. Nausea after eating
Abnormal PE/Chem/CBC/UA Results: Blood normal, Urine pending

ULTRASONOGRAPHIC EXAMINATION OF THE ABDOMEN

Urinary System

The **urinary bladder**, trigone, and pelvic urethra presented normal thicknesses and normal tone. The ureters were not visible which is normal. No uroliths or sediment were visualized and anechoic urine was present. No evidence of inflammatory or neoplastic changes were noted. Ureteral papillae were normal. The pelvic urethra was imaged 2.0 cm beyond the cystourethral junction.

The **kidneys** revealed largely normal size and structure, corticomedullary definition and ratio (cortex 1/3 of medulla) were essentially maintained with some age-related loss of curvilinear patterns regarding the capsule and C/M junction. The cortices presented largely uniform texture with some increased echogenicity expected for his age patient. Medullary structure differed distinctly from that of the cortex and no evidence of pelvic dilation was present. Minor mineralization noted in both kidneys. The right kidney measured 4.8 cm. The left kidney measured 3.54 cm.

Adrenal Glands

The **left adrenal gland** was visualized and recognized as having normal shape, size, position and echogenicity for this breed. The phrenic vasculature, glandular echogenicity and detail were unremarkable. Capsule, cortex, and medullary definition were normal for this age patient. The left adrenal gland measured 0.38 cm.

The region of the **right adrenal gland** was imaged, no evident pathology.

Spleen

The **spleen** was mildly enlarged (1.33 cm) with uniform, but subtly micronodular parenchyma, and undulating capsular contour. This is consistent with reactive spleen owing to immune stimulus or early infiltrative disease such as mast cell disease or lymphoma. 25-gauge FNA would be ideal if weight loss is an issue to differentiate early round cell neoplasia versus splenitis or reactive spleen all of which can present in this manner. Occasional hyperechoic lipid plaques noted.

Liver

The **liver** images submitted revealed subjectively normal liver size, contour, and structure. Parenchymal echogenicity was naturally coarse and hypoechoic to the spleen. Vascular and biliary tracts were of normal volume with no evidence of congestion. The gallbladder presented acceptably thin walls with primarily anechoic content. The cystic and common bile ducts were normal. No pathological hepatic lymphadenopathy was evident. No overt structural evidence of inflammatory, infiltrative or regenerative pathology was evident.

Gastrointestinal

Examination of the **gastrointestinal tract** revealed a stomach and intestine free of stasis, of normal wall thickness, acceptable curvilinear mural detail, and peristaltic activity. Small and large intestine demonstrated normal luminal chyme and stool consistency respectively. No obstructive or overt infiltrative disease was noted. No associated abnormal lymphatic activity was noted.



PATIENT

Hastings Barnard

SPECIES

Feline

BREED

DSH

SEX

Neutered Male

AGE

10 Years

WEIGHT

16.8

INTERPRETED BY

Eric Lindquist, DMV,
DABVP (CFM), Cert.
IVUSS

IMAGING PERFORMED BY

JK

HOSPITAL NAME

Hamburg Veterinary
Clinic

REFERRING VET

Dr. Martens

INVOICE

71694

DATE

11/11/25

Pancreas

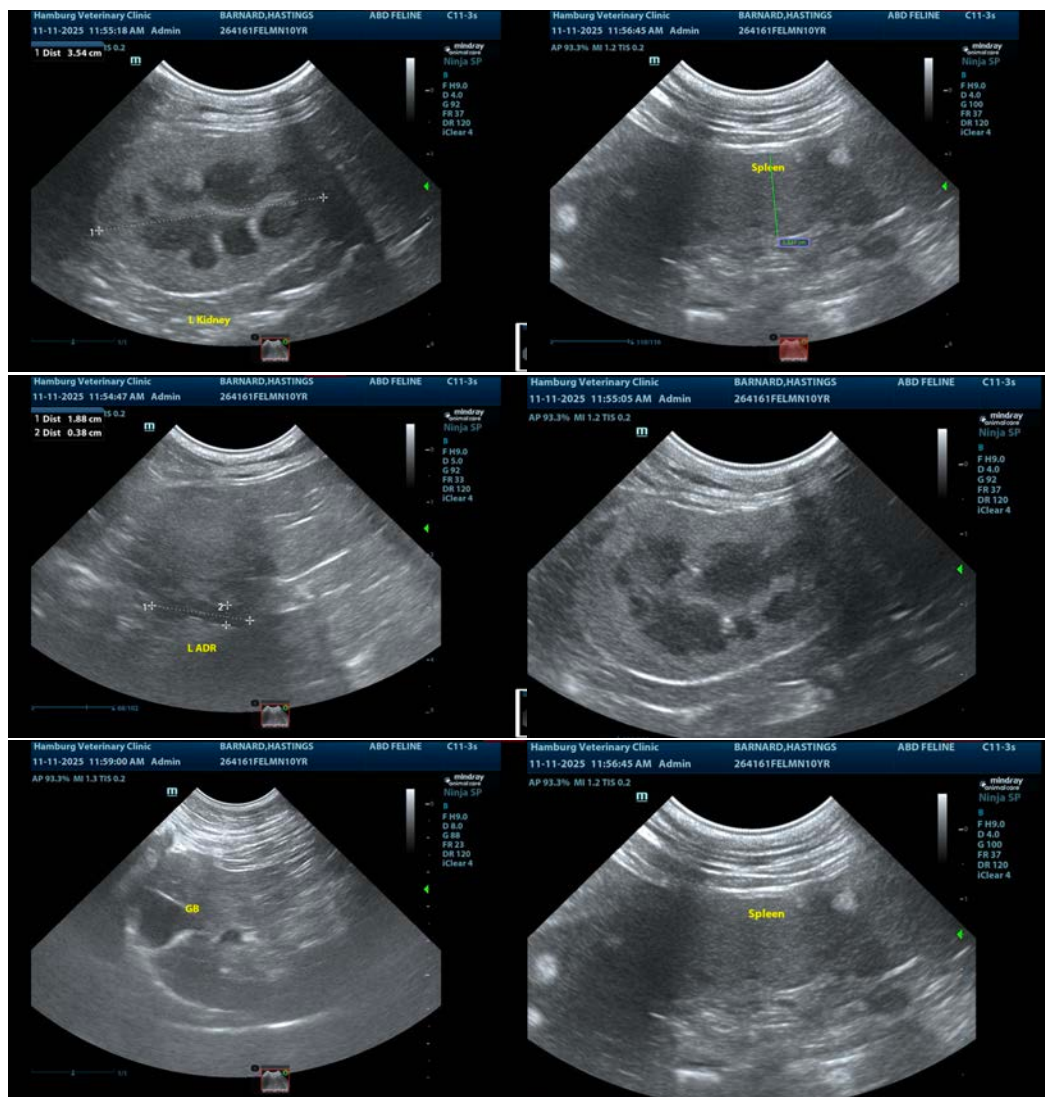
The base and limbs of the **pancreas** were observed to be largely isoechoic to surrounding omental fat. Pancreatic duct and capsular contour were acceptably normal and parenchyma respected normal curvilinear patterns. No overt evidence of active inflammatory or neoplastic disease was noted.

ULTRASONOGRAPHIC FINDINGS

- Mild splenic enlargement with lipid plaques.
- Age related renal changes with minor mineralization, non-obstructive.
- Structurally normal GI tract.

INTERPRETATION OF THE FINDINGS & FURTHER RECOMMENDATIONS

FNA of the spleen indicated. Reactive spleen versus emerging round cell neoplasia are concerns.





PATIENT

Hastings Barnard

SPECIES

Feline

BREED

DSH

SEX

Neutered Male

AGE

10 Years

WEIGHT

16.8

INTERPRETED BY

Eric Lindquist, DMV,
DABVP (CFM), Cert.
IVUSS

IMAGING PERFORMED BY

JK

HOSPITAL NAME

Hamburg Veterinary
Clinic

REFERRING VET

Dr. Martens

INVOICE

71694

DATE

11/11/25

The information and recommendations provided are based on the images presented by the referring veterinarian/sonographer. No evaluation can be communicated regarding pathology that was not visible in the image/video clips provided.

Thank you for this referral. If the clinical or image interpretation does not parallel your findings or if I can be of any further assistance please contact me.

Eric Lindquist, DMV, DABVP(CFM), Cert. IVUSS,
CEO, Owner, Founder -- SonoPath.com
info@SonoPath.com