



<b>PATIENT</b>	<b>PRESENTING CLINICAL SIGNS</b>
Ranger Wittkamper	History: Ranger was diagnosed with pancreatitis by the rDVM a few days ago. Outpatient plan was elected, p showed no improvement. Continues to be anorexia, V+, and having D+. P transferred today for hospitalization.
<b>SPECIES</b>	
Canine	Abnormal PE/Chem/CBC/UA Results: Elevated Amylase, Lipase, ALT 185
<b>BREED</b>	<b>ULTRASONOGRAPHIC EXAMINATION OF THE ABDOMEN</b>
Wire Fox Terrier	<b>Urinary System</b>
<b>SEX</b>	The <b>urinary bladder</b> , trigone, and pelvic urethra presented normal thicknesses and normal tone. The ureters were not visible which is normal. No uroliths or sediment were visualized, and anechoic urine was present. No evidence of inflammatory or neoplastic changes were noted. Ureteral papillae were normal. The pelvic urethra was imaged 3.0 cm beyond the cystourethral junction. The residual prostate measured 5.0 mm.
Neutered Male	
<b>AGE</b>	The <b>kidneys</b> revealed normal size and structure, corticomedullary definition and ratio for this age. The cortices presented largely uniform texture with normal echogenic relationship to liver and spleen. Medullary structure differed distinctly from the cortex and no evidence of pelvic dilation was present. The capsules were acceptably uniform without significant irregularities. The left kidney measured 4.7 cm. The right kidney measured 4.7 cm.
8.5 Years	
<b>WEIGHT</b>	<b>Adrenal Glands</b>
10.2 kg	Both <b>adrenal glands</b> were visualized and recognized as having normal shape, size, position and echogenicity for this breed. The phrenic vasculature, glandular echogenicity and detail were unremarkable. Capsule, cortex, and medullary definition were normal for this age patient.
<b>INTERPRETED BY</b>	<b>Spleen</b>
Eric Lindquist, DMV DABVP, Cert. IVUSS	The <b>spleen</b> revealed a microcystic nodule, measuring 5.0 mm at the caudal pole of the spleen. Minor heterogeneous changes were noted elsewhere in the spleen.
<b>IMAGING PERFORMED BY</b>	<b>Liver</b>
Carver	The <b>liver</b> images submitted revealed subjectively normal liver size, contour, and structure. Parenchymal echogenicity was naturally coarse and hypoechoic to the spleen. Vascular and biliary tracts were of normal volume with no evidence of congestion. The gallbladder presented acceptably thin walls with primarily anechoic content. The cystic and common bile ducts were normal. No pathological hepatic lymphadenopathy was evident. No overt structural evidence of inflammatory, infiltrative or regenerative pathology was evident.
<b>HOSPITAL NAME</b>	<b>Gastrointestinal</b>
Animal Emergency Hospital Volusia	The upper <b>gastrointestinal tract</b> in this patient revealed minor, edematous wall. There was no evidence of foreign bodies. Minor areas of fluctuant fluid accumulation were noted within the lumen with hyperperistalsis. This pattern continued to the ileocecal valve. The colon was empty. This presentation is most consistent with gastrointestinal irritation/inflammation without obstruction. This is a minor change.
<b>REFERRING VET</b>	
Carver	
<b>INVOICE</b>	<b>Pancreas</b>
17934	
<b>DATE</b>	
11/11/22	



## PATIENT

Ranger Wittkamper

The base and limbs of the **pancreas** were observed to be largely isoechoic to surrounding omental fat. Pancreatic duct and capsular contour were acceptably normal and parenchyma respected normal curvilinear patterns. No overt evidence of active inflammatory or neoplastic disease was noted.

## SPECIES

Canine

## Free Abdomen

The mesenteric **lymph nodes** (up to 1.0 cm x 0.5 cm) presented normal length to width ratio with slight, swollen contour. There was no loss of parenchymal detail. This is most consistent with reactive lymphadenitis or lymphatic hyperplasia.

## BREED

Wire Fox Terrier

## ULTRASONOGRAPHIC FINDINGS

- Nonspecific gastrointestinal irritability pattern
- Reactive mesenteric lymph nodes
- Splenic nodule

## SEX

Neutered Male

## INTERPRETATION OF THE FINDINGS & FURTHER RECOMMENDATIONS

## AGE

8.5 Years

Occult parasitism, inflammatory bowel and dietary intolerance are all possible. 24-hour NPO, GI protectants, antiparasitic protocol, fecal test and hydrolyzed diet are all warranted. Otherwise, full thickness intestinal biopsies are warranted. Recheck sonogram in 3-4 weeks to assess the splenic nodule and presentation, as well as the GI tract to ensure an emerging neoplastic event is not occurring in either organ system. However, the splenic lesion is likely benign. The splenic presentation is likely benign, and the GI presentation does not have neoplastic criteria.

## WEIGHT

10.2 kg

## INTERPRETED BY

Eric Lindquist, DMV  
DABVP, Cert. IVUSS

## IMAGING PERFORMED BY

Carver

## HOSPITAL NAME

Animal Emergency  
Hospital Volusia

## REFERRING VET

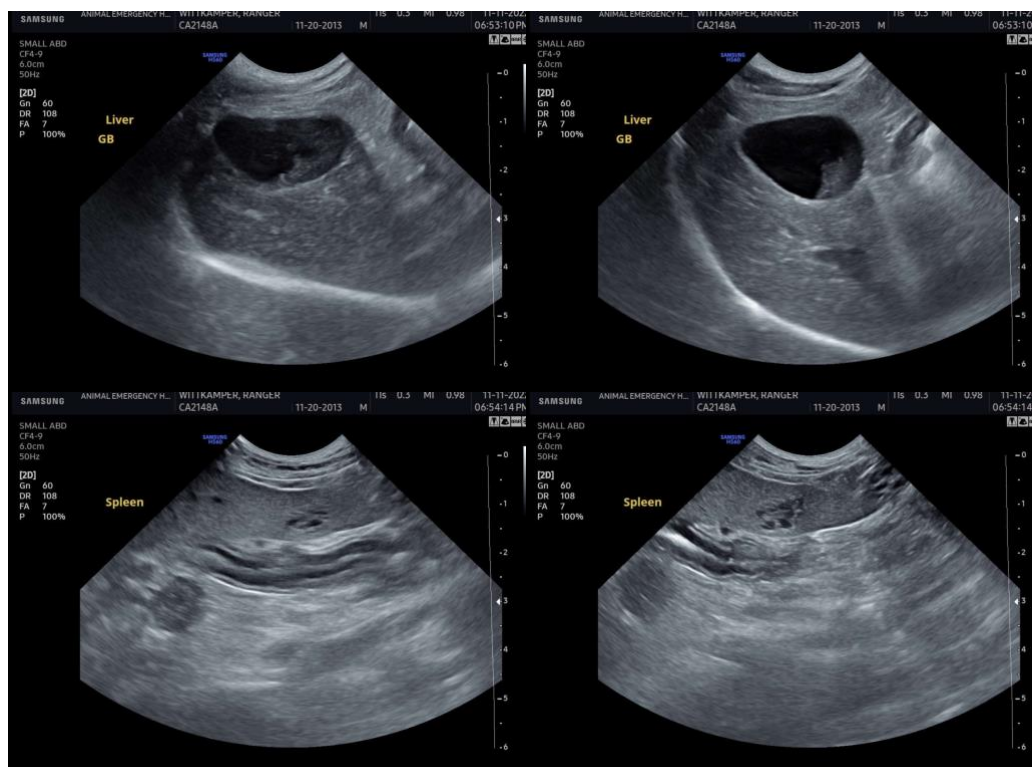
Carver

## INVOICE

17934

## DATE

11/11/22





**PATIENT**

Ranger Wittkamper

**SPECIES**

Canine

**BREED**

Wire Fox Terrier

**SEX**

Neutered Male

**AGE**

8.5 Years

**WEIGHT**

10.2 kg

**INTERPRETED BY**

Eric Lindquist, DMV  
DABVP, Cert. IVUSS

**IMAGING PERFORMED BY**

Carver

**HOSPITAL NAME**

Animal Emergency  
Hospital Volusia

**REFERRING VET**

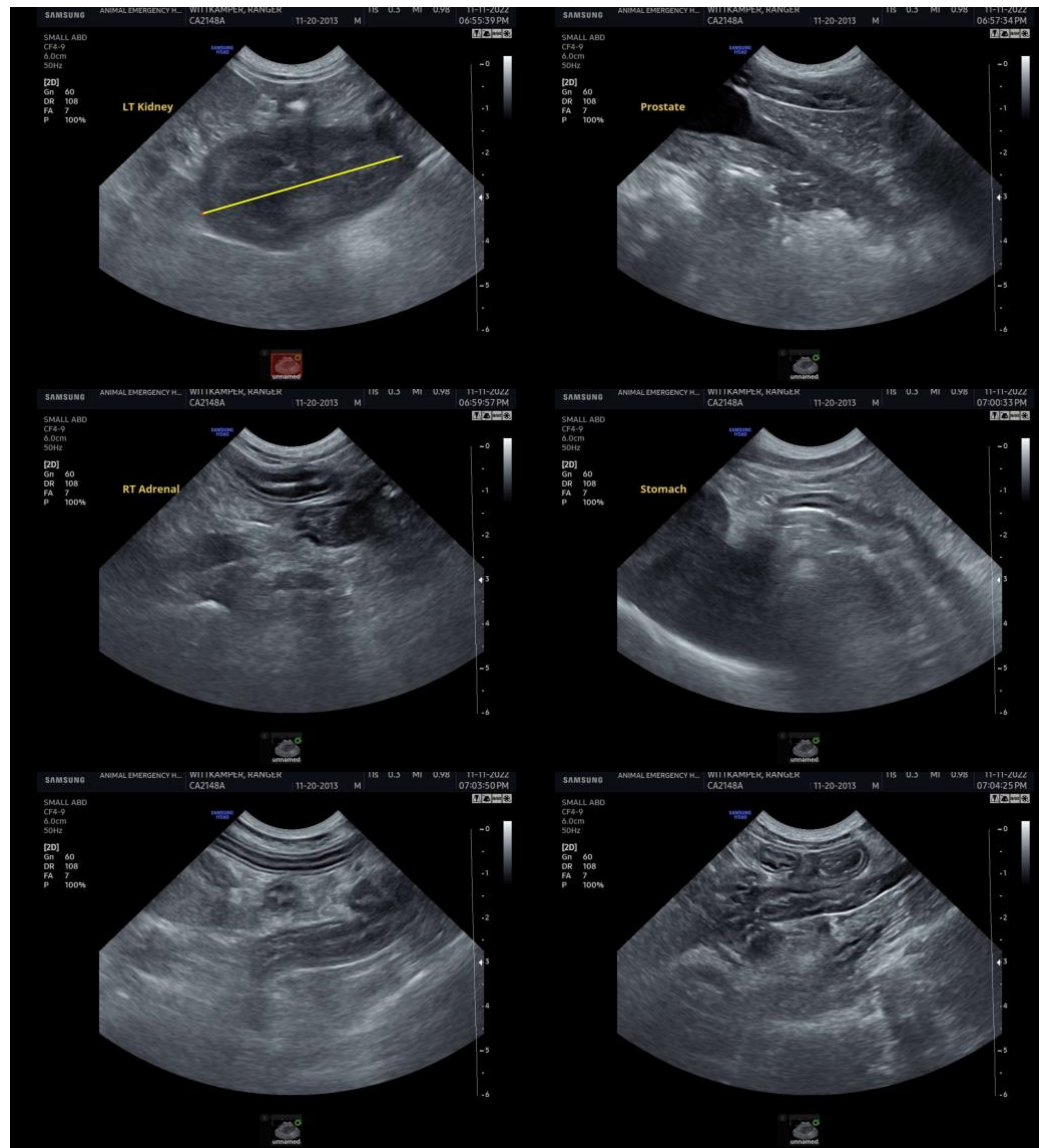
Carver

**INVOICE**

17934

**DATE**

11/11/22



The information and recommendations provided are based on the images presented by the referring veterinarian. No evaluation can be communicated regarding pathology that was not visible in the image/video clips provided.

Thank you for this referral. If the clinical or image interpretation does not parallel your findings or if I can be of any further assistance please contact me.

**Eric Lindquist**, DMV, DABVP, Cert. IVUSS, CEO of SonoPath.com  
info@SonoPath.com