



PATIENT

Pebbles Hodgkiss

SPECIES

Canine

BREED

Mixed

SEX

Spayed Female

AGE

12 Years

WEIGHT

67 Pounds

INTERPRETED BY

Eric Lindquist, DMV

DABVP, Cert. IVUSS

IMAGING PERFORMED BY

Dr. Rodriguez

HOSPITAL NAME

Animal Health VC

REFERRING VET

Dr. Rodriguez

INVOICE

42763

DATE

11/11/22

PRESENTING CLINICAL SIGNS

STRANGURIA, POLLAKURIA AND INCONTINENCE ONLY PARTIALLY RESPONSIVE TO ANTIBIOTICS. I COLLECTED URINE FOR A BRAF AT ANTECH AND A VOIDED URINE CULTURE AND SENSITIVITY. STILL BAR AND GOOD APPETITE. I SENT HOME ANOTHER ROUND OF AMOXI-CLAV PER RELIEF VET AND IT HELPS PEBBLES 75% AND ALSO RIMADYL 50 MG BID AND GABAPENTIN 300 MG AT NIGHT. I AM CONCERNED ABOUT SUSPECT EMERGING MASS AT DORSAL TRIGONE AREA OF BLADDER. MY Abnormal PE/Chem/CBC/UA Results: SEE PREVIOUS REPORT. BRAF PENDING

LIMITED ULTRASONOGRAPHIC EXAMINATION

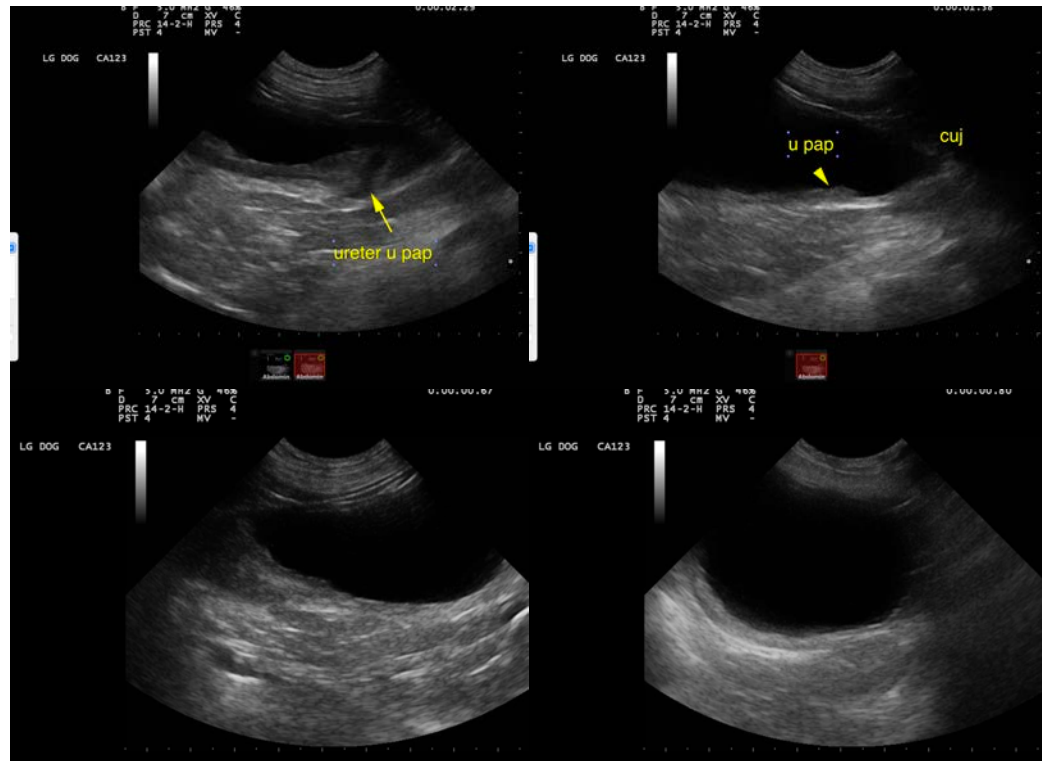
The urinary bladder presented mild repletion. Slight echogenic mucosal changes noted in the apex of the bladder yet no evident masses present. The cystourethral junction was unremarkable. The ureteral papilla was prominent, yet no evident masses present. The area of the ureteral papilla should be monitored for any progression, yet this type of presentation occurs often when patients have a history of moving calculi.

ULTRASONOGRAPHIC FINDINGS

- Mildly thickened ureteral papilla yet no masses present.

INTERPRETATION OF THE FINDINGS & FURTHER RECOMMENDATIONS

I cannot rule out deep pelvic urethral pathology. However, no obvious masses present. Recheck sonogram in 3-5 weeks. If the lower urinary tract signs are persistent, then cystoscopy would be ideal in this patient with mucosal biopsies.





PATIENT

Pebbles Hodgkiss

The information and recommendations provided are based on the images presented by the referring veterinarian/sonographer. No evaluation can be communicated regarding pathology that was not visible in the image/video clips provided.

SPECIES

Canine

Thank you for this referral. If the clinical or image interpretation does not parallel your findings or if I can be of any further assistance please contact me.

Eric Lindquist, DMV, DABVP, Cert. IVUSS, CEO of SonoPath.com

info@SonoPath.com

BREED

Mixed

SEX

Spayed Female

AGE

12 Years

WEIGHT

67 Pounds

INTERPRETED BY

Eric Lindquist, DMV

DABVP, Cert. IVUSS

IMAGING PERFORMED BY

Dr. Rodriguez

HOSPITAL NAME

Animal Health VC

REFERRING VET

Dr. Rodriguez

INVOICE

42763

DATE

11/11/22