



PATIENT

Pebbles Caldwell

SPECIES

Canine

BREED

French Bulldog

SEX

Spayed Female

AGE

3 Years

WEIGHT

21.7 Pounds

INTERPRETED BY

Eric Lindquist, DMV
DABVP, Cert. IVUSS

IMAGING PERFORMED BY

Shari Reffi, CVT

HOSPITAL NAME

Newton VH

REFERRING VET

Dr. Kim

INVOICE

17939

DATE

11/11/22

PRESENTING CLINICAL SIGNS

History: Got into bean bag chair-was lethargic, shaking, anorexic. Regional loss of peritoneal serosal detail on rads. CPL normal. Current meds: IVF

Abnormal PE/Chem/CBC/UA Results: ALT 137 (120H); K 3.7 (3.8L)

ULTRASONOGRAPHIC EXAMINATION OF THE ABDOMEN

Urinary System

The **urinary bladder**, trigone, and pelvic urethra presented normal thicknesses and normal tone. The ureters were not visible which is normal. No uroliths or sediment were visualized, and anechoic urine was present. No evidence of inflammatory or neoplastic changes were noted. Ureteral papillae were normal. The pelvic urethra was imaged 2.0 cm beyond the cystourethral junction.

The **kidneys** revealed normal size and structure, corticomedullary definition and ratio for this age. The cortices presented largely uniform texture with normal echogenic relationship to liver and spleen. Medullary structure differed distinctly from the cortex and no evidence of pelvic dilation was present. The capsules were acceptably uniform without significant irregularities. The right kidney measured 4.77 cm. The left kidney measured 4.77 cm.

Adrenal Glands

Both **adrenal glands** were visualized and recognized as having normal shape, size, position and echogenicity for this breed. The phrenic vasculature, glandular echogenicity and detail were unremarkable. Capsule, cortex, and medullary definition were normal for this age patient. The left adrenal gland measured 1.58 cm x 0.35 cm at the cranial pole and 0.61 cm at the caudal pole. The right adrenal gland measured 2.0 cm x 0.75 cm at the cranial pole and 0.75 cm at the caudal pole.

Spleen

The **spleen** presented a smooth homogeneous parenchyma hyperechoic to liver and renal cortical parenchyma. The capsule was smooth without noticeable expansion or deviation from within the spleen or adjacent pathology. The splenic vasculature demonstrated normal volume without signs of congestion or thrombosis. No sonographic evidence of acute or chronic inflammatory, neoplastic, or infarctual changes were noted. The spleen measured 1.3 cm.

Liver

The **liver** images submitted revealed subjectively normal liver size, contour, and structure. Parenchymal echogenicity was naturally coarse and hypoechoic to the spleen. Vascular and biliary tracts were of normal volume with no evidence of congestion. The gallbladder presented acceptably thin walls with primarily anechoic content. The cystic and common bile ducts were normal. No pathological hepatic lymphadenopathy was evident. No overt structural evidence of inflammatory, infiltrative or regenerative pathology was evident.

Gastrointestinal

The upper **gastrointestinal tract** in this patient revealed minor, edematous wall. A mild amount of mucosal remodeling was noted, as well as mucosal striations in the small intestine. There was no evidence of foreign bodies. Minor areas of fluctuant fluid accumulation were noted within the lumen with hyperperistalsis. This pattern continued to the ileocecal valve. The colon revealed a fluid filled



PATIENT

Pebbles Caldwell

lumen. This presentation is most consistent with gastrointestinal irritation/inflammation without obstruction.

SPECIES

Canine

Pancreas

The base and limbs of the **pancreas** were observed to be largely isoechoic to surrounding omental fat. Pancreatic duct and capsular contour were acceptably normal and parenchyma respected normal curvilinear patterns. No overt evidence of active inflammatory or neoplastic disease was noted.

BREED

French Bulldog

ULTRASONOGRAPHIC FINDINGS

- Gastroenteritis pattern

SEX

Spayed Female

INTERPRETATION OF THE FINDINGS & FURTHER RECOMMENDATIONS

Dietary indiscretion, food intolerance, structurally insignificant inflammatory bowel or occult parasitism and occult Addison's are all potentials. GI protectant protocol warranted. I recommend a fresh fecal smear and fecal floatation analysis. Antiparasitic protocol is indicated. Potential diet change to hydrolyzed diet may be appropriate.

AGE

3 Years

WEIGHT

21.7 Pounds

INTERPRETED BY

Eric Lindquist, DMV
DABVP, Cert. IVUSS

IMAGING PERFORMED BY

Shari Reffi, CVT

HOSPITAL NAME

Newton VH

REFERRING VET

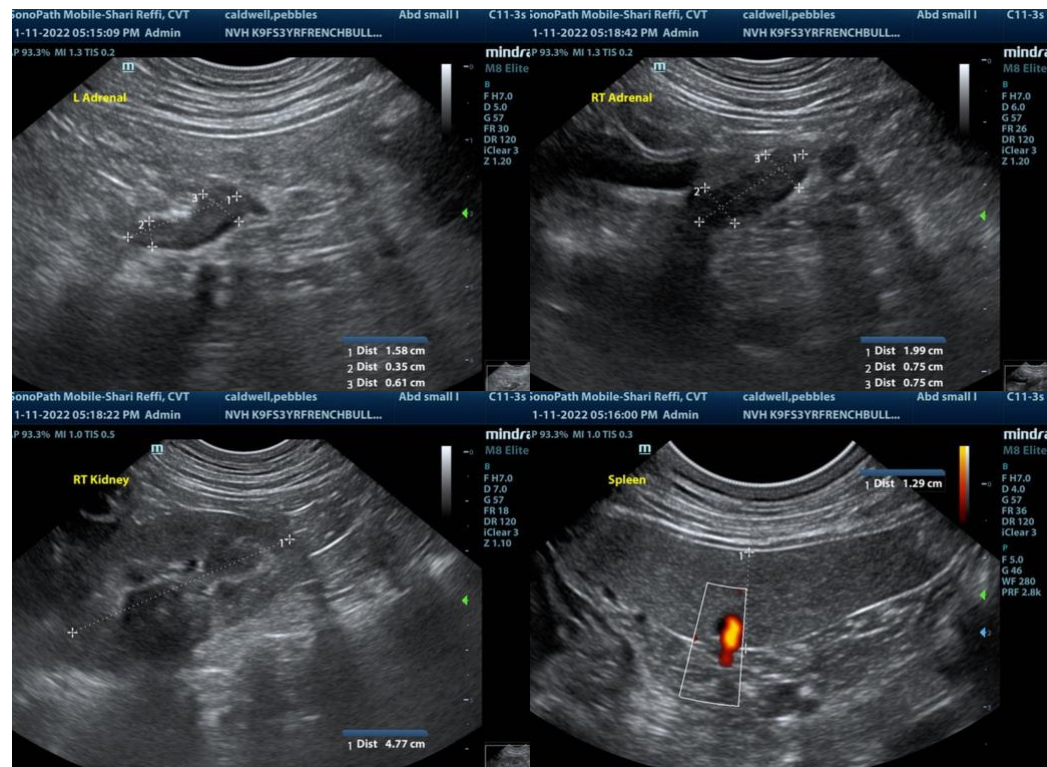
Dr. Kim

INVOICE

17939

DATE

11/11/22





PATIENT

Pebbles Caldwell

SPECIES

Canine

BREED

French Bulldog

SEX

Spayed Female

AGE

3 Years

WEIGHT

21.7 Pounds

INTERPRETED BY

Eric Lindquist, DMV
DABVP, Cert. IVUSS

IMAGING PERFORMED BY

Shari Reffi, CVT

HOSPITAL NAME

Newton VH

REFERRING VET

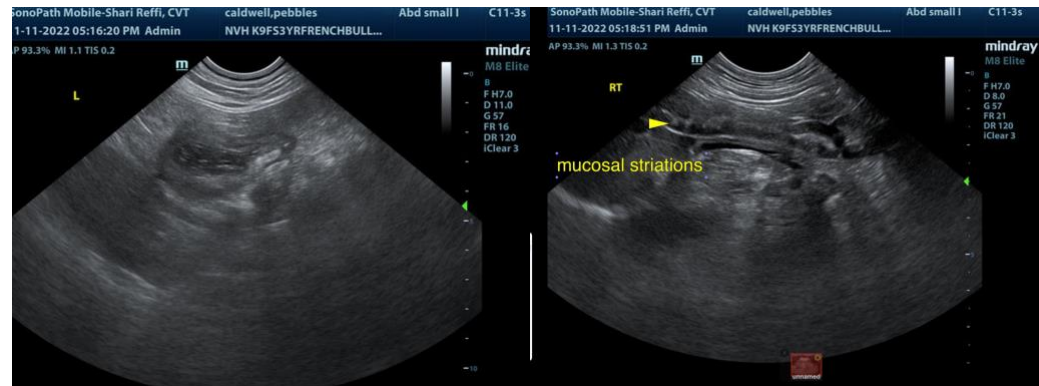Dr. Kim

INVOICE

17939

DATE

11/11/22



The information and recommendations provided are based on the images presented by the referring veterinarian. No evaluation can be communicated regarding pathology that was not visible in the image/video clips provided.

Thank you for this referral. If the clinical or image interpretation does not parallel your findings or if I can be of any further assistance please contact me.

Eric Lindquist, DMV, DABVP, Cert. IVUSS, CEO of SonoPath.com
info@SonoPath.com