



PATIENT

Pesto Hughes

SPECIES

Feline

BREED

Domestic Shorthair

SEX

Spayed female

AGE

13 years

WEIGHT

18.5 lbs

INTERPRETED BY

Eric Lindquist, DMV
DABVP, Cert. IVUSS

IMAGING PERFORMED BY

Dr. Gabriel

HOSPITAL NAME

Central Jersey AH

REFERRING VET

Dr. Gabriel

INVOICE

68535

DATE

11/10/25

PRESENTING CLINICAL SIGNS

History: acting off sometimes history of DM take vetsuline 4 IU SQ BID drinking more than usual
Abnormal PE/Chem/CBC/UA Results: CBC/CHEM /t4 ref lab pending

ULTRASONOGRAPHIC EXAMINATION OF THE ABDOMEN

Urinary System

The **urinary bladder**, trigone, and pelvic urethra presented normal thicknesses and normal tone. The pelvic urethra was imaged 2.0 cm beyond the cystourethral junction and appeared normal. The ureters were not visible which is normal. No uroliths or sediment were visualized and anechoic urine was present. No evidence of inflammatory or neoplastic changes was noted. Ureteral papillae were normal.

The **kidneys** revealed largely normal size and structure, corticomedullary definition and ratio (cortex 1/3 of medulla) were essentially maintained with some age-related loss of curvilinear patterns regarding the capsule and C/M junction. The cortices presented largely uniform texture with some increased echogenicity expected for this age patient. Medullary structure differed distinctly from that of the cortex. The left kidney measured 4.2 cm with slight pyelectasia. The right kidney measured 5.0 cm.

Adrenal Glands

Both **adrenal glands** were visualized and recognized as having normal shape, size, position and echogenicity for this breed. The phrenic vasculature, glandular echogenicity and detail were unremarkable. Capsule, cortex, and medullary definition were normal for this age patient.

Spleen

The **spleen** presented a smooth homogeneous parenchyma hyperechoic to liver and renal cortical parenchyma. The capsule was smooth without noticeable expansion or deviation from within the spleen or adjacent pathology. The splenic vasculature demonstrated normal volume without signs of congestion or thrombosis. No sonographic evidence of acute or chronic inflammatory, neoplastic, or infarctual changes was noted.

Liver

The **liver** images from right and left intercostal as well as subcostal views revealed subjectively normal liver size, contour, and structure. Some age-related parenchymal remodeling was noted but likely not clinically significant at this time. Vascular and biliary tracts were of normal volume and no evidence of congestion was noted. The gallbladder presented some dependent debris with essentially normal contour. The cystic and common bile ducts were normal. No overt evidence of active inflammatory, infiltrative or regenerative pathology was noted but should be paired with current or past LE elevations regarding any clinical significance to this presentation. The hepatic lymph nodes were unremarkable.



PATIENT

Pesto Hughes

SPECIES

Feline

BREED

Domestic Shorthair

SEX

Spayed female

AGE

13 years

WEIGHT

18.5 lbs

INTERPRETED BY

Eric Lindquist, DMV
DABVP, Cert. IVUSS

IMAGING PERFORMED BY

Dr. Gabriel

HOSPITAL NAME

Central Jersey AH

REFERRING VET

Dr. Gabriel

INVOICE

68535

DATE

11/10/25

Gastrointestinal

Examination of the **gastrointestinal tract** revealed a stomach and intestine free of stasis, of normal wall thickness, acceptable curvilinear mural detail, and peristaltic activity. Small and large intestine demonstrated normal luminal chyme and stool consistency respectively. No obstructive or overt infiltrative disease was noted. No associated abnormal lymphatic activity was noted.

Pancreas

The base and limbs of the **pancreas** were observed to be largely isoechoic to surrounding omental fat. Pancreatic duct and capsular contour were acceptably normal and parenchyma respected normal curvilinear patterns. No overt evidence of active inflammatory or neoplastic disease was noted.

ULTRASONOGRAPHIC FINDINGS

- Age related renal changes with slight pyelectasia.

INTERPRETATION OF THE FINDINGS & FURTHER RECOMMENDATIONS

There was no other evidence of significant disease.

Potential Causes of Diabetic Dysregulation

This is a suggestive checkoff list when faced with an unregulated diabetic patient:

UTI

Dietary indiscretion/intolerance

Pancreatitis

Hyperthyroidism/hypothyroidism

Exogenous steroids (including topical eye meds)

Cushing's

Acromegaly

Owner compliance

Insulin quality issues

Antibodies to insulin

Underlying Neoplasia

Diffuse liver disease



PATIENT

Pesto Hughes

SPECIES

Feline

BREED

Domestic Shorthair

SEX

Spayed female

AGE

13 years

WEIGHT

18.5 lbs

INTERPRETED BY

Eric Lindquist, DMV
DABVP, Cert. IVUSS

IMAGING PERFORMED BY

Dr. Gabriel

HOSPITAL NAME

Central Jersey AH

REFERRING VET

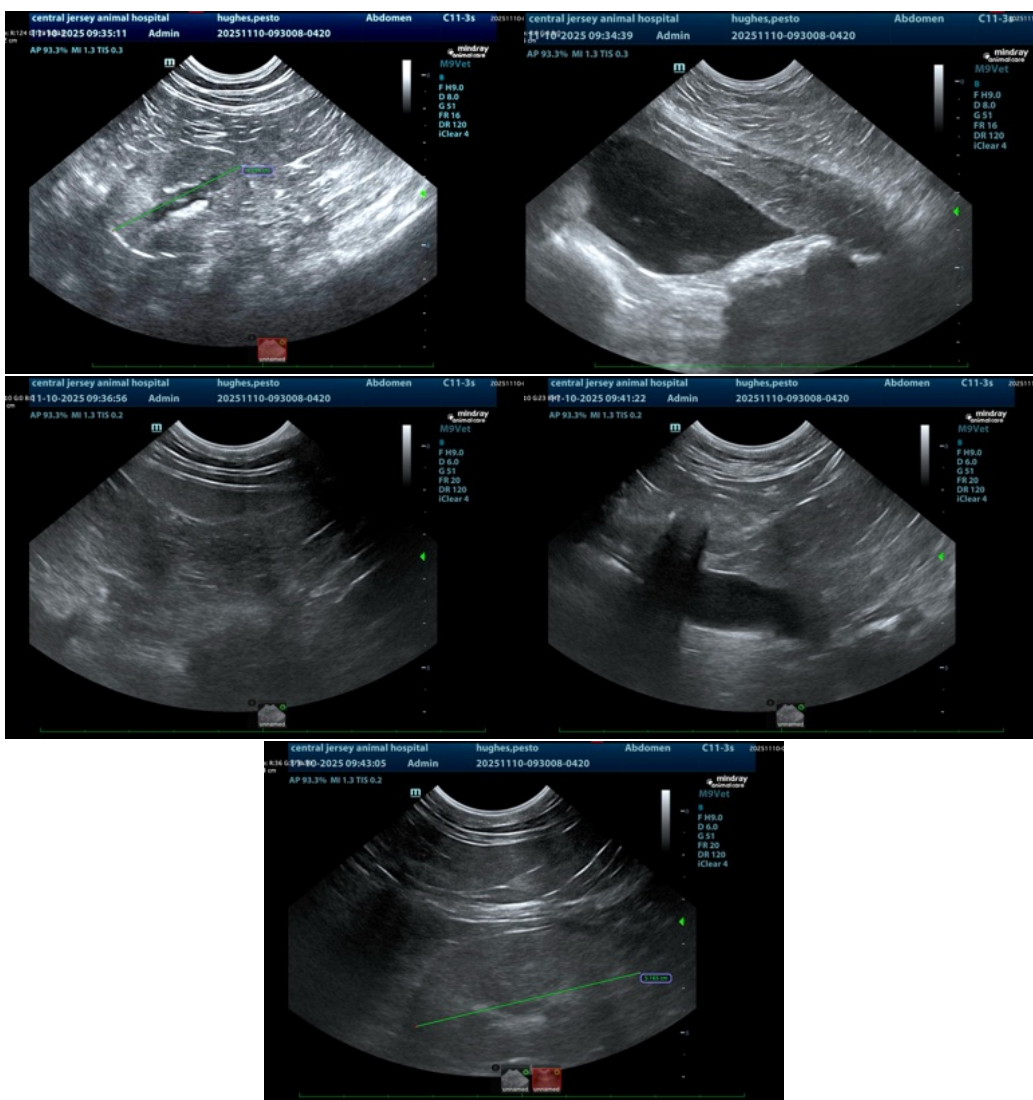
Dr. Gabriel

INVOICE

68535

DATE

11/10/25



The information and recommendations provided are based on the images presented by the referring veterinarian/sonographer. No evaluation can be communicated regarding pathology that was not visible in the image/video clips provided.

Thank you for this referral. If the clinical or image interpretation does not parallel your findings or if I can be of any further assistance please contact me.

Eric Lindquist, DMV, DABVP (CFM), Cert. IVUSS, CEO of SonoPath.com

info@SonoPath.com