



PATIENT

Chunky Yamartino

SPECIES

Canine

BREED

Staffordshire Mix

SEX

Neutered male

AGE

8 years

WEIGHT

61 lbs

INTERPRETED BY

Eric Lindquist, DMV
DABVP, Cert. IVUSS

IMAGING PERFORMED BY

Dr. Copp

HOSPITAL NAME

Westside AH

REFERRING VET

Dr. Copp

INVOICE

68512

DATE

11/10/25

PRESENTING CLINICAL SIGNS

History: Hx chronic bilious vomiting, softer stools. Owner found diet of white rice, bison and veggies and has done well on that but still gets intermittent GI upset. Has history of MCT (grade 2) on 2 occasions with mass removals showing good margins.

Abnormal PE/Chem/CBC/UA Results: PE: NSF, mild tartar, NSR, NMA, PSS, eupneic, lungs clear. Normal LN. CBC- WNL Chem- WNL

ULTRASONOGRAPHIC EXAMINATION OF THE ABDOMEN

Urinary System

The **urinary bladder**, trigone, and pelvic urethra presented normal thicknesses and normal tone. The pelvic urethra was imaged 1.0 cm beyond the cystourethral junction and appeared normal. The ureters were not visible which is normal. No uroliths or sediment were visualized and anechoic urine was present. No evidence of inflammatory or neoplastic changes was noted. Ureteral papillae were normal.

The **kidneys** revealed normal size and structure, corticomedullary definition and ratio for this age. The cortices presented largely uniform texture with normal echogenic relationship to liver and spleen. Medullary structure differed distinctly from the cortex and no evidence of pelvic dilation was present. The capsules were acceptably uniform without significant irregularities.

Adrenal Glands

Both **adrenal glands** were visualized and recognized as having normal shape, size, position and echogenicity for this breed. The phrenic vasculature, glandular echogenicity and detail were unremarkable. Capsule, cortex, and medullary definition were normal for this age patient. The left adrenal gland measured 0.6 cm. The right adrenal gland measured 0.8 cm at the cranial pole and 0.5 cm at the caudal pole.

Spleen

The **spleen** presented a smooth homogeneous parenchyma hyperechoic to liver and renal cortical parenchyma. The capsule was smooth without noticeable expansion or deviation from within the spleen or adjacent pathology. The splenic vasculature demonstrated normal volume without signs of congestion or thrombosis. No sonographic evidence of acute or chronic inflammatory, neoplastic, or infarctual changes was noted.

Liver

The **liver** images submitted revealed subjectively normal liver size, contour, and structure. Parenchymal echogenicity was naturally coarse and hypoechoic to the spleen. Vascular and biliary tracts were of normal volume with no evidence of congestion. The gallbladder presented acceptably thin walls with primarily anechoic content. The cystic and common bile ducts were normal. No pathological hepatic



PATIENT

Chunky Yamartino

lymphadenopathy was evident. No overt structural evidence of inflammatory, infiltrative or regenerative pathology was evident.

SPECIES

Canine

Gastrointestinal

The **pylorus** was mildly thickened without loss of mural detail. However, the muscularis hypertrophy was evident. The muscularis measured 1.0 cm with wall thickness of 1.7 cm. The small intestines and colon were unremarkable with normal curvilinear mural patterns and content.

BREED

Staffordshire Mix

SEX

Neutered male

Pancreas

The base and limbs of the **pancreas** were observed to be largely isoechoic to surrounding omental fat. Pancreatic duct and capsular contour were acceptably normal and parenchyma respected normal curvilinear patterns. No overt evidence of active inflammatory or neoplastic disease was noted.

AGE

8 years

ULTRASONOGRAPHIC FINDINGS

- Mildly thickened pylorus.

WEIGHT

61 lbs

INTERPRETED BY

Eric Lindquist, DMV
DABVP, Cert. IVUSS

INTERPRETATION OF THE FINDINGS & FURTHER RECOMMENDATIONS

Endoscopy would be ideal in this patient. Canned b.i.d. feedings are recommended. A clinical trial of the following may have proven effective. Recheck sonogram would be ideal in 4 weeks.

IMAGING PERFORMED BY

Dr. Copp

Helicobacter/Gastritis protocol

HOSPITAL NAME

Westside AH

A clinical trial of **Zithromax (Dogs: 5-10 mg/kg p.o. q24h. May increase dosing interval to q48h after 3-5 days of treatment)**, **Metronidazole (10-20 mg/kg p.o. b.i.d.)**, **Pepcid (0.5-1 mg/kg s.i.d.)** and **Sucralfate (0.5-2 g/dog PO)** or **Omeprazole (1 mg/kg p.o. s.i.d.)** over the next 3 weeks along with a **novel-protein or hydrolyzed diet** with slurry feeding b.i.d./t.i.d. over the next 2-4 days and then increase to canned diet bid. Dry food should be avoided over the next 4 weeks. A recheck sonogram to assess GI improvement or progression would be ideal in 4 weeks.

REFERRING VET

Dr. Copp

INVOICE

68512

DATE

11/10/25



PATIENT

Chunky Yamartino

SPECIES

Canine

BREED

Staffordshire Mix

SEX

Neutered male

AGE

8 years

WEIGHT

61 lbs

INTERPRETED BY

Eric Lindquist, DMV
DABVP, Cert. IVUSS

IMAGING PERFORMED BY

Dr. Copp

HOSPITAL NAME

Westside AH

REFERRING VET

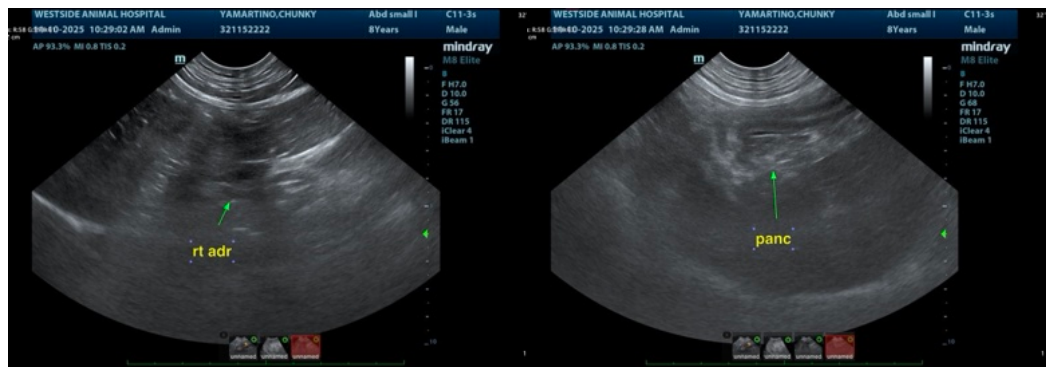
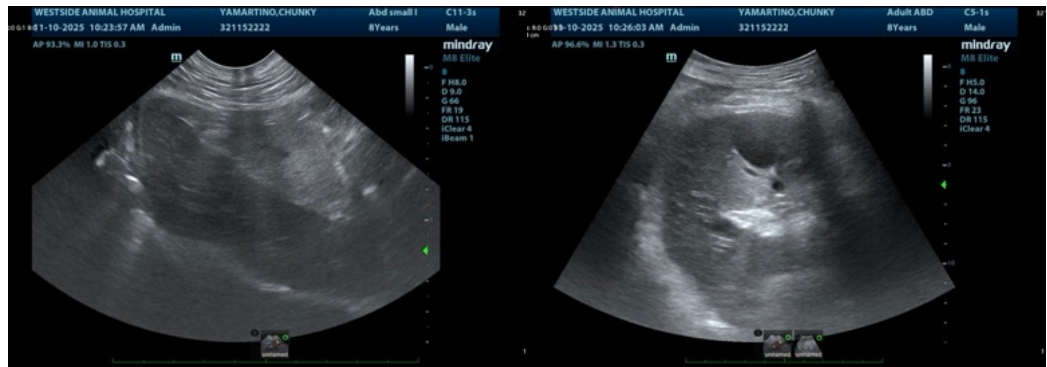
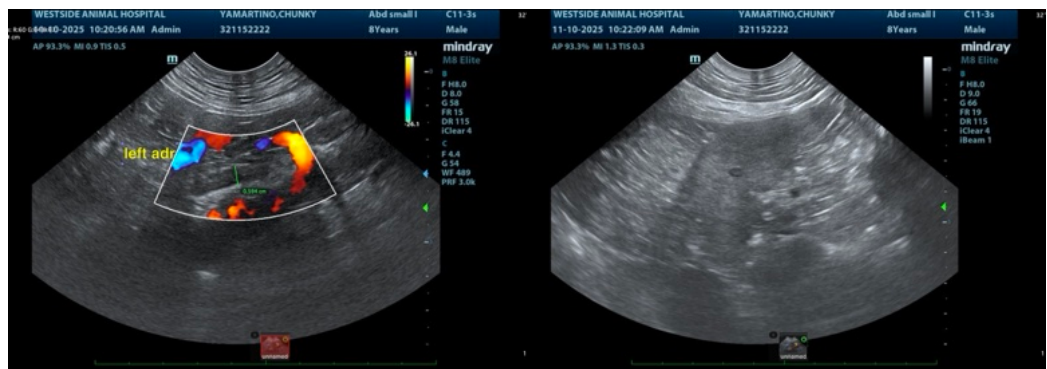
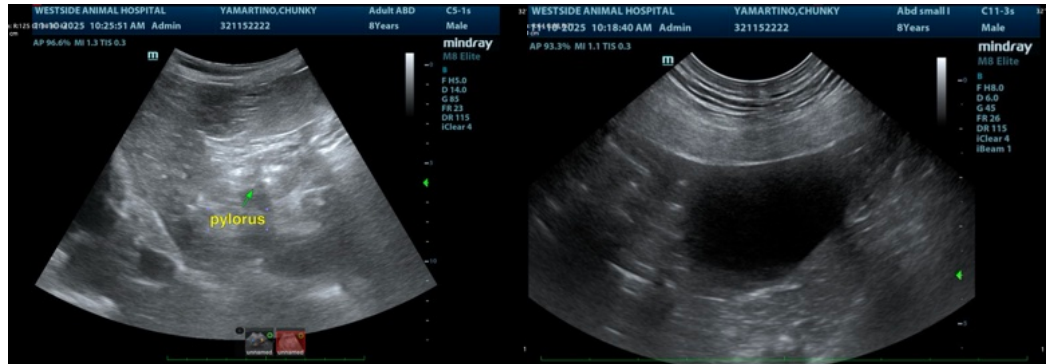
Dr. Copp

INVOICE

68512

DATE

11/10/25





PATIENT

Chunky Yamartino

SPECIES

Canine

BREED

Staffordshire Mix

SEX

Neutered male

AGE

8 years

WEIGHT

61 lbs

INTERPRETED BY

Eric Lindquist, DMV
DABVP, Cert. IVUSS

IMAGING PERFORMED BY

Dr. Copp

HOSPITAL NAME

Westside AH

REFERRING VET

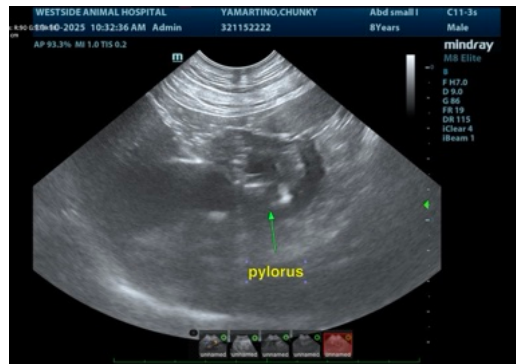
Dr. Copp

INVOICE

68512

DATE

11/10/25



The information and recommendations provided are based on the images presented by the referring veterinarian/sonographer. No evaluation can be communicated regarding pathology that was not visible in the image/video clips provided.

Thank you for this referral. If the clinical or image interpretation does not parallel your findings or if I can be of any further assistance please contact me.

Eric Lindquist, DMV, DABVP (CFM), Cert. IVUSS, CEO of SonoPath.com

info@SonoPath.com