



**PATIENT PRESENTING CLINICAL SIGNS**

**Bear Guzik** stacking of intestines- acute projectile vomiting. Patient does eat fabric. R/O FB vs gastroenteritis, ulcer, reflux

**SPECIES** Abnormal PE/Chem/CBC/UA Results: HCT 66% hemoconcentrated; BUN 29, CPL normal

Canine

**ULTRASONOGRAPHIC EXAMINATION OF THE ABDOMEN**

**BREED** *Urinary System*

**French Bulldog** The **urinary bladder**, trigone, and pelvic urethra presented normal thicknesses and normal tone. The ureters were not visible which is normal. No uroliths or sediment were visualized and anechoic urine was present. No evidence of inflammatory or neoplastic changes were noted. Ureteral papillae were normal. The pelvic urethra was imaged 3.0 cm beyond the cystourethral junction.

**SEX**

**Neutered Male** The residual prostate measured 6.0 mm.

**AGE**

3 Years

The **kidneys** revealed normal size and structure, corticomedullary definition and ratio for this age. The cortices presented largely uniform texture with normal echogenic relationship to liver and spleen. Medullary structure differed distinctly from the cortex and no evidence of pelvic dilation was present. The capsules were acceptably uniform without significant irregularities. The right kidney measured 4.57 cm. The left kidney measured 4.45 cm.

**WEIGHT**

28 Pounds

**Adrenal Glands**

Both **adrenal glands** were visualized and recognized as having normal shape, size, position and echogenicity for this breed. The phrenic vasculature, glandular echogenicity and detail were unremarkable. Capsule, cortex, and medullary definition were normal for this age patient. The left adrenal gland measured 2.09 cm x 0.43 cm at the caudal pole and 0.40 cm at the cranial pole. The right adrenal gland measured 2.06 cm x 0.78 cm at the cranial pole and 0.45 cm at the caudal pole.

**INTERPRETED BY**

Eric Lindquist, DMV

DABVP, Cert. IVUSS

**Spleen**

The **spleen** presented a smooth homogeneous parenchyma hyperechoic to liver and renal cortical parenchyma. The capsule was smooth without noticeable expansion or deviation from within the spleen or adjacent pathology. The splenic vasculature demonstrated normal volume without signs of congestion or thrombosis. No sonographic evidence of acute or chronic inflammatory, neoplastic, or infarctual changes were noted.

**IMAGING PERFORMED BY**

Diane McFadden

**HOSPITAL NAME**

Rockaway AH

**Liver**

The **liver** images submitted revealed subjectively normal liver size, contour, and structure. Parenchymal echogenicity was naturally coarse and hypoechoic to the spleen. Vascular and biliary tracts were of normal volume with no evidence of congestion. The gallbladder presented acceptably thin walls with primarily anechoic content. The cystic and common bile ducts were normal. No pathological hepatic lymphadenopathy was evident. No overt structural evidence of inflammatory, infiltrative or regenerative pathology was evident.

**REFERRING VET**

Dr. Ascot

**INVOICE**

42691

**Gastrointestinal**

The stomach revealed a moderate amount of fluid with floating echogenic linear structure, yet non-obstructive. This may represent a worm burden. The small intestine and colon were unremarkable. No evidence of foreign bodies. The pylorus was patent.

**DATE**

11/10/22



**PATIENT**

Bear Guzik

**Pancreas**

**SPECIES**

Canine

The base and limbs of the **pancreas** were observed to be largely isoechoic to surrounding omental fat. Pancreatic duct and capsular contour were acceptably normal and parenchyma respected normal curvilinear patterns. No overt evidence of active inflammatory or neoplastic disease was noted.

**BREED**

French Bulldog

**ULTRASONOGRAPHIC FINDINGS**

- Gastritis pattern with potential worm burden

**SEX**

Neutered Male

**INTERPRETATION OF THE FINDINGS & FURTHER RECOMMENDATIONS**

Fecal test, antiparasitic protocol, GI protectants, IV fluid support, and medical therapy should prove effective.

**AGE**

3 Years

**WEIGHT**

28 Pounds

**INTERPRETED BY**

Eric Lindquist, DMV

DABVP, Cert. IVUSS

**IMAGING PERFORMED BY**

Diane McFadden

**HOSPITAL NAME**

Rockaway AH

**REFERRING VET**

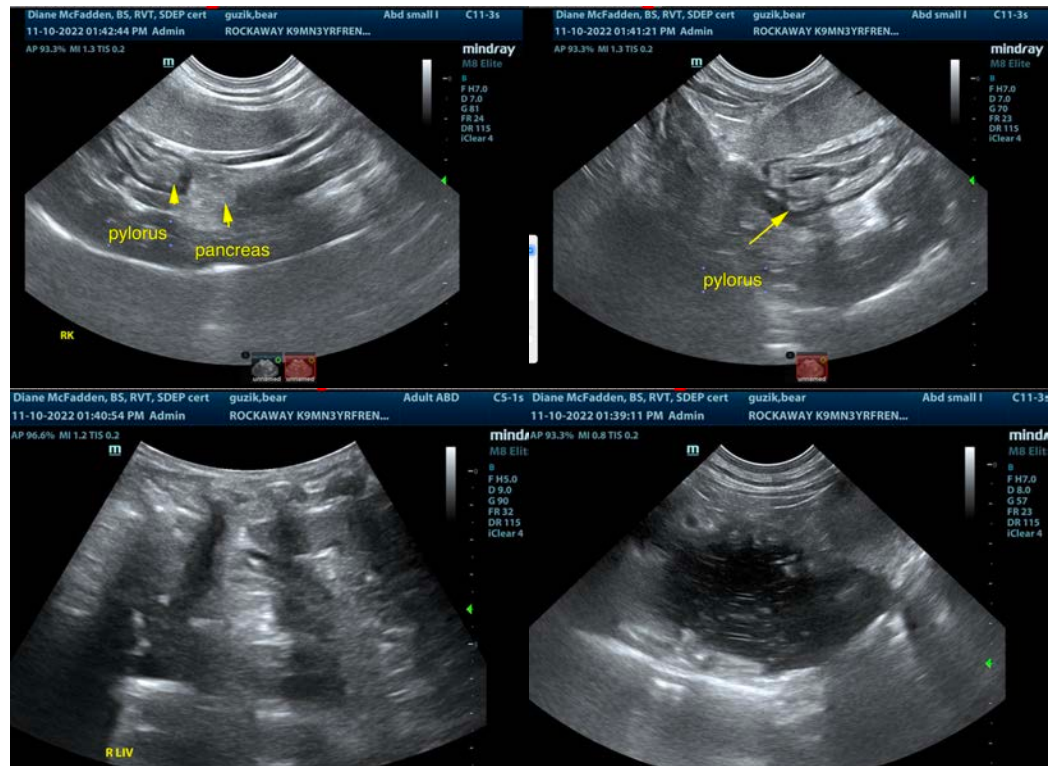
Dr. Ascot

**INVOICE**

42691

**DATE**

11/10/22





**PATIENT**

Bear Guzik

**SPECIES**

Canine

**BREED**

French Bulldog

**SEX**

Neutered Male

**AGE**

3 Years

**WEIGHT**

28 Pounds

**INTERPRETED BY**

Eric Lindquist, DMV  
DABVP, Cert. IVUSS

**IMAGING PERFORMED BY**

Diane McFadden

**HOSPITAL NAME**

Rockaway AH

**REFERRING VET**

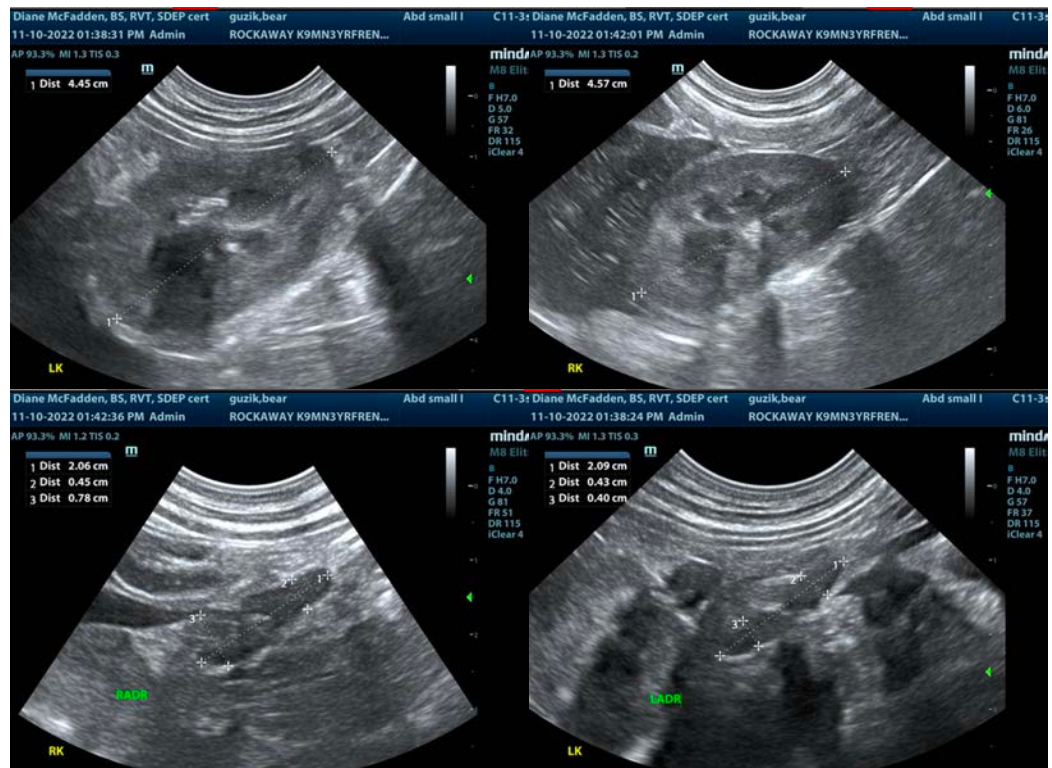
Dr. Ascot

**INVOICE**

42691

**DATE**

11/10/22



The information and recommendations provided are based on the images presented by the referring veterinarian/sonographer. No evaluation can be communicated regarding pathology that was not visible in the image/video clips provided.

Thank you for this referral. If the clinical or image interpretation does not parallel your findings or if I can be of any further assistance please contact me.

Eric Lindquist, DMV, DABVP, Cert. IVUSS, CEO of SonoPath.com

[info@SonoPath.com](mailto:info@SonoPath.com)