



PATIENT

Dolly Matich Howard

SPECIES

Canine

BREED

Chihuahua

SEX

Spayed female

AGE

7 years

WEIGHT

16 lbs

INTERPRETED BY

Eric Lindquist, DMV
DABVP, Cert. IVUSS

IMAGING PERFORMED BY

Amy Mayhew LVT

HOSPITAL NAME

SVS Imaging Michigan

REFERRING VET

Waterford AC

INVOICE

42266

DATE

11/1/22

PRESENTING CLINICAL SIGNS

History: Swelling from shoulder down to elbow and around leg. Patient was limping and unable to bend leg. Improved on medications. Returned and was started on Pred and Baytril. Previous history of MCT.
Abnormal PE/Chem/CBC/UA Results: Labs normal except platelets slightly high.

ULTRASONOGRAPHIC EXAMINATION

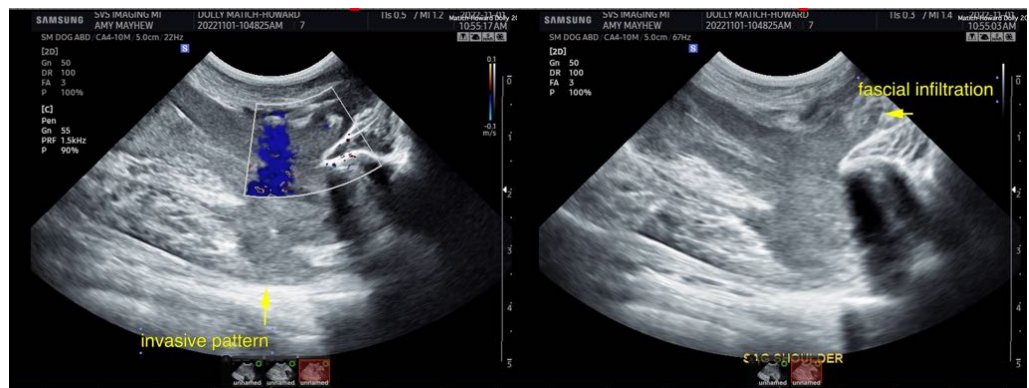
A 4.0 cm hypoechoic mass was noted extending from the subcutaneous tissue to the periosteum of the regional bone. Areas of cystic portions were also noted. There was disruption of regional musculature present. The margins are ill defined. The mass appears to infiltrate into regional fascia. The mass appears to reach the level of the periosteum, but does not invade the bone. Clean resection is unlikely in this patient as the mass has a tentacle type invasive pattern and envelops the regional bone. No evidence of bone lysis noted in the regions imaged.

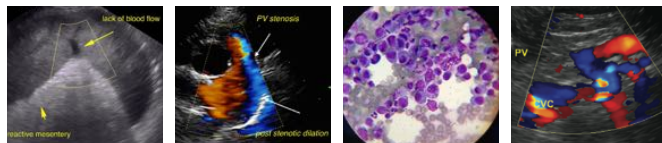
ULTRASONOGRAPHIC FINDINGS

Ill-defined soft tissue mass occupying subcutaneous space and muscle infiltrating into fascia. Appears attached to the regional periosteum.

INTERPRETATION OF THE FINDINGS & FURTHER RECOMMENDATIONS

Ultrasound-guided FNA is indicated. CT evaluation is warranted; however, limb amputation is likely the best option assuming no metastatic disease is noted elsewhere in the body. Chest CT or radiographs to assess for metastatic disease and abdominal sonogram is warranted if not already performed as well as physical inspection of other joints. Mast cell disease or other round cell neoplasia is a strong potential in this case.





PATIENT

Dolly Matich Howard

SPECIES

Canine

BREED

Chihuahua

SEX

Spayed female

AGE

7 years

WEIGHT

16 lbs

INTERPRETED BY

Eric Lindquist, DMV
DABVP, Cert. IVUSS

**IMAGING
PERFORMED BY**

Amy Mayhew LVT

HOSPITAL NAME

SVS Imaging Michigan

REFERRING VET

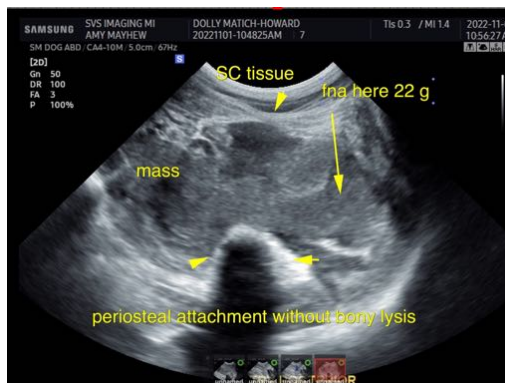
Waterford AC

INVOICE

42266

DATE

11/1/22



The information and recommendations provided are based on the images presented by the referring veterinarian/sonographer. No evaluation can be communicated regarding pathology that was not visible in the image/video clips provided.

Thank you for this referral. If the clinical or image interpretation does not parallel your findings or if I can be of any further assistance please contact me.

Eric Lindquist, DMV, DABVP, Cert. IVUSS, CEO of SonoPath.com
info@SonoPath.com