



PATIENT

Belle Robinson

PRESENTING CLINICAL SIGNS

lethargic, not eating

SPECIES

Canine

ULTRASONOGRAPHIC EXAMINATION OF THE ABDOMEN

Urinary System

The **urinary bladder** presented minor polypoid change or mineralization at the apex of the bladder, not pathological, yet should be monitored.

BREED

Schnauzer

The **kidneys** revealed normal size and structure, corticomedullary definition and ratio for this age. The cortices presented largely uniform texture with normal echogenic relationship to liver and spleen. Medullary structure differed distinctly from the cortex and no evidence of pelvic dilation was present. The capsules were acceptably uniform without significant irregularities. The right kidney measured 5.22 cm. The left kidney measured 4.75 cm.

SEX

Spayed Female

Adrenal Glands

AGE

6 Years

Both **adrenal glands** were visualized and recognized as having normal shape, size, position and echogenicity for this breed. The phrenic vasculature, glandular echogenicity and detail were unremarkable. Capsule, cortex, and medullary definition were normal for this age patient. The left adrenal gland measured 1.31 cm x 0.57 cm at the caudal pole and 0.42 cm at the cranial pole. The right adrenal gland measured 1.96 cm x 0.85 cm at the cranial pole and 0.47 cm at the caudal pole.

WEIGHT

21.5 Pounds

Spleen

The **spleen** presented a smooth homogeneous parenchyma hyperechoic to liver and renal cortical parenchyma. The capsule was smooth without noticeable expansion or deviation from within the spleen or adjacent pathology. The splenic vasculature demonstrated normal volume without signs of congestion or thrombosis. No sonographic evidence of acute or chronic inflammatory, neoplastic, or infarctual changes were noted.

INTERPRETED BY

Eric Lindquist, DMV

DABVP, Cert. IVUSS

Liver

The **liver** images from right and left intercostal as well as subcostal views revealed subjectively normal liver size, contour, and structure. Some age-related parenchymal remodeling was noted but likely not clinically significant at this time. Vascular and biliary tracts were of normal volume and no evidence of congestion was noted. The gallbladder presented some dependent debris with essentially normal contour. The cystic and common bile ducts were normal. No overt evidence of active inflammatory, infiltrative or regenerative pathology was noted but should be paired with current or past LE elevations regarding any clinical significance to this presentation. The hepatic lymph nodes were unremarkable.

HOSPITAL NAME

Rockaway AH

Comet tail lung pattern noted through the diaphragm.

REFERRING VET

Dr. Maniar

Gastrointestinal

There was some residual chyme and gas was noted in the **stomach**, yet not pathological. This is consistent with end post prandial presentation. Transit of chyme into the small intestine was normal. Curvilinear patterns were maintained throughout the GI tract. No evidence of pathology. Small and large intestine demonstrated normal luminal chyme and stool consistency respectively. No obstructive or overt infiltrative disease was noted. No associated abnormal lymphatic activity was noted.

INVOICE

42420

DATE

11/1/22



PATIENT

Pancreas

Belle Robinson

The base and limbs of the **pancreas** were observed to be largely isoechoic to surrounding omental fat. Pancreatic duct and capsular contour were acceptably normal and parenchyma respected normal curvilinear patterns. No overt evidence of active inflammatory or neoplastic disease was noted.

SPECIES

Canine

ULTRASONOGRAPHIC FINDINGS

- Stable abdomen with minor bladder polyp or mineralization
- Comet tail lung pattern – suggestive of thoracic disease.

BREED

Schnauzer

INTERPRETATION OF THE FINDINGS & FURTHER RECOMMENDATIONS

Chest radiographs indicated for further definition. No overt cause of lethargy or anorexia noted in the abdomen. Orthopedic, CNS, or thoracic disease should all be considered.

SEX

Spayed Female

AGE

6 Years

WEIGHT

21.5 Pounds

INTERPRETED BY

Eric Lindquist, DMV
DABVP, Cert. IVUSS

IMAGING PERFORMED BY

Jenn

HOSPITAL NAME

Rockway AH

REFERRING VET

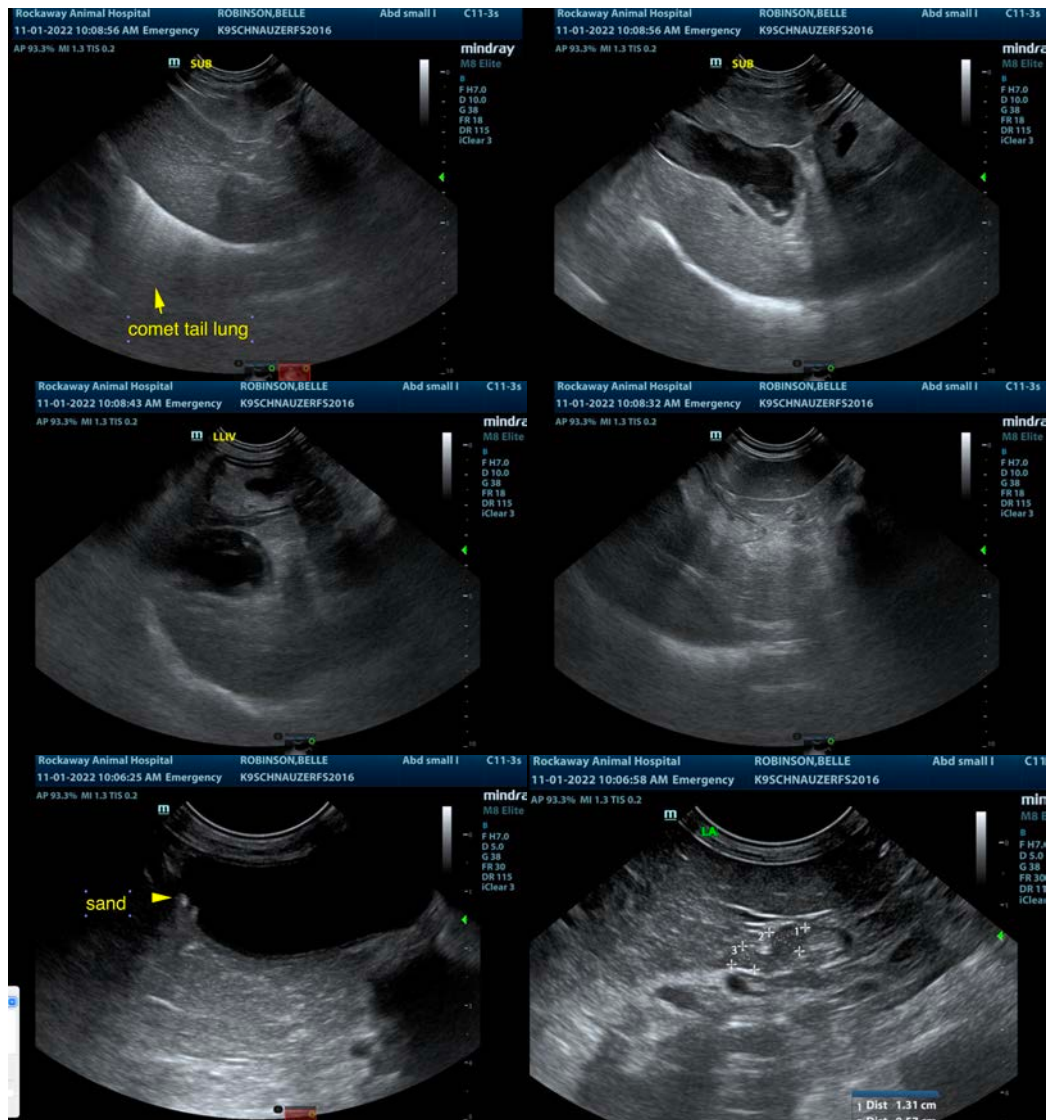
Dr. Maniar

INVOICE

42420

DATE

11/1/22





PATIENT

Belle Robinson

SPECIES

Canine

BREED

Schnauzer

SEX

Spayed Female

AGE

6 Years

WEIGHT

21.5 Pounds

INTERPRETED BY

Eric Lindquist, DMV
DABVP, Cert. IVUSS

IMAGING PERFORMED BY

Jenn

HOSPITAL NAME

Rockaway AH

REFERRING VET

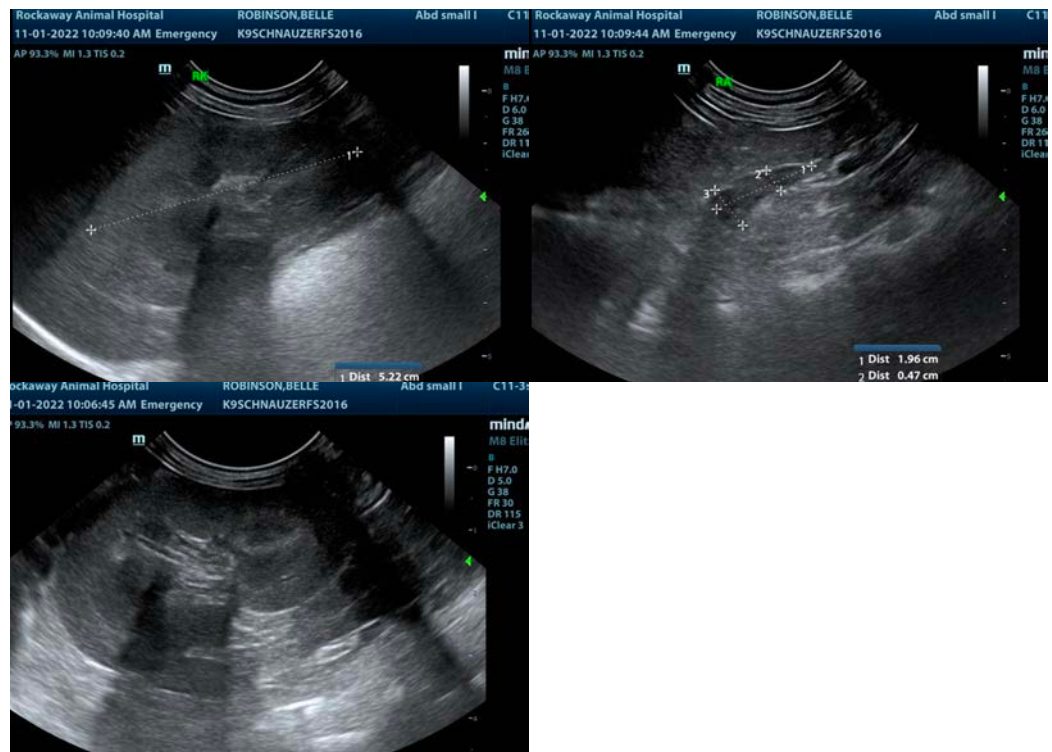
Dr. Maniar

INVOICE

42420

DATE

11/1/22



The information and recommendations provided are based on the images presented by the referring veterinarian/sonographer. No evaluation can be communicated regarding pathology that was not visible in the image/video clips provided.

Thank you for this referral. If the clinical or image interpretation does not parallel your findings or if I can be of any further assistance please contact me.

Eric Lindquist, DMV, DABVP, Cert. IVUSS, CEO of SonoPath.com

info@SonoPath.com