



PATIENT

Rip Domich

SPECIES

Feline

BREED

Domestic Longhair

SEX

Neutered male

AGE

4 years

WEIGHT

5.93 kg

INTERPRETED BY

Eric Lindquist, DMV
DABVP, Cert. IVUSS

IMAGING PERFORMED BY

Dr. DeCordon

HOSPITAL NAME

Mason Dixon Animal
Emergency Hospital

REFERRING VET

Dr. DeCordon

INVOICE

DATE

10/7/22

PRESENTING CLINICAL SIGNS

History: Has always had D+ since O rescued him, went to RDVM last Friday, went home with meds, went back Monday stayed on IV fluids all day, now P is no longer eating and constantly drooling, RDVM is thinking he has Pancreatitis Ate food about a week ago, has not been feeling good since Had a bowel movement last night that was firm, P is still urinating His physical exam was fairly unremarkable other than mild cranial abdominal discomfort.
Abnormal PE/Chem/CBC/UA Results: His bloodwork was fairly unremarkable other than a mildly elevated globulin- immune stimulatory protein.

ULTRASONOGRAPHIC EXAMINATION OF THE ABDOMEN

Urinary System

The **urinary bladder**, trigone, and pelvic urethra presented normal thicknesses and normal tone. The ureters were not visible which is normal. No uroliths or sediment were visualized and anechoic urine was present. No evidence of inflammatory or neoplastic changes was noted. Ureteral papillae were normal.

The **kidneys** revealed normal size and structure, corticomedullary definition and ratio for this age. The cortices presented largely uniform texture with normal echogenic relationship to liver and spleen. Medullary structure differed distinctly from the cortex and no evidence of pelvic dilation was present. The capsules were acceptably uniform without significant irregularities. The caudal pole of the left kidney revealed an anechoic 0.5 cm cyst noted in the caudal pole of the left kidney. The left kidney measured 4.88 cm. The right kidney measured 4.94 cm.

Adrenal Glands

Both **adrenal glands** were visualized and recognized as having normal shape, size, position and echogenicity for this breed. The phrenic vasculature, glandular echogenicity and detail were unremarkable. Capsule, cortex, and medullary definition were normal for this age patient.

Spleen

The **spleen** presented a smooth homogeneous parenchyma hyperechoic to liver and renal cortical parenchyma. The capsule was smooth without noticeable expansion or deviation from within the spleen or adjacent pathology. The splenic vasculature demonstrated normal volume without signs of congestion or thrombosis. No sonographic evidence of acute or chronic inflammatory, neoplastic, or infarctual changes was noted.

Liver

The **liver** images submitted revealed subjectively normal liver size, contour, and structure. Parenchymal echogenicity was naturally coarse and hypoechoic to the spleen. Vascular and biliary tracts were of normal volume with no evidence of congestion. The gallbladder presented acceptably thin walls with primarily anechoic content. The cystic and common bile ducts were normal. No pathological hepatic



PATIENT

Rip Domich

lymphadenopathy was evident. No overt structural evidence of inflammatory, infiltrative or regenerative pathology was evident.

SPECIES

Feline

Gastrointestinal

Examination of the **gastrointestinal tract** revealed a minor hair density in the stomach. The gastrointestinal tract was structurally unremarkable. The curvilinear patterns are respected.

BREED

Domestic Longhair

Pancreas

The base and limbs of the **pancreas** were observed to be largely isoechoic to surrounding omental fat. Pancreatic duct and capsular contour were acceptably normal and parenchyma respected normal curvilinear patterns. No overt evidence of active inflammatory or neoplastic disease was noted.

SEX

Neutered male

AGE

4 years

ULTRASONOGRAPHIC FINDINGS

Structurally unremarkable abdomen and GI tract with possible minor hairball accumulation.

WEIGHT

5.93 kg

INTERPRETATION OF THE FINDINGS & FURTHER RECOMMENDATIONS

Hydrolyzed diet, broad spectrum anti-parasitic protocol and hairball therapy are all solid empirical measures. Endoscopy is warranted to assess for esophageal disease. Sedation and examination of the oral cavity is warranted to assess for underlying pain related disease that may be playing a role in the clinical history, yet the GI tract and remainder of the abdomen appears innocuous.

INTERPRETED BY

Eric Lindquist, DMV
DABVP, Cert. IVUSS

IMAGING PERFORMED BY

Dr. DeCordon

HOSPITAL NAME

Mason Dixon Animal
Emergency Hospital

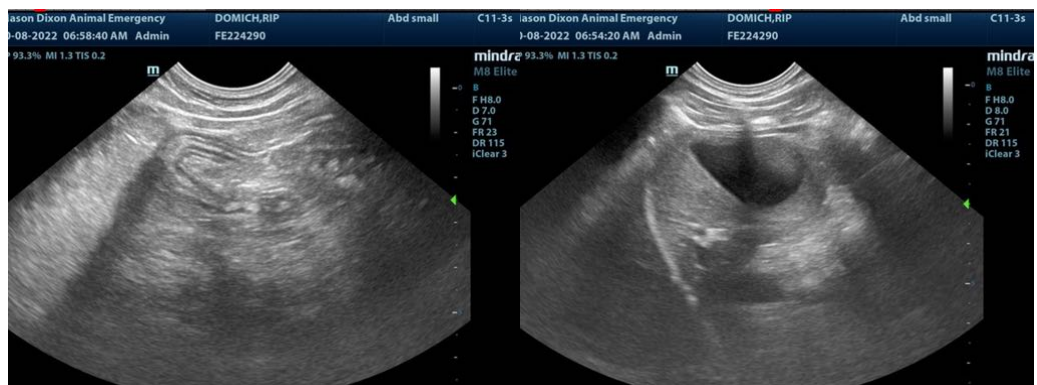REFERRING VET

Dr. DeCordon

INVOICE

DATE

10/7/22





PATIENT

Rip Domich

SPECIES

Feline

BREED

Domestic Longhair

SEX

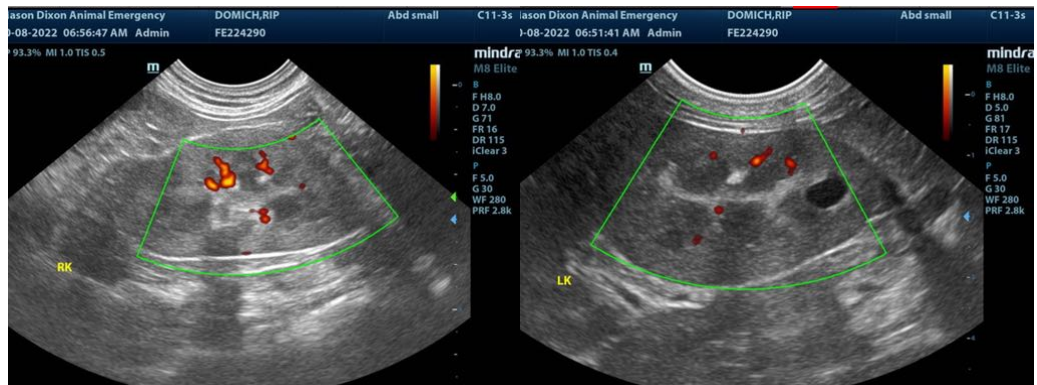
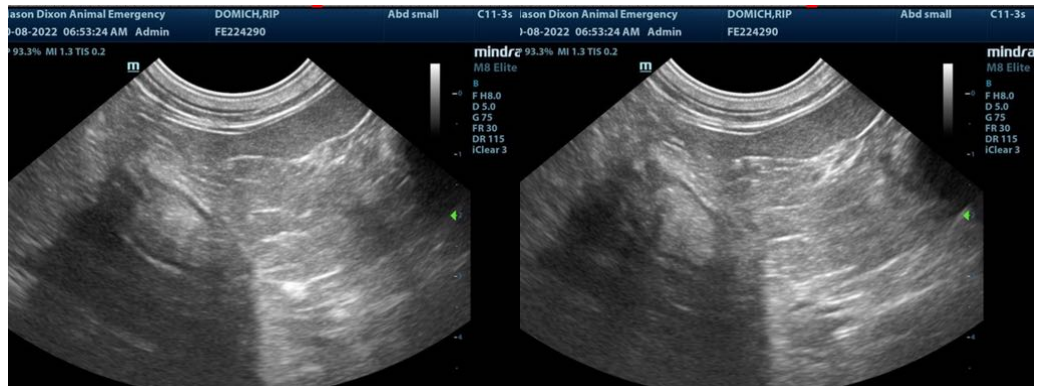
Neutered male

AGE

4 years

WEIGHT

5.93 kg



INTERPRETED BY

Eric Lindquist, DMV
DABVP, Cert. IVUSS

IMAGING PERFORMED BY

Dr. DeCordon

HOSPITAL NAME

Mason Dixon Animal
Emergency Hospital

REFERRING VET

Dr. DeCordon

INVOICE

DATE

10/7/22

The information and recommendations provided are based on the images presented by the referring veterinarian/sonographer. No evaluation can be communicated regarding pathology that was not visible in the image/video clips provided.

Thank you for this referral. If the clinical or image interpretation does not parallel your findings or if I can be of any further assistance please contact me.

Eric Lindquist, DMV, DABVP, Cert. IVUSS, CEO of SonoPath.com
info@SonoPath.com