



PATIENT

Rocco Davidson

SPECIES

Canine

BREED

Basset Hound Mix

SEX

Neutered male

AGE

4 years

WEIGHT

43 lbs

INTERPRETED BY

Eric Lindquist, DMV
DABVP, Cert. IVUSS

IMAGING PERFORMED BY

Adrienne Ligenza

HOSPITAL NAME

Rush Veterinary
Urgent Care

REFERRING VET

Dr. Milot

INVOICE

92268

DATE

10/8/21

PRESENTING CLINICAL SIGNS

History: possible FB, ate piece of carpet, not eating, vomited once with piece of carpet, had BM with piece of carpet

Abnormal PE/Chem/CBC/UA Results: BW pending

ULTRASONOGRAPHIC EXAMINATION OF THE ABDOMEN

Urinary System

The **urinary bladder**, trigone, and pelvic urethra presented normal thicknesses and normal tone. The pelvic urethra was imaged 2.0 cm beyond the cystourethral junction. The ureters were not visible which is normal. No uroliths or sediment were visualized and anechoic urine was present. No evidence of inflammatory or neoplastic changes was noted. Ureteral papillae were normal.

The **kidneys** revealed normal size and structure, corticomedullary definition and ratio for this age. The cortices presented largely uniform texture with normal echogenic relationship to liver and spleen. Medullary structure differed distinctly from the cortex and no evidence of pelvic dilation was present. The capsules were acceptably uniform without significant irregularities. The left kidney measured 6.65 cm. The right kidney measured 6.16 cm.

Adrenal Glands

Both **adrenal glands** were visualized and recognized as having normal shape, size, position and echogenicity for this breed. The phrenic vasculature, glandular echogenicity and detail were unremarkable. Capsule, cortex, and medullary definition were normal for this age patient. The left adrenal gland measured 0.64 cm. The right adrenal gland measured 0.47 cm.

Spleen

The **spleen** presented a smooth homogeneous parenchyma hyperechoic to liver and renal cortical parenchyma. The capsule was smooth without noticeable expansion or deviation from within the spleen or adjacent pathology. The splenic vasculature demonstrated normal volume without signs of congestion or thrombosis. No sonographic evidence of acute or chronic inflammatory, neoplastic, or infarctual changes was noted.

Liver

The **liver** images submitted revealed subjectively normal liver size, contour, and structure. Parenchymal echogenicity was naturally coarse and hypoechoic to the spleen. Vascular and biliary tracts were of normal volume with no evidence of congestion. The gallbladder presented acceptably thin walls with primarily anechoic content. The cystic and common bile ducts were normal. No pathological hepatic lymphadenopathy was evident. No overt structural evidence of inflammatory, infiltrative or regenerative pathology was evident.



PATIENT

Gastrointestinal

Rocco Davidson

The **gastrointestinal tract** revealed minor areas of spasming. The upper gastrointestinal tract revealed areas of soft shadowing material with minor, tethered intestinal tract and stasis. This is consistent with fabric foreign body.

SPECIES

Canine

Pancreas

BREED

Basset Hound Mix

The base and limbs of the **pancreas** were observed to be largely isoechoic to surrounding omental fat. Pancreatic duct and capsular contour were acceptably normal and parenchyma respected normal curvilinear patterns. No overt evidence of active inflammatory or neoplastic disease was noted.

SEX

Neutered male

ULTRASONOGRAPHIC FINDINGS

Upper gastrointestinal foreign body obstruction.

AGE

4 years

INTERPRETATION OF THE FINDINGS & FURTHER RECOMMENDATIONS

Surgical intervention is recommended. Gastrointestinal biopsies are recommended to rule out underlying disease.

WEIGHT

43 lbs

INTERPRETED BY

Eric Lindquist, DMV
DABVP, Cert. IVUSS

IMAGING PERFORMED BY

Adrienne Ligenza

HOSPITAL NAME

Rush Veterinary
Urgent Care

REFERRING VET

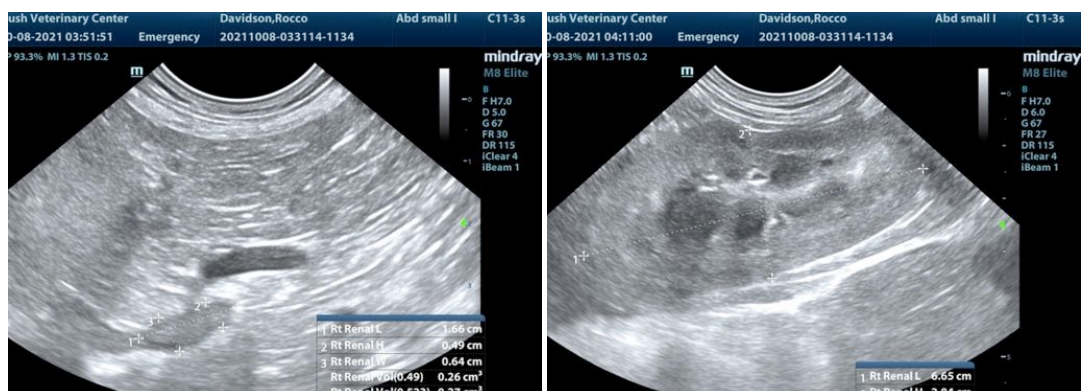
Dr. Milot

INVOICE

92268

DATE

10/8/21





PATIENT

Rocco Davidson

SPECIES

Canine

BREED

Basset Hound Mix

SEX

Neutered male

AGE

4 years

WEIGHT

43 lbs

INTERPRETED BY

Eric Lindquist, DMV
DABVP, Cert. IVUSS

IMAGING PERFORMED BY

Adrienne Ligenza

HOSPITAL NAME

Rush Veterinary
Urgent Care

REFERRING VET

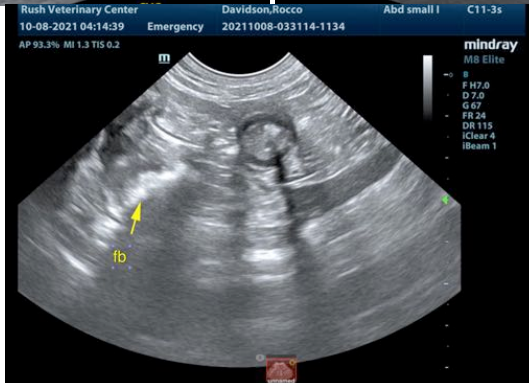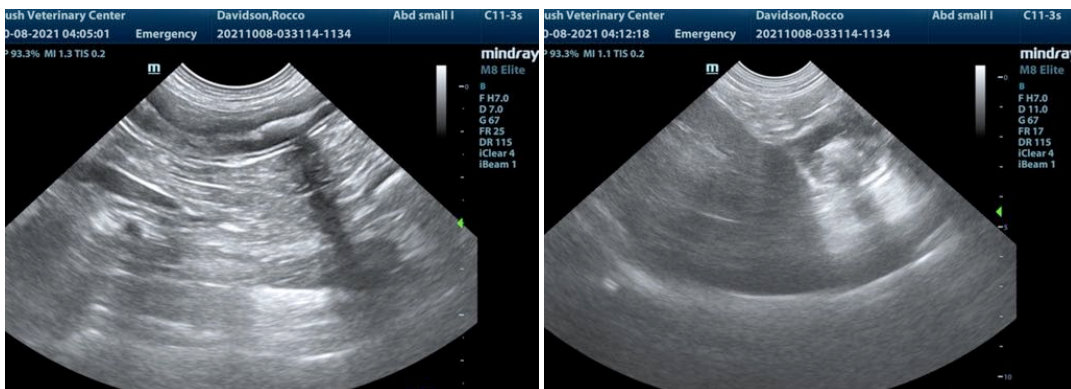
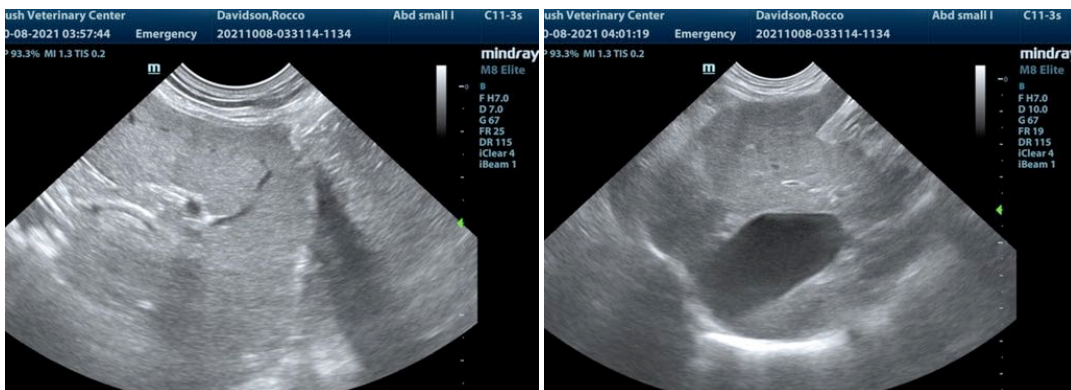
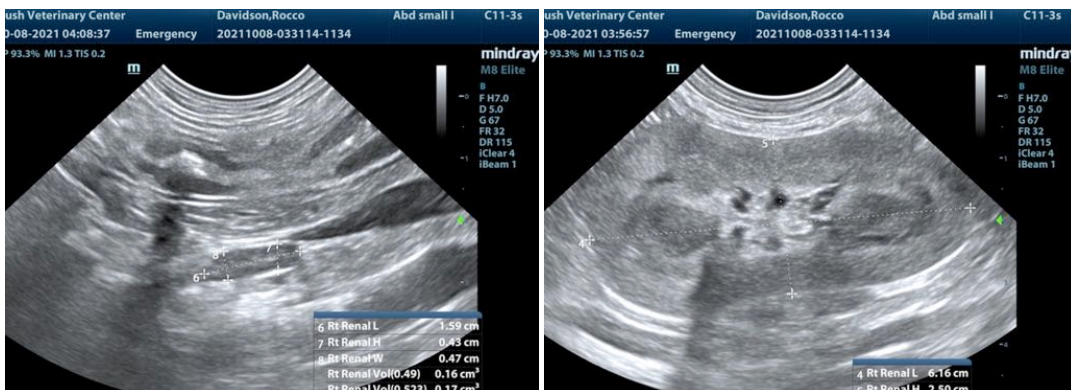
Dr. Milot

INVOICE

92268

DATE

10/8/21





PATIENT

Rocco Davidson

SPECIES

Canine

BREED

Basset Hound Mix

SEX

Neutered male

AGE

4 years

WEIGHT

43 lbs

INTERPRETED BY

Eric Lindquist, DMV
DABVP, Cert. IVUSS

**IMAGING
PERFORMED BY**

Adrienne Ligenza

HOSPITAL NAME

Rush Veterinary
Urgent Care

REFERRING VET

Dr. Milot

INVOICE

92268

DATE

10/8/21

The information and recommendations provided are based on the images presented by the referring veterinarian. No evaluation can be communicated regarding pathology that was not visible in the image/video clips provided.

Thank you for this referral. If the clinical or image interpretation does not parallel your findings or if I can be of any further assistance please contact me.

Eric Lindquist, DMV, DABVP, Cert. IVUSS, CEO of SonoPath.com
info@SonoPath.com