



PATIENT

Raven Wagner

SPECIES

Canine

BREED

American Pitbull

SEX

Female

AGE

9 Years

WEIGHT

53 Pounds

INTERPRETED BY

Eric Lindquist, DMV
DABVP, Cert. IVUSS

IMAGING PERFORMED BY

Jill Rumachik

HOSPITAL NAME

Mazomanie AH

REFERRING VET

Eric Howlett

INVOICE

13646

DATE

10/8/21

PRESENTING CLINICAL SIGNS

History: Intact 9 y.o. female presented for intermittent chronic vomiting and diarrhea - responsive to bland diet.

Abnormal PE/Chem/CBC/UA Results: 9/17/21: ALB 2.1; ALP 19; TP 3.8; GLOB 1.7.

ULTRASONOGRAPHIC EXAMINATION OF THE ABDOMEN

Urinary System

The **urinary bladder**, trigone, and pelvic urethra presented normal thicknesses and normal tone. The ureters were not visible which is normal. No uroliths or sediment were visualized and anechoic urine was present. No evidence of inflammatory or neoplastic changes were noted. Ureteral papillae were normal.

The **kidneys** revealed largely normal size and structure, corticomedullary definition and ratio (cortex 1/3 of medulla) were essentially maintained with some mild age-related loss of curvilinear patterns regarding the capsule and C/M junction. The cortices presented largely uniform texture with some increased echogenicity expected for his age patient. Medullary structure differed distinctly from that of the cortex and no evidence of pelvic dilation was present. The left kidney measured 6.2 cm. The right kidney measured 5.0 cm.

Adrenal Glands

Both **adrenal glands** were not visualized.

Spleen

The **spleen** presented a smooth homogeneous parenchyma hyperechoic to liver and renal cortical parenchyma. The capsule was smooth without noticeable expansion or deviation from within the spleen or adjacent pathology. The splenic vasculature demonstrated normal volume without signs of congestion or thrombosis. No sonographic evidence of acute or chronic inflammatory, neoplastic, or infarctual changes were noted.

Liver

The visible **liver** was unremarkable, however, minimal views present. The gallbladder and common bile duct were unremarkable.

Gastrointestinal

The upper **gastrointestinal** wall was thickened in this patient, appeared to be stomach. Wall thickness measured up to 1.2 cm. The stomach was filled with ingesta.

Pancreas

The base and limbs of the **pancreas** were observed to be largely isoechoic to surrounding omental fat. Pancreatic duct and capsular contour were acceptably normal and parenchyma respected normal curvilinear patterns. No overt evidence of active inflammatory or neoplastic disease was noted.

Free Abdomen

Free fluid was noted in the **abdomen**.



PATIENT

Raven Wagner

SPECIES

Canine

BREED

American Pitbull

SEX

Female

AGE

9 Years

WEIGHT

53 Pounds

INTERPRETED BY

Eric Lindquist, DMV
DABVP, Cert. IVUSS

IMAGING PERFORMED BY

Jill Rumachik

HOSPITAL NAME

Mazomanie AH

REFERRING VET

Eric Howlett

INVOICE

13646

DATE

10/8/21

ULTRASONOGRAPHIC FINDINGS

- Age-related renal changes
- Upper GI tract thickened, appeared to be stomach
- Free fluid in the abdomen

INTERPRETATION OF THE FINDINGS & FURTHER RECOMMENDATIONS

Given the low albumin level, I'm concerned for protein losing enteropathy. Possible protein losing nephropathy even though structurally the GI tract is unremarkable. Screening for Addison's warranted given that the adrenals were not evident. If no significant proteinuria is present, then strict PLE protocol recommended. No evidence of reproductive pathology.

PLE Therapy

Part or all of this protocol may be considered based on your clinical impression of the patient:

OBJECTIVE: keep albumin levels > 2 g/dl, avoid thromboembolism and cavitory effusions, monitor concurrent PLN (Wheaton Terrier PLE/PLN) and liver disease:

Plasma 10 mL / kilogram IV over 4 hours

Or **Human albumin** 2 ml/kg/h over 10 hours. Total daily volume 20.l/kg/day

And Colloids/Hetastarch

10 to 20 mL per kilogram per day and dogs

10 to 15 mL per kilogram per day cats

(Can bolus first 1/3 of dose over 15 minutes)

& maintain on LRS maintenance otherwise.

Metronidazole (10-20 mg/kg po bid)

Famotidine 1 mg/kg Iv Im po dc Sid /bid

Sucralfate 0.5-1 g po tid dogs, 0.5 g bid cats in slurry Or **Misoprostol** 1-5 ug/kg po tid

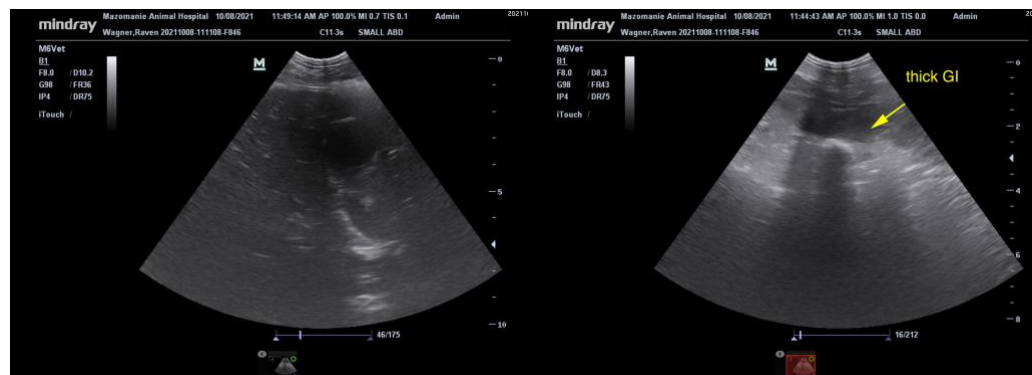Diet: Highly digestible high quality protein, low fiber, low fat diet (< 15% of dry matter). Hydrolyzed protein or novel protein. Purina HA or Royal Canine HP or similar.

Prednisone or prednisolone 2 mg/kg bid x 3-5 days then 2 mg/kg sid. **Chlorambucil** in refractive severe IBD/alimentary lymphoma cases (monitor cbc for rare bone marrow suppression) 4 mg/m² Q 24-48 hours.

Cobalamine (B12) 250-1500 ug/dog weekly x 6 weeks.

Calcium supplementation if necessary.

Aspirin 0.5-1 mg/kg/day or **Clopidrel** (Plavix) 1-5 mg/kg/day.





PATIENT

Raven Wagner

SPECIES

Canine

BREED

American Pitbull

SEX

Female

AGE

9 Years

WEIGHT

53 Pounds

INTERPRETED BY

Eric Lindquist, DMV
DABVP, Cert. IVUSS

IMAGING PERFORMED BY

Jill Rumachik

HOSPITAL NAME

Mazomanie AH

REFERRING VET

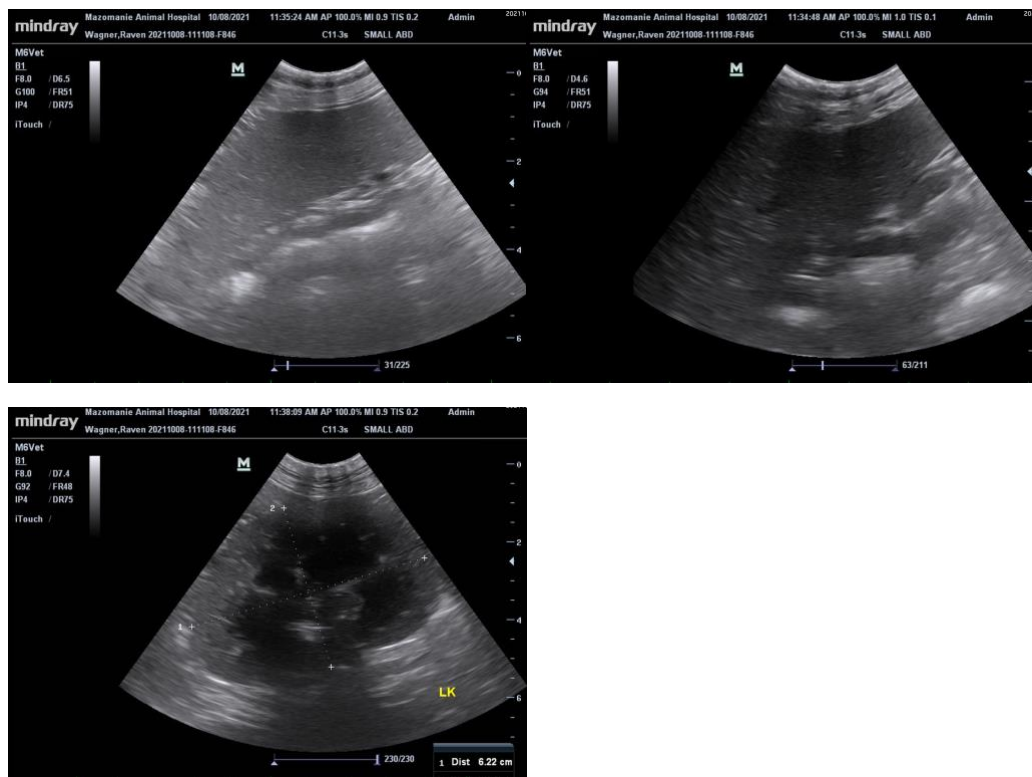
Eric Howlett

INVOICE

13646

DATE

10/8/21



The information and recommendations provided are based on the images presented by the referring veterinarian. No evaluation can be communicated regarding pathology that was not visible in the image/video clips provided.

Thank you for this referral. If the clinical or image interpretation does not parallel your findings or if I can be of any further assistance please contact me.

Eric Lindquist, DMV, DABVP, Cert. IVUSS, CEO of SonoPath.com
info@SonoPath.com

Protein-Losing Nephropathy (PLN)

<http://www.sonopath.com/PLN>

Description: Protein-losing nephropathy (PLN) is a common form of renal disease that typically affects dogs in middle age; it occurs less commonly in cats. Glomerular causes of renal protein loss encompass two broad categories: glomerulonephritis (GN) and amyloidosis. (The causes of GN in human medicine are more specifically differentiated based on a combination of histopathology, immunofluorescence, and electron microscopy findings.) Membranoproliferative glomerulonephritis is the most common cause of GN in dogs and is associated with infectious disease with secondary immune complex deposition as well as Lyme disease. Membranous nephropathy is the second most common cause of GN in dogs and the most common cause in cats. It occurs due to primary immune complex deposition on the urinary side of the basement membrane of the glomerulus, resulting in the leakage of albumin. Amyloidosis is caused by the deposition of amyloid A proteins



PATIENT

Raven Wagner

in a β -pleated sheet configuration in the glomeruli. It is a familial disease in the Shar Pei, but occurs as a reactive disease in other canine breeds. It is also inheritable in the Abyssinian cat, but the amyloidosis occurs in the medulla and is therefore not a protein-losing condition in this breed.

SPECIES

Canine

Glomerular lesions can be associated with:

BREED

American Pitbull

- Infectious diseases:
 - Protozoan: *Babesia*, *Hepatozoon*, and *Leishmania*.
 - Bacterial: *Borrelia*, *Bartonella*, *Brucella*, *Ehrlichia*, *Mycoplasma*, pyometra, pyoderma, endocarditis, and pyelonephritis.
 - Viral: FeLV, FIV, and FIP.
 - Fungal
 - Helminthic: *Dirofilaria*.
- Non-infectious inflammatory diseases: pancreatitis, chronic dermatitis, inflammatory bowel disease, periodontal disease, polyarthritis, and systemic lupus erythematosus (SLE).
- Neoplasia: lymphoma, leukemia, and mast cell disease.
- Familial conditions in the soft-coated Wheaten Terrier, Shar Pei, Beagle, Cocker Spaniel, and Bernese mountain dog.
- Idiopathic conditions.

SEX

Female

AGE

9 Years

WEIGHT

53 Pounds

Post-glomerular causes, such as hemorrhage and inflammation, also contribute to urine protein quantification.

INTERPRETED BY

Eric Lindquist, DMV
DABVP, Cert. IVUSS

Proteinuria Classifications: Patients can be divided into three tiers, depending on their clinical characteristics:

Tier 1A: persistent subclinical proteinuria

Tier 1B: persistent proteinuria with hypertension

IMAGING PERFORMED BY

Jill Rumachik

Tier 2A: proteinuria and hypoalbuminemia

Tier 2B: proteinuria, hypoalbuminemia, and hypertension

HOSPITAL NAME

Mazomanie AH

REFERRING VET

Eric Howlett

Tier 3A: proteinuria and azotemia

Tier 3B: proteinuria, azotemia, and hypertension

INVOICE

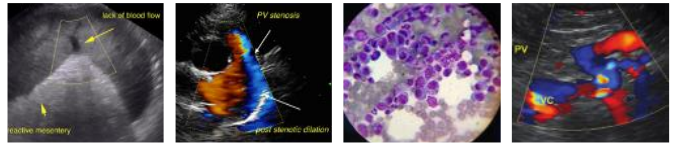
13646

Tier 3C: proteinuria, azotemia, hypertension, and hypoalbuminemia

DATE

10/8/21

Diagnostics: Traditionally, urine protein loss has been detected either through a qualitative test, such as a urine dipstick, or with a semi-quantitative test, such as a urine protein-creatinine (UPC) ratio. When the latter is greater than 0.5, it is considered abnormal. False positive results can occur



PATIENT

Raven Wagner

SPECIES

Canine

BREED

American Pitbull

SEX

Female

AGE

9 Years

WEIGHT

53 Pounds

INTERPRETED BY

Eric Lindquist, DMV
DABVP, Cert. IVUSS

IMAGING PERFORMED BY

Jill Rumachik

HOSPITAL NAME

Mazomanie AH

REFERRING VET

Eric Howlett

INVOICE

13646

DATE

10/8/21

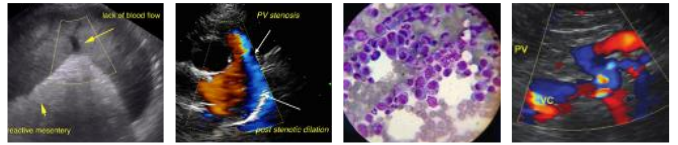
due to contamination of urine with red blood cells, white blood cells, and bacterial protein. Thus, one must use a urine sample with inactive sediment and a negative culture for measurement purposes. A 24-hour urine protein quantification is more accurate but technically more difficult to obtain, as it requires hospitalization and 24-hour urinary catheterization with a closed collection system. Pooling urine samples can be considered in cases where urine protein loss is stable. One must obtain three different urine samples, combine 1 ml from each sample to submit for a UPC test, and ensure that inactive sediments are present in all the samples. There should be a high degree of correlation between the UPC on the pooled sample and the mean of the three samples measured independently. Research has not yet demonstrated the accuracy of pooled samples for urine samples with high protein loss (i.e., in cases where the UPC is > 8).

Further diagnostic tests will depend on the tier classification. Once proteinuria is documented repeatedly, additional tests can be considered to assess for potential underlying causes, and, further to that, possible sources of antigen stimulation. Depending on presentation, tests may include:

- CBC and biochemical profile
- Urine culture and sensitivity
- 4DX
- Blood pressure measurement
- Thoracic and abdominal radiographs
- Spinal radiographs to assess for discospondylitis
- Abdominal ultrasound to assess for evidence of underlying infection or neoplasia
- Echocardiogram to assess for vegetative endocarditis and possible effects of hypertension
- Screen for Cushing's disease, especially if hypertensive (LDDST or ACTH stimulation)
- ANA
- Expanded tick or infectious disease screen
- Renal biopsy to differentiate among specific causes of PLN

Renal biopsy should be considered if proteinuria is severe (UPC > 3.5) and hypoalbuminemia and/or hypertension have been documented. Renal biopsy is an invasive procedure and should be considered only to determine if there is an underlying disease process that would benefit from specific therapy. If the patient is debilitated, severely azotemic, or has uncontrolled hypertension or coagulation abnormalities, then the risk of the procedure and anesthesia may be too great and should not be pursued.

Tissue samples should be submitted for a combination of light microscopy (in formalin; use with special stains), immunofluorescence (in Michel's solution or frozen), and electron microscopy (in formalin with glutaraldehyde). It is imperative to request special media before obtaining the biopsy. Samples can be obtained via ultrasound guidance, laparotomy, or laparoscopy, but cortical samples must be divided so that they can be placed in the three



PATIENT

Raven Wagner

different media. One must ensure that the pre-surgical clotting profile and platelet count are both normal. Patients should undergo pre-biopsy and post-biopsy diuresis.

SPECIES

Canine

Treatment: The main goals of therapy are to i) reduce proteinuria (i.e., UPC < 1.0); ii) prevent a thrombotic event; iii) manage hypertension; and iv) replace fluid deficits. Fluid therapy should be approached cautiously, especially in patients with nephrotic syndrome. Standard therapy for PLN includes a low-protein diet, which in itself will reduce proteinuria, and the administration of an angiotensin-converting enzyme (ACE) inhibitor, such as enalapril (0.5 mg/kg PO BID) or benazepril (0.5 mg/kg PO Q24hr). Newer proposed therapeutic protocols include increasing the ACE inhibitor dose slowly while monitoring BUN and creatinine carefully. The dose can be raised to 1 mg/kg PO BID if needed, provided creatinine has not increased more than 30% from the baseline level.

BREED

American Pitbull

SEX

Female

Another class of drugs currently being used is angiotensin receptor blockers, such as Losartan (the dose in azotemic dogs is 0.125-0.25 mg/kg/day PO Q12-24hr and 0.5-1.0 mg/kg/day in non-azotemic patients). This can be combined with an ACE inhibitor, but it is important to monitor BUN, creatinine, and potassium levels. Spironolactone has been used in people in combination with the other two classes of drugs to further modify the renin-angiotensin-aldosterone system (RAAS) (1-2 mg/kg PO BID); however, the effect of using all three drug classes in dogs has not yet been fully investigated. All of these medications are potassium sparing; thus, monitoring for hyperkalemia is important.

AGE

9 Years

WEIGHT

53 Pounds

INTERPRETED BY

Eric Lindquist, DMV
DABVP, Cert. IVUSS

Hypertension is managed with amlodipine (0.1-0.2 mg/kg PO Q12-24hr) when an ACE inhibitor is insufficient to control blood pressure. Supplementing with an anti-thrombotic agent, such as aspirin (1 mg/kg PO Q24hr), may be considered in advanced cases, especially once the patient is hypoalbuminemic. Omega-3 fatty acids can be given (0.25-0.5 g/day), but are typically increased in standard kidney diets.

IMAGING PERFORMED BY

Jill Rumachik

HOSPITAL NAME

Mazomanie AH

The most recent controversy in the management of glomerular diseases is the use of immunosuppressive medications. Because it is possible to arrive at a more definitive diagnosis in human patients, the use of immunosuppressive agents can be useful in the management of the disease, specifically when the disease is immune-mediated in its pathogenesis, such as SLE, membranous nephropathy, and minimal change disease glomerulonephritis. The procurement of a renal biopsy is being advocated in dogs so that practitioners can identify the population of patients that may benefit most from immunosuppressive therapy. Presently, there is no evidence-based medicine to suggest that immunosuppressive therapy should definitely be incorporated into a daily protocol for canine patients; however, it could be beneficial in some cases and may even result in remission. Further investigation is warranted. Trials are currently being conducted in patients with Lyme nephritis that are treated with immunosuppressive agents in addition to standard antibiotic therapy. The IRIS Treatment of Canine Glomerular Disease Study Group has suggested the trial use of immunosuppressive therapy in severe, persistent, or progressive PLN, even without a biopsy diagnosis in specific cases that are

REFERRING VET

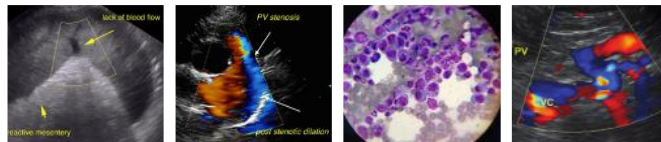
Eric Howlett

INVOICE

13646

DATE

10/8/21



PATIENT

Raven Wagner

SPECIES

Canine

BREED

American Pitbull

SEX

Female

AGE

9 Years

WEIGHT

53 Pounds

INTERPRETED BY

Eric Lindquist, DMV
DABVP, Cert. IVUSS

**IMAGING
PERFORMED BY**

Jill Rumachik

HOSPITAL NAME

Mazomanie AH

REFERRING VET

Eric Howlett

INVOICE

13646

DATE

10/8/21

unresponsive to standard therapy (i.e., nephrotic syndrome, progressively azotemic, hypoalbuminemic patients). One can also consider administering the following drugs: pulse steroid therapy, mycophenolate, cyclophosphamide, azathioprine, and chlorambucil. One should monitor blood work, UPC ratio, and blood pressure weekly for 2 weeks, then biweekly for 6 weeks, then monthly. If there is further deterioration, immunosuppressive therapy should be discontinued.

References:

Goldstein R and Polzin D. Treatment of canine glomerular disease: report of the IRIS treatment of canine glomerular disease study group. Proceedings from the American College of Veterinary Internal Medicine, Denver, CO, June 15-18, 2011.

Grauer GF, Greco DS, Getzy DM, et al. Effects of enalapril versus placebo as a treatment for canine idiopathic glomerulonephritis. *J Vet Intern Med* 2000;14:526-33.

Less GE, Cianciolo RE, and Clubb FJ. Renal biopsy and pathologic evaluation of glomerular disease. *Top Companion Anim Med* 2011;26(3):143-53.

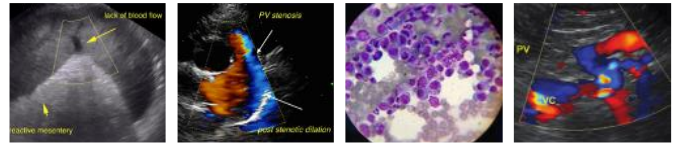
LeVine DA, Zhang D, Vaden SL. The use of pooled vs. serial urine samples to measure urine protein:creatinine ratios. *Vet Clin Pathol* 2010;39(1):53-56.

Nabity MB, Boggess MM, Kashtan CE, et al. Day-to-day variability in the urine protein:creatinine ratio in female dogs with stable glomerular proteinuria caused by x-linked hereditary nephropathy. *J Vet Intern Med* 2007;21:425-30.

Vaden SL. Glomerular Disease. *Top Companion Anim Med* 2011;26(3):128-34.

Vaden SL. Glomerular Diseases. In: Ettinger SJ and Feldman EC, eds. *Textbook of Veterinary Internal Medicine, 7th Ed.* St Louis, MI: Saunders Elsevier; 2010;2021-36.

Vaden SL. Microalbuminuria: What is it and how do I interpret it. Proceedings from the American College of Veterinary Internal Medicine, Charlotte, NC, June 4-7, 2003.



PATIENT

Raven Wagner

Vaden SL et al. Urinary tract inflammation has a variable effect in urine albumin concentration.
J Vet Intern Med 2002;16:378 (abstract).

SPECIES

Canine

BREED

American Pitbull

SEX

Female

AGE

9 Years

WEIGHT

53 Pounds

INTERPRETED BY

Eric Lindquist, DMV
DABVP, Cert. IVUSS

**IMAGING
PERFORMED BY**

Jill Rumachik

HOSPITAL NAME

Mazomanie AH

REFERRING VET

Eric Howlett

INVOICE

13646

DATE

10/8/21