

**DATE PRESENTING CLINICAL SIGNS**

10/8/21 History: Unable to urinate. AEH unable to pass cath. No stones visualized on radiographs.

PATIENT

Peaches Thurston

Current Medications: Baytril, Gabapentin.
 Date of Previous IntraPet Ultrasound: No previous
 Sedation: not needed
 Stat Report: not requested

SPECIES

Canine

BREED

Pitbull

SEX

Spayed Female

AGE

2010

WEIGHT

60 Pounds

LIMITED ULTRASONOGRAPHIC EXAMINATION

The **bladder** wall itself, cystourethral junction and proximal urethra were unremarkable. Small bladder calculi noted- should be small enough to pass. However, some mineralization was noted in the deep pelvic urethra, is concerning and presents an irregular contour, not typical for embedded urethral calculi. Strong concern for deep urethral carcinoma. Iliac lymph nodes were slightly enlarged, measuring 1.0 cm x 0.5 cm.

The **kidneys** revealed normal size and structure, corticomedullary definition and ratio for this age. The cortices presented largely uniform texture with normal echogenic relationship to liver and spleen. Medullary structure differed distinctly from the cortex and no evidence of pelvic dilation was present. The capsules were acceptably uniform without significant irregularities. The left kidney measured 6.84 cm. The right kidney measured 6.25 cm.

ULTRASONOGRAPHIC FINDINGS

- Deep urethral mineralization

INTERPRETATION OF THE FINDINGS & FURTHER RECOMMENDATIONS

Cystoscopy warranted to assess for deep urethral neoplasia/carcinoma versus embedded calculi (less likely). Guarded prognosis. The area in question is approximately 4.0- 5.0 cm caudal to the cystourethral junction. Ultrasound guided FNA of the iliac lymph nodes would be appropriate to assess for metastatic disease versus reactive lymphadenitis.

INTERPRETED BY

Eric Lindquist, DMV
 DABVP, Cert. IVUSS

HOSPITAL NAME

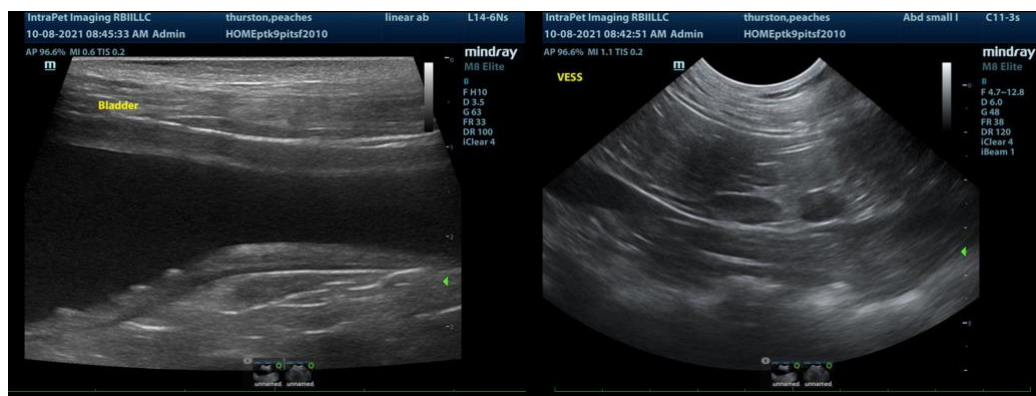
Homeward Bound VS

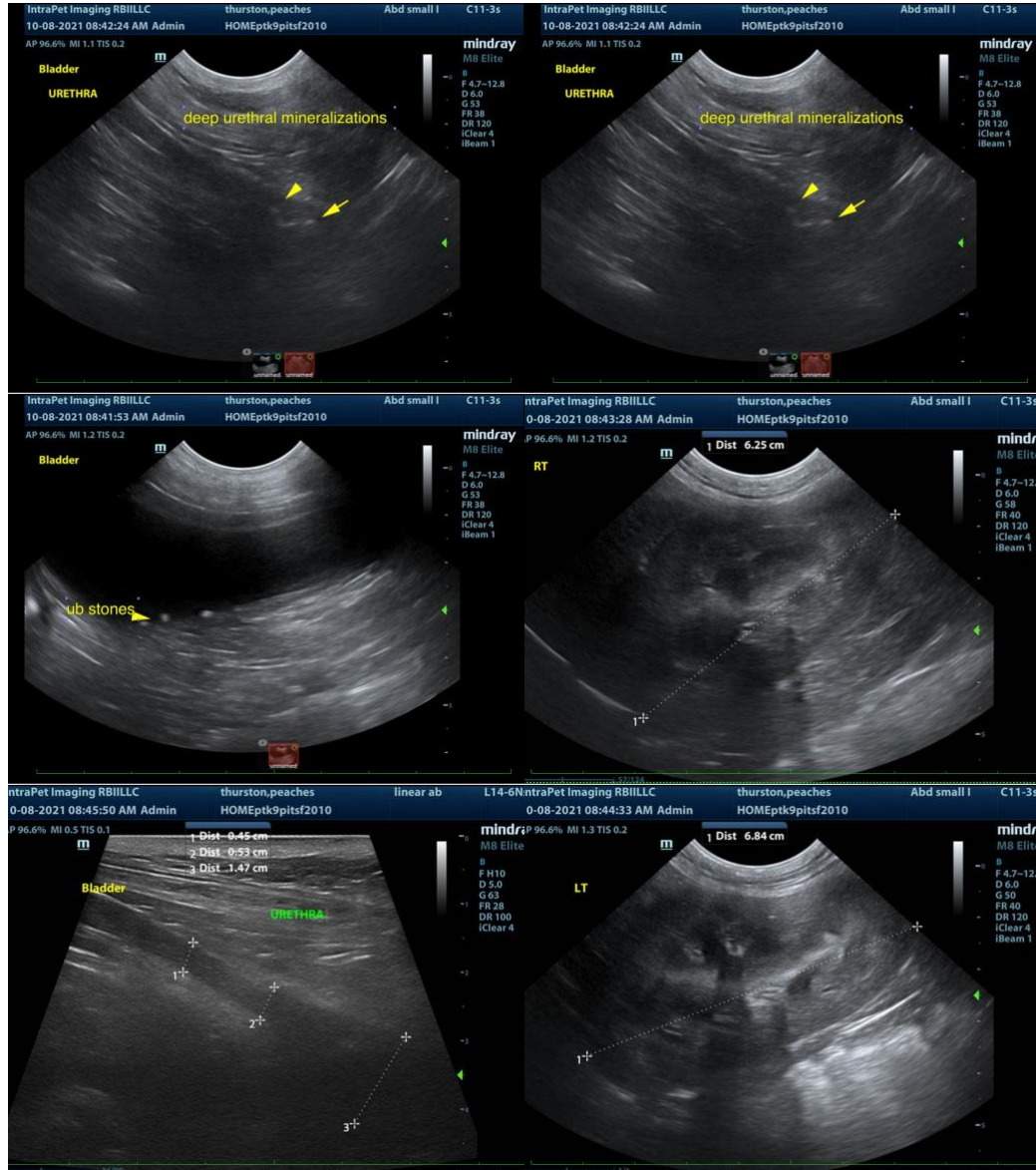
REFERRING VET

Dr. Vance

INVOICE

13640





The information and recommendations provided are based on the images presented by the referring veterinarian. No evaluation can be communicated regarding pathology that was not visible in the image/video clips provided.

Thank you for this referral. If the clinical or image interpretation does not parallel your findings or if I can be of any further assistance please contact me.

Eric Lindquist, DMV, DABVP, Cert. IVUSS, CEO of SonoPath.com
info@SonoPath.com