

PATIENT

Walter Waffle

SPECIES

Canine

BREED

English Springer

SEX

Neutered Male

AGE

1 Year

WEIGHT

44 Pounds

INTERPRETED BY

Eric Lindquist, DMV
DABVP, Cert. IVUSS

IMAGING PERFORMED BY

Adrienne Waffle

HOSPITAL NAME

Torch Lake VC

REFERRING VET

Adrienne Waffle

INVOICE

17605

DATE

10/7/22

PRESENTING CLINICAL SIGNS

History: Noticed laryngeal area felt enlarged on L side of neck when compared to R - no distinct nodule able to be palpated. Lymph nodes palpated WNL

LIMITED ULTRASONOGRAPHIC EXAMINATION

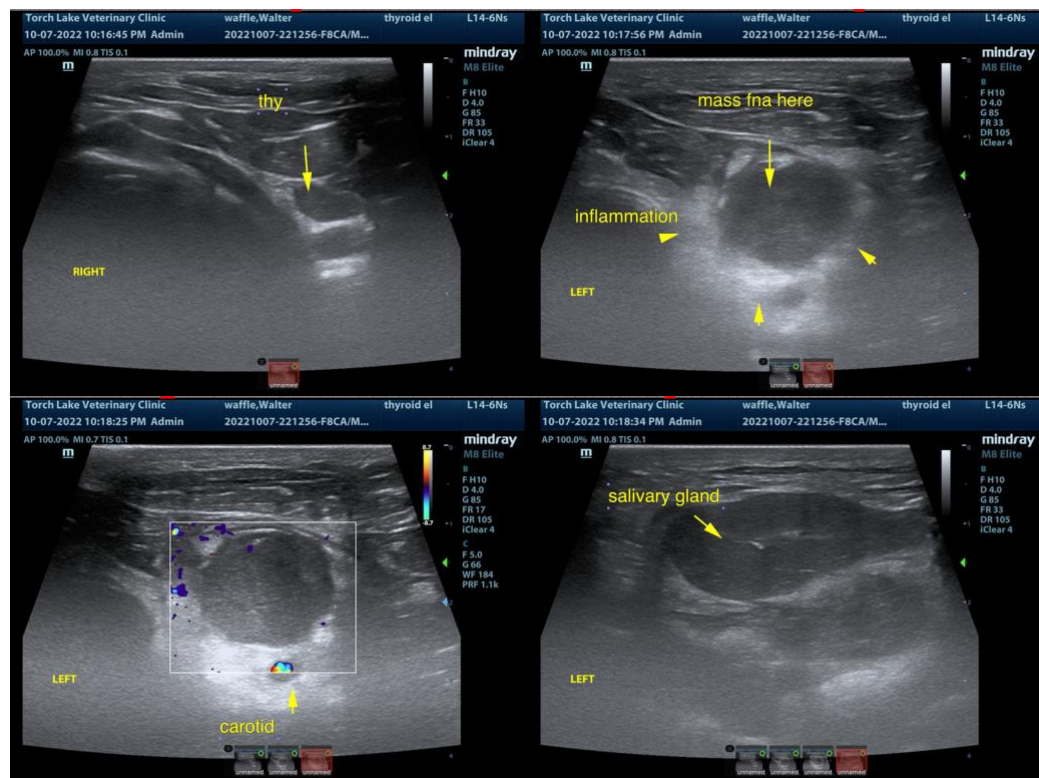
The right and left cervical regions were imaged. The right thyroid and carotid, regional tissues and salivary glands were all normal. The trachea was normal. On the left side, the esophagus was uniform with no evident pathology. However, an undifferentiated mass was noted in this patient, measuring approximately 2.5 cm in length versus 1.5 cm in width with significant regional inflammation. The mass appeared to be a cluster of lymph nodes or possible thyroid origin. FNA is indicated. The mass does not appear resectable, as it appears to be multinodular. Recognizable left thyroid tissue was not evident and may be obscured by the mass.

ULTRASONOGRAPHIC FINDINGS

- Multinodular left sided cervical mass, either lymph node or thyroid in origin

INTERPRETATION OF THE FINDINGS & FURTHER RECOMMENDATIONS

FNA of the mass is indicated for further definition. CT of the neck would be ideal for further definition. Suspected aggressive neoplastic process. Abdominal and chest imaging recommended to assess for related disease.





PATIENT

Walter Waffle

SPECIES

Canine

BREED

English Springer

SEX

Neutered Male

AGE

1 Year

WEIGHT

44 Pounds

INTERPRETED BY

Eric Lindquist, DMV
DABVP, Cert. IVUSS

IMAGING PERFORMED BY

Adrienne Waffle

HOSPITAL NAME

Torch Lake VC

REFERRING VET

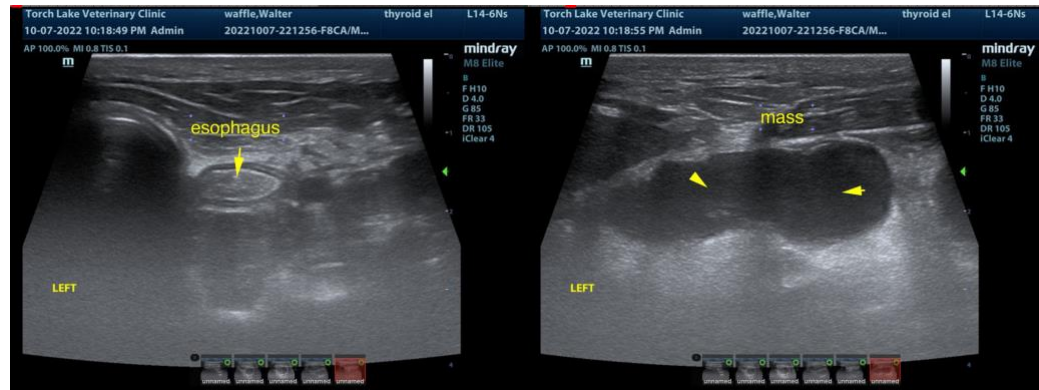
Adrienne Waffle

INVOICE

17605

DATE

10/7/22



The information and recommendations provided are based on the images presented by the referring veterinarian. No evaluation can be communicated regarding pathology that was not visible in the image/video clips provided.

Thank you for this referral. If the clinical or image interpretation does not parallel your findings or if I can be of any further assistance please contact me.

Eric Lindquist, DMV, DABVP, Cert. IVUSS, CEO of SonoPath.com
info@SonoPath.com