

**DATE**

10/7/22

PRESENTING CLINICAL SIGNS

History: Vomited blood in August. Has been having intermittent vomiting since. Treated recently for skin rash with Cefpodoxime and topical GentaCalm spray.

PATIENT

Tucker Brown

Current Medications: None listed. Coming in on Gaba/Traz.

Lab Results: 9/14 WNL. Repeat panel 9/22 ALT 148, Lipase 2503, Cholesterol 321.

Date of Previous IntraPet Ultrasound: No previous.

Sedation: P coming in on gaba/traz. Dexdomitor IV.

Stat Report: Not requested.

Imaging Performed By: Rachel Brillhart, RDMS.

SPECIES

Canine

BREED

Great Pyrenees

SEX

Neutered Male

AGE

10/1/16

WEIGHT

127 Pounds

ULTRASONOGRAPHIC EXAMINATION OF THE ABDOMEN**Urinary System**

The **urinary bladder**, trigone, and pelvic urethra presented normal thicknesses and normal tone. The ureters were not visible which is normal. No uroliths or sediment were visualized, and anechoic urine was present. No evidence of inflammatory or neoplastic changes were noted. Ureteral papillae were normal.

The **kidneys** revealed normal size and structure, corticomedullary definition and ratio for this age. The cortices presented largely uniform texture with normal echogenic relationship to liver and spleen. Medullary structure differed distinctly from the cortex and no evidence of pelvic dilation was present. The capsules were acceptably uniform without significant irregularities. The left kidney measured 7.77 cm. The right kidney measured 7.47 cm.

Adrenal Glands

The **left adrenal gland** was flattened and isoechoic, measuring 2.93 cm x 0.41 cm at the caudal pole and 0.58 cm at the cranial pole.

The **right adrenal gland** was normal in size and contour, measuring 3.36 cm x 0.77 cm at the caudal pole and 0.81 cm at the cranial pole.

Spleen

The **spleen** presented a smooth homogeneous parenchyma hyperechoic to liver and renal cortical parenchyma. The capsule was smooth without noticeable expansion or deviation from within the spleen or adjacent pathology. The splenic vasculature demonstrated normal volume without signs of congestion or thrombosis. No sonographic evidence of acute or chronic inflammatory, neoplastic, or infarctual changes were noted.

Liver

The **liver** images submitted revealed subjectively normal liver size, contour, and structure. Parenchymal echogenicity was naturally coarse and hypoechoic to the spleen. Vascular and biliary tracts were of normal volume with no evidence of congestion. The gallbladder presented acceptably thin walls with primarily anechoic content. The cystic and common bile ducts were normal. No pathological hepatic lymphadenopathy was evident. No overt structural evidence of inflammatory, infiltrative or regenerative pathology was evident.

Gastrointestinal**INTERPRETED BY**Eric Lindquist, DMV
DABVP, Cert. IVUSS**HOSPITAL NAME**

Homeward Bound

REFERRING VET

Dr. Sorum

INVOICE

17619

The **pylorus** was clearly visualized without evident pathology. Minor upper GI gas was noted, yet the GI tract was structurally unremarkable with curvilinear patterns maintained. Some gas interface may be obstructing some finer mucosal detail changes, however, structurally unremarkable.

Pancreas

Minor heterogeneous **pancreatic** changes were noted. Low grade inflammation is likely. Subxiphoid palpation is recommended to assess for pain or discomfort associated with the pancreas. The changes were minor.

ULTRASONOGRAPHIC FINDINGS

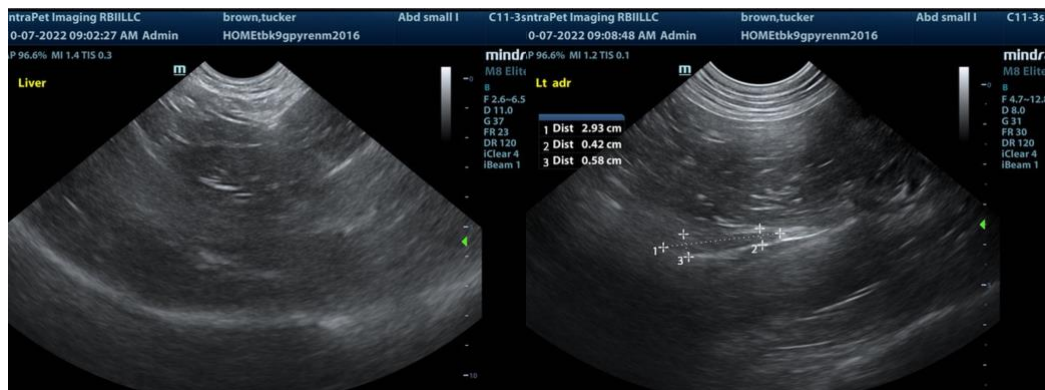
- Structurally unremarkable abdomen
- Flattened isoechoic left adrenal gland
- Minor heterogeneous pancreatic changes
- Upper GI gas

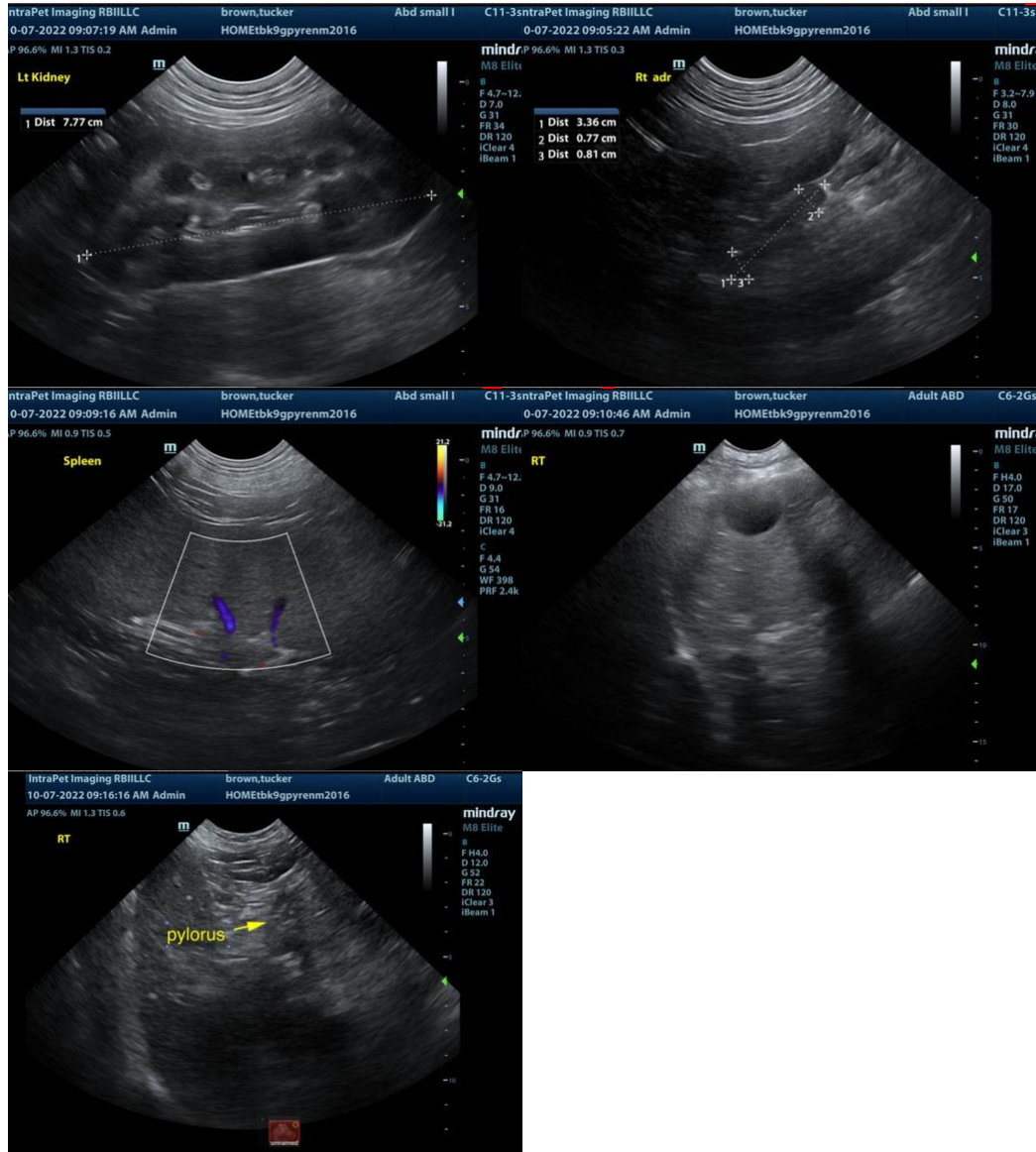
INTERPRETATION OF THE FINDINGS & FURTHER RECOMMENDATIONS

Given the patient history, GI protectant protocol is warranted. Endoscopy is indicated if clinical signs persist. I recommend a fresh fecal smear and fecal floatation analysis. Screening for Addisons is warranted given the flattened left adrenal gland. The right adrenal gland was structurally normal. A clinical trial of the following may prove effective.

Helicobacter/Gastritis protocol

A clinical trial of **Zithromax (Dogs: 5-10 mg/kg p.o. q24h**. May increase dosing interval to q48h after 3-5 days of treatment), **Metronidazole (10-20 mg/kg p.o. b.i.d.)**, **Pepcid (0.5-1 mg/kg s.i.d.)** and **Sucralfate (0.5-2 g/dog PO)** or **Omeprazole (1 mg/kg p.o. s.i.d.)** over the next 3 weeks along with a **novel-protein or hydrolyzed diet** with slurry feeding b.i.d./t.i.d. over the next 2-4 days and then increase to canned diet bid. Dry food should be avoided over the next 4 weeks. A recheck sonogram to assess GI improvement or progression would be ideal in 4 weeks.





The information and recommendations provided are based on the images presented by the referring veterinarian. No evaluation can be communicated regarding pathology that was not visible in the image/video clips provided.

Thank you for this referral. If the clinical or image interpretation does not parallel your findings or if I can be of any further assistance please contact me.

Eric Lindquist, DMV, DABVP, Cert. IVUSS, CEO of SonoPath.com
 info@SonoPath.com