



PATIENT

Ozzy Robinson

PRESENTING CLINICAL SIGNS

Wt loss, anorexia. Concern due to pleural effusion and possible mass. Increased RR/RE.

SPECIES

Canine

Abnormal PE/Chem/CBC/UA Results: WNL

ULTRASONOGRAPHIC EXAMINATION OF THE CHEST

BREED

Dachshund

Rapid view of the heart revealed minor vegetative mitral valve changes. Normal volumes and contractility. Non-cardiogenic pleural effusion noted in the chest. Variable areas of lung consolidation noted and nodular pleura. Comet tail lung pattern noted through the diaphragm.

SEX

Neutered Male

- Non-cardiogenic pleural effusion
- Minor valvular disease without volume overload

INTERPRETATION OF THE FINDINGS & FURTHER RECOMMENDATIONS

AGE

12 Years

Primary lung pathology or metastatic disease suspected. Lung/thoracic neoplasia, carcinomatosis, lymphomatosis, lung lobe torsion all potentials. Pleurocentesis and cytospin warranted to assess underlying cytology +/- culture. Chest CT would be ideal in this patient. Abdominal sonogram warranted to assess for primary disease that may be metastatic to the chest.

WEIGHT

14 Pounds

SonoPath CT Services are offered at the [Blairstown Animal Hospital](https://www.blairstownanimalhospital.com/). Blairstown animal hospital is just a 30-minute drive west on route 80 from the route 80/287 interchange/Parsippany, New Jersey. More information can be found at:

INTERPRETED BY

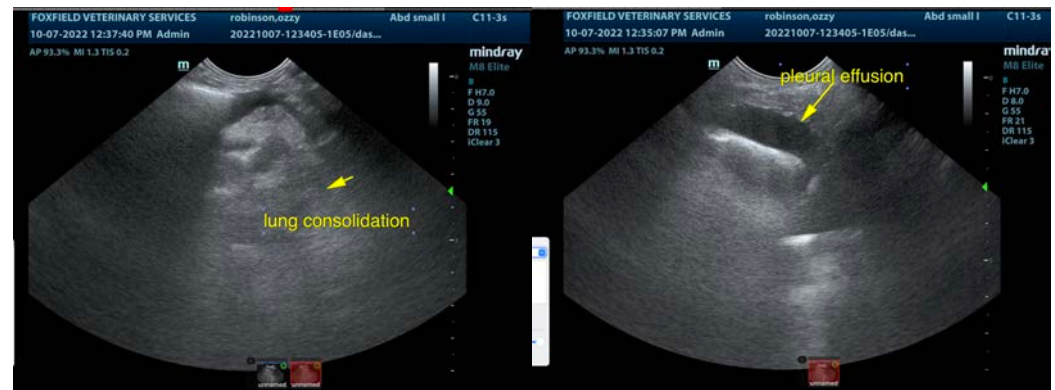
Eric Lindquist, DMV

<https://sonopath.com/resources/sonopaths-teleconsultation-services-and-sdep-certification/sonopath-ct-services>

DABVP, Cert. IVUSS

IMAGING PERFORMED BY

Dr. Rodriguez



HOSPITAL NAME

Foxfield Vet Services

REFERRING VET

Dr. Rodriguez

INVOICE

41892

DATE

10/7/22



PATIENT

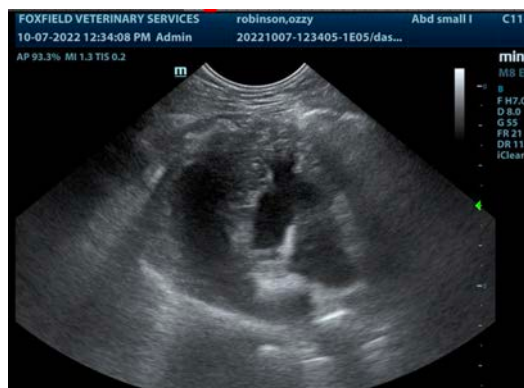Ozzy Robinson

SPECIES

Canine

BREED

Dachshund



SEX

Neutered Male

The information and recommendations provided are based on the images presented by the referring veterinarian/sonographer. No evaluation can be communicated regarding pathology that was not visible in the image/video clips provided.

AGE

12 Years

Thank you for this referral. If the clinical or image interpretation does not parallel your findings or if I can be of any further assistance please contact me.

Eric Lindquist, DMV, DABVP, Cert. IVUSS, CEO of SonoPath.com

info@SonoPath.com

WEIGHT

14 Pounds

INTERPRETED BY

Eric Lindquist, DMV

DABVP, Cert. IVUSS

IMAGING PERFORMED BY

Dr. Rodriguez

HOSPITAL NAME

Foxfield Vet Services

REFERRING VET

Dr. Rodriguez

INVOICE

41892

DATE

10/7/22