



PATIENT

Boots Kendrick

SPECIES

Feline

BREED

Domestic Shorthair

SEX

Spayed female

AGE

14 years

WEIGHT

9.16 lbs

INTERPRETED BY

Eric Lindquist, DMV
DABVP, Cert. IVUSS

IMAGING PERFORMED BY

Jack Reese

HOSPITAL NAME

Willow Run VC

REFERRING VET

Dr. Leppien

INVOICE

39987

DATE

10/7/22

PRESENTING CLINICAL SIGNS

History: Presented on 10/6 with history of vomiting since the evening of 10/5. She was not able to keep any food down when she presented. Started her on IV fluids and gave Cerenia. Ate a small amt of food in the afternoon of 10/7 with no vomiting, fasted overnight for u/s She is hyperthyroid and well controlled on 2.5mg Methimazole twice daily

Abnormal PE/Chem/CBC/UA Results: Slight decreased potassium, likely secondary to vomiting, otherwise unremarkable

ULTRASONOGRAPHIC EXAMINATION OF THE ABDOMEN

Urinary System

The **urinary bladder**, trigone, and pelvic urethra presented normal thicknesses and normal tone. The ureters were not visible which is normal. No uroliths or sediment were visualized and anechoic urine was present. No evidence of inflammatory or neoplastic changes was noted. Ureteral papillae were normal.

The **kidneys** revealed normal size and structure, corticomedullary definition and ratio for this age. The cortices presented largely uniform texture with normal echogenic relationship to liver and spleen. Medullary structure differed distinctly from the cortex. The capsules were acceptably uniform without significant irregularities. A cortical infarct was noted at the cranial pole of the right kidney. Pinpoint renal mineralization was noted in both kidneys. The right kidney measured 4.2 cm. The left kidney measured 3.85 cm with slight pyelectasia. Blood flow to the kidneys appeared normal except for the area of the infarct.

Adrenal Glands

Both **adrenal glands** were visualized and recognized as having normal shape, size, position and echogenicity for this breed. The phrenic vasculature, glandular echogenicity and detail were unremarkable. Capsule, cortex, and medullary definition were normal for this age patient. The left adrenal gland measured 0.32 cm. The right adrenal gland measured 0.32 cm.

Spleen

The **spleen** presented a smooth homogeneous parenchyma hyperechoic to liver and renal cortical parenchyma. The capsule was smooth without noticeable expansion or deviation from within the spleen or adjacent pathology. The splenic vasculature demonstrated normal volume without signs of congestion or thrombosis. No sonographic evidence of acute or chronic inflammatory, neoplastic, or infarctual changes was noted.

Liver

The **liver** images submitted revealed subjectively normal liver size, contour, and structure. Parenchymal echogenicity was naturally coarse and hypoechoic to the spleen. Vascular and biliary tracts were of normal volume with no evidence of congestion. The gallbladder presented acceptably thin walls with primarily anechoic content. The cystic and common bile ducts were normal. No pathological hepatic lymphadenopathy was evident. No overt structural evidence of inflammatory, infiltrative or regenerative pathology was evident.



PATIENT

Boots Kendrick

Gastrointestinal

SPECIES

Feline

The **gastrointestinal** presentation revealed mild uniform prominence of the gastric mucosa as well as areas of "ropey" small intestinal wall with slight disruption of the normal 1:3 muscularis/mucosal ratio. The intestinal submucosa was slightly irregular, thickened and hyperechoic suggestive of low grade, chronic disease. The mesenteric lymph node was reactive and measured 1.5 x 0.8 cm.

BREED

Domestic Shorthair

Pancreas

SEX

Spayed female

The base and limbs of the **pancreas** were observed to be largely isoechoic to surrounding omental fat. Pancreatic duct and capsular contour were acceptably normal and parenchyma respected normal curvilinear patterns. No overt evidence of active inflammatory or neoplastic disease was noted.

AGE

14 years

ULTRASONOGRAPHIC FINDINGS

Right renal infarct.

WEIGHT

9.16 lbs

Degenerative renal changes with mineralization and slight pyelectasia in the left kidney.

Diffuse intestinal thickening without neoplastic criteria.

INTERPRETATION OF THE FINDINGS & FURTHER RECOMMENDATIONS

INTERPRETED BY

Eric Lindquist, DMV
DABVP, Cert. IVUSS

Pre renal and renal disease are likely playing a role in this patient. Management for inflammatory bowel is indicated. Full thickness intestinal biopsies are warranted if clinical management is not effective. No neoplastic criteria was present; however, I cannot rule out the potential of an emerging pre-neoplastic state in the GI tract. Clinical trial fo the following may prove fruitful.

IMAGING PERFORMED BY

Jack Reese

Part or all of this protocol may be considered based on your clinical impression of the patient:

HOSPITAL NAME

Willow Run VC

Recommend pain management when anorexic with **Buprenorphine** (0.01-0.02 mg/kg IM or SC), clinical trial of **Zithromax** (50 mg sid/cat x 10 days, 3 weeks if bartonella +), **Prednisolone** (0.5-2 mg/kg tapering over 1 week to minimal effective dose), and **B12 injections** if weight loss (Cyanobalamine 250 mcg sub-q once-weekly x six weeks, then every other week for six weeks and then once-monthly, long-term if necessary), **novel-protein or hydrolyzed diet** (*Hydrolyzed diets have been shown to be more effective in dietary intolerance case management compared to hypoallergenic diets*) or the **magical Purina DM** (changing protein source is crucial and may need rotation every 6 months if clinical signs recur) Diet trials is a whatever works phenomenon. If vomiting becomes a persistent issue then endoscopy would be warranted and/or recheck sonogram to assess more emerging disease. One diet does not work for all patients so different trials may be necessary or protein source rotation every 6 months as new sensitivities develop.

REFERRING VET

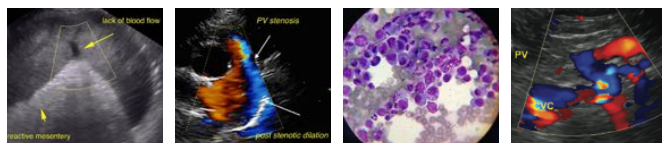
Dr. Leppien

INVOICE

39987

DATE

10/7/22



PATIENT

Boots Kendrick

SPECIES

Feline

BREED

Domestic Shorthair

SEX

Spayed female

AGE

14 years

WEIGHT

9.16 lbs

INTERPRETED BY

Eric Lindquist, DMV
DABVP, Cert. IVUSS

**IMAGING
PERFORMED BY**

Jack Reese

HOSPITAL NAME

Willow Run VC

REFERRING VET

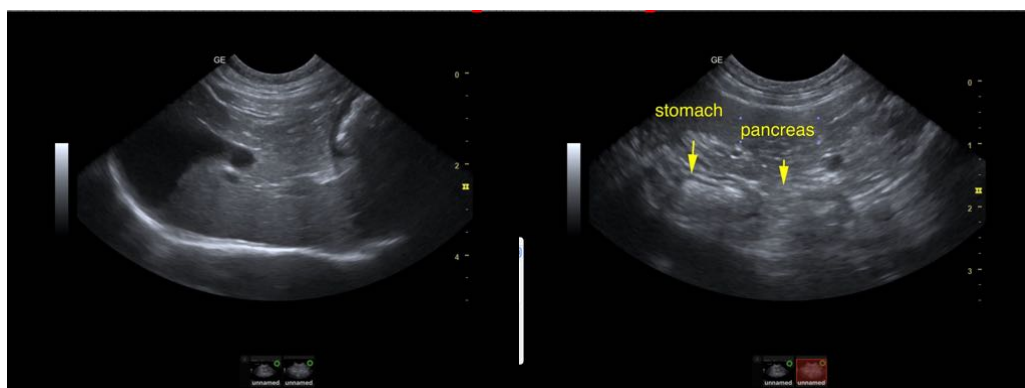
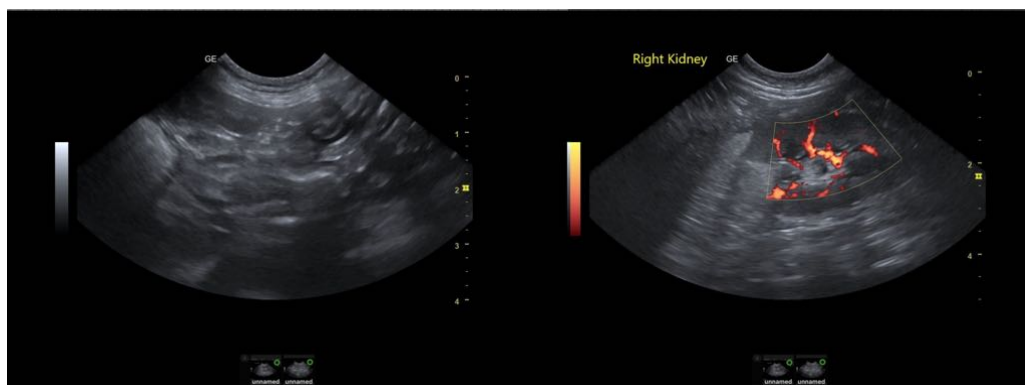
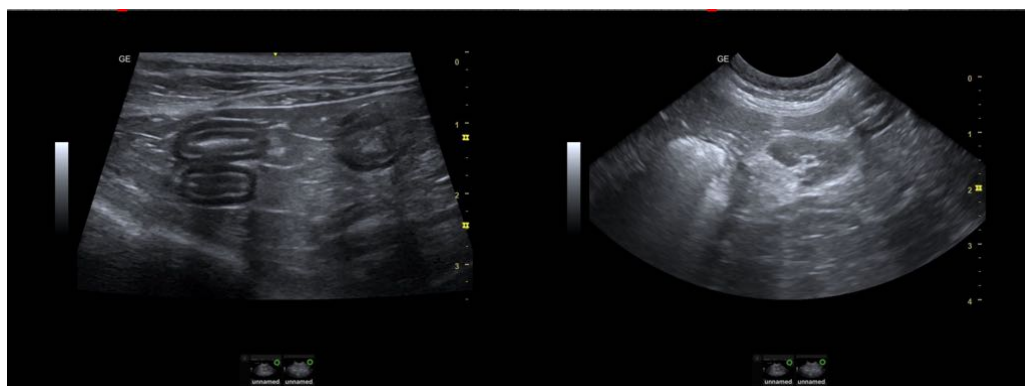
Dr. Leppien

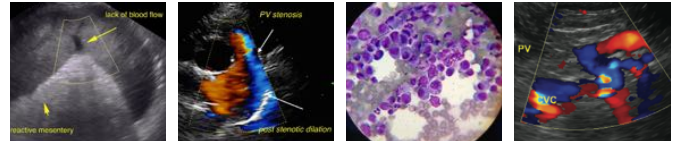
INVOICE

39987

DATE

10/7/22





PATIENT

Boots Kendrick

SPECIES

Feline

BREED

Domestic Shorthair

SEX

Spayed female

AGE

14 years

WEIGHT

9.16 lbs

INTERPRETED BY

Eric Lindquist, DMV
DABVP, Cert. IVUSS

IMAGING PERFORMED BY

Jack Reese

HOSPITAL NAME

Willow Run VC

REFERRING VET

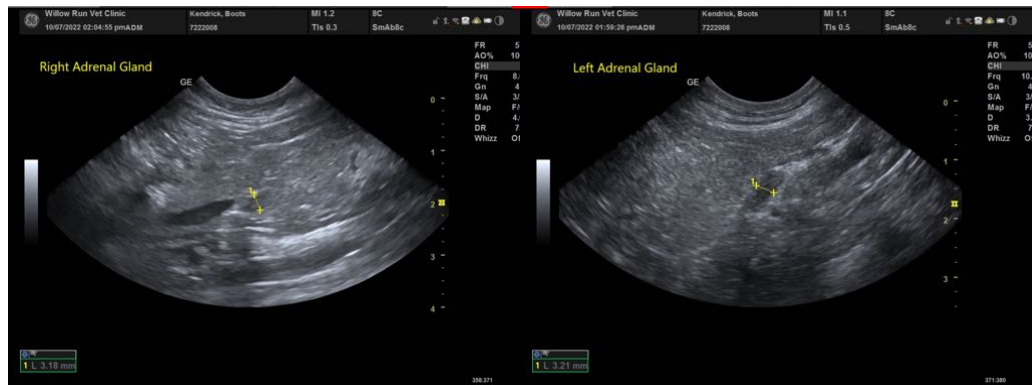
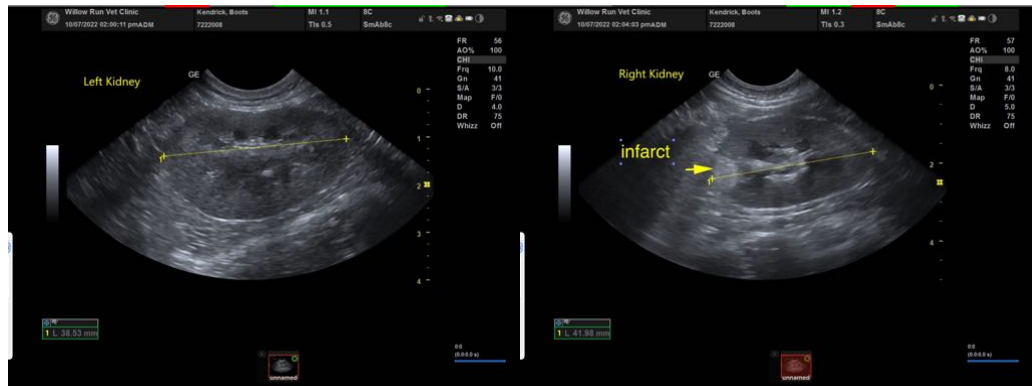
Dr. Leppien

INVOICE

39987

DATE

10/7/22



The information and recommendations provided are based on the images presented by the referring veterinarian/sonographer. No evaluation can be communicated regarding pathology that was not visible in the image/video clips provided.

Thank you for this referral. If the clinical or image interpretation does not parallel your findings or if I can be of any further assistance please contact me.

Eric Lindquist, DMV, DABVP, Cert. IVUSS, CEO of SonoPath.com
info@SonoPath.com