



**PATIENT**

Rocky Ebersole

**SPECIES**

Feline

**BREED**

Domestic Longhair

**SEX**

Neutered male

**AGE**

Approx 8 months

**WEIGHT**

8.2 lbs

**INTERPRETED BY**

Eric Lindquist, DMV  
DABVP, Cert. IVUSS

**IMAGING PERFORMED BY**

Dr. Ebersole

**HOSPITAL NAME**

Scanvet

**REFERRING VET**

Dr. Ebersole

**INVOICE**

39961

**DATE**

10/6/22

**PRESENTING CLINICAL SIGNS**

History: Stray, recently brought home. Unknown history. Heart murmur, no clinical signs. Gabapentin PO for sedation.

Abnormal PE/Chem/CBC/UA Results: PE: Grade 3/6 systolic murmur, parasternal L and R. Does not change with degree of excitement. Felv/FIV/HW: Neg x 3

**ULTRASONOGRAPHIC EXAMINATION OF THE HEART**

The echocardiogram in this patient demonstrated normal **left atrial** size based on 3 separate LA measurements. The cranial and caudal **mitral** valve leaflets presented normal linear structure and kinetics. The **left ventricle** presented normal thicknesses with linear contour and was not dilated nor restricted. The **myocardium** presented normal echogenicity without subjective evidence of significant fibrotic or ischemic disease. **Contractility** of the ventricular walls was adequate and in normal range for this patient evidenced by the fractional shortening measurement and subjective evaluation of the different regions and angles of the myocardium. The **left ventricular outflow** tract demonstrated normal laminar flow and subjective structural integrity. The **right atrium** and auricle revealed normal size, structure and content. No evidence of masses was noted or chamber overload. **Tricuspid** insufficiency was noted at 1.82 m/sec. The **right ventricle** was of normal size (1/3 diameter of LV), chordae structure, myocardial echogenicity and thickness. **Pulmonic** tract assessment revealed normal valve structure, laminar flow, and diameter (approx. 1:1 pa/ao ratio). No visible **pericardial** or free pleura fluid was noted or extra cardiac pathology in the visible planes. The cranial **mediastinum** and **pericardial regions** were free of masses in the visible window. The **hepatic** veins were not dilated.

FELINE CARDIAC PARAMETERS	BODY WEIGHT	HR (BPM)	IVSd (cm)	LVIDd (cm)	LVWd (cm)	FS (%)	EF (%)
NORMAL PARAMETER	-----	150-240	0.3-0.6	1.0-2.1	0.25-0.6	35-67	80-100
PATIENT	8.2 lbs	123	0.47	1.38	0.61	41	76
FELINE CARDIAC PARAMETERS	LA/AO (Boon)	LA/AO HEART BASE (Sisson)	LA 2D 4-chamber long axis AS to FW (Sisson) (cm)	LVOT VEL. (m/s)	RVOT VEL. (m/s)	IVRT (m/)	
NORMAL PARAMETER	<1.5	0.88-1.79	0.7-1.7	<1.6	<1.3	40-60	
PATIENT		1.2	1.46	1.44	1.01	NM	
Adapted from June Boon, Veterinary Echocardiography, 1998 Sisson D et al. JVIM 1991; 5: 232, Jacobs et al. Am J Vet Res 1985; 46:1705							



**PATIENT**

Rocky Ebersole

**ULTRASONOGRAPHIC FINDINGS**

Tricuspid insufficiency, stable. Idiopathic or may be a congenital lesion or acquired.

**SPECIES**

Feline

**INTERPRETATION OF THE FINDINGS & FURTHER RECOMMENDATIONS**

Tricuspid insufficiency is not clinically significant. No contraindication to anesthetic procedure if necessary. A recheck echocardiogram is recommended in 6 months.

**BREED**

Domestic Longhair

**SEX**

Neutered male

**AGE**

Approx 8 months

**WEIGHT**

8.2 lbs

**INTERPRETED BY**

Eric Lindquist, DMV  
DABVP, Cert. IVUSS

**IMAGING PERFORMED BY**

Dr. Ebersole

**HOSPITAL NAME**

Scanvet

**REFERRING VET**

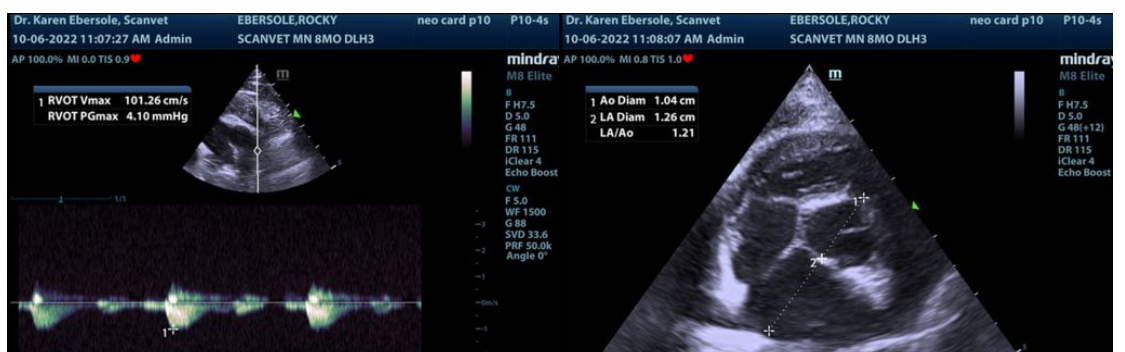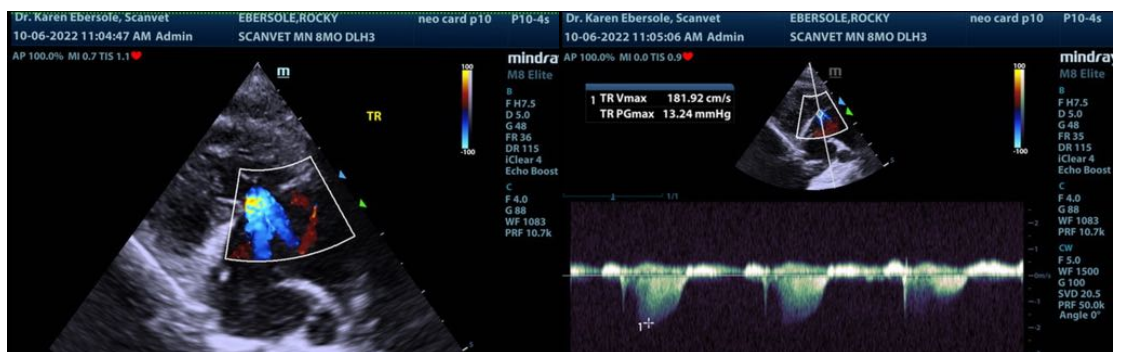
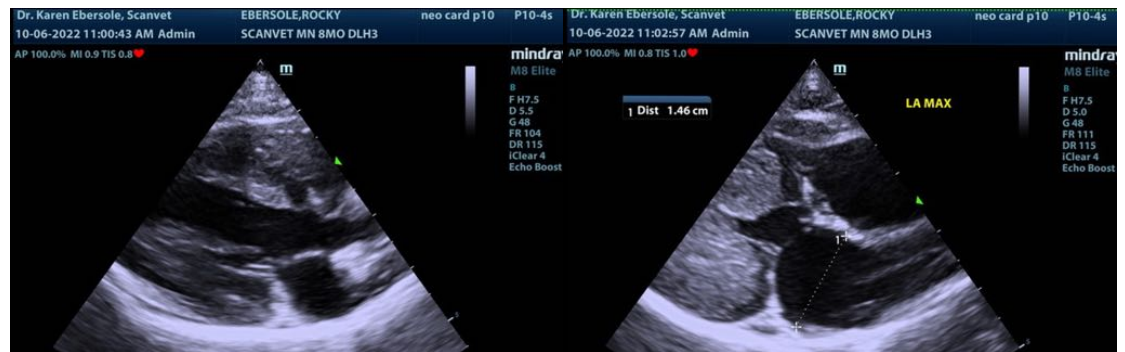Dr. Ebersole

**INVOICE**

39961

**DATE**

10/6/22





**PATIENT**

Rocky Ebersole

**SPECIES**

Feline

**BREED**

Domestic Longhair

**SEX**

Neutered male

**AGE**

Approx 8 months

**WEIGHT**

8.2 lbs

**INTERPRETED BY**

Eric Lindquist, DMV  
DABVP, Cert. IVUSS

**IMAGING PERFORMED BY**

Dr. Ebersole

**HOSPITAL NAME**

Scanvet

**REFERRING VET**

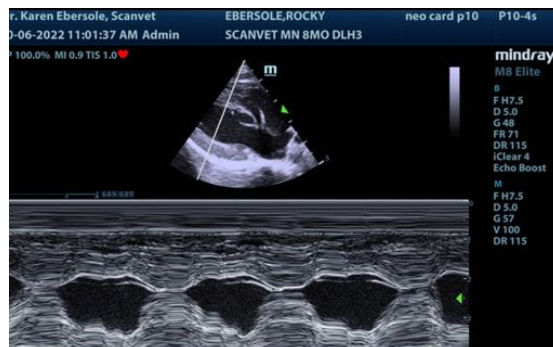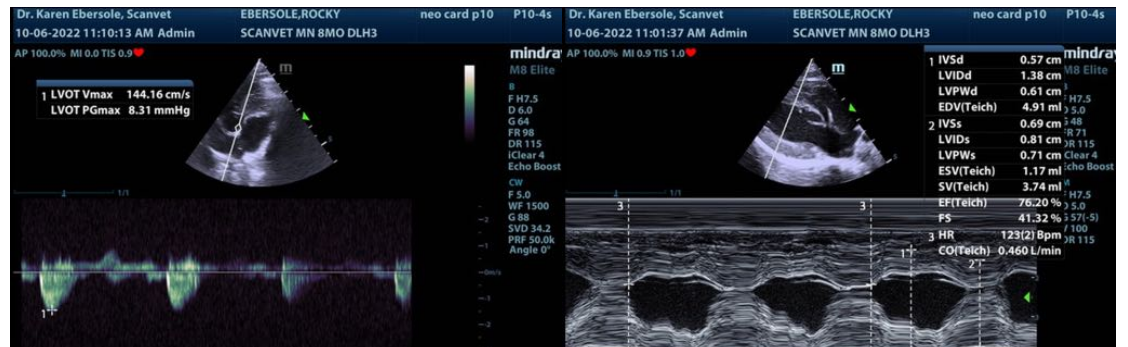Dr. Ebersole

**INVOICE**

39961

**DATE**

10/6/22



The information and recommendations provided are based on the images presented by the referring veterinarian/sonographer. No evaluation can be communicated regarding pathology that was not visible in the image/video clips provided.

Thank you for this referral. If the clinical or image interpretation does not parallel your findings or if I can be of any further assistance please contact me.

**Eric Lindquist, DMV, DABVP, Cert. IVUSS, CEO of SonoPath.com**  
info@SonoPath.com