



**PATIENT**

Buddy Morrill

**SPECIES**

Canine

**BREED**

Boxer Cross

**SEX**

Neutered male

**AGE**

10 years

**WEIGHT**

69.5 lbs

**INTERPRETED BY**

Eric Lindquist, DMV  
DABVP, Cert. IVUSS

**IMAGING PERFORMED BY**

Dr. Bailes

**HOSPITAL NAME**

All Creatures Great  
and Small

**REFERRING VET**

Dr. Bailes

**INVOICE**

39965

**DATE**

10/6/22

**PRESENTING CLINICAL SIGNS**

History: Dermal hemangiosarcoma removed from base of tail 8/30/22. Thoracic rads: NSF  
Abnormal PE/Chem/CBC/UA Results: Multiple hemangioma - like masses ventrum, obese -  
otherwise NSF on PE

**ULTRASONOGRAPHIC EXAMINATION OF THE ABDOMEN**

**Urinary System**

The **bladder** in this patient was mildly thickened with slight echogenic mural changes. No calculi or masses were noted. Slight micropolypoid changes were noted. This is a frequent finding in older animals and may be linked to a history of chronic urinary tract infection or active urinary tract infection. Urinalysis would be recommended with culture if any evidence of inflammatory sediment is present. The region of the trigone and visible pelvic urethra were normal.

The **kidneys** revealed largely normal size and structure, corticomedullary definition and ratio (cortex 1/3 of medulla) were essentially maintained with some age-related loss of curvilinear patterns regarding the capsule and C/M junction. The cortices presented largely uniform texture with some increased echogenicity expected for his age patient. Medullary structure differed distinctly from that of the cortex and no evidence of pelvic dilation was present. Slight, dorsal cortical cysts were noted in the left kidney and measured 0.36 cm. The right kidney measured 6.88 cm. The left kidney measured 6.93 cm.

**Adrenal Glands**

Both **adrenal glands** were visualized and recognized as having normal shape, size, position and echogenicity for this breed. The phrenic vasculature, glandular echogenicity and detail were unremarkable. Capsule, cortex, and medullary definition were normal for this age patient. The left adrenal gland measured 0.5 cm. The right adrenal gland measured 1.92 x 0.45 cm at the cranial pole and 0.59 cm at the caudal pole.

**Spleen**

The **spleen** presented a smooth homogeneous parenchyma hyperechoic to liver and renal cortical parenchyma. The capsule was smooth without noticeable expansion or deviation from within the spleen or adjacent pathology. The splenic vasculature demonstrated normal volume without signs of congestion or thrombosis. No sonographic evidence of acute or chronic inflammatory, neoplastic, or infarctual changes was noted.

**Liver**

The **liver** images from right and left intercostal as well as subcostal views revealed subjectively normal liver size, contour, and structure. Some age-related parenchymal remodeling was noted but likely not clinically significant at this time. Vascular and biliary tracts were of normal volume and no evidence of congestion was noted. The gallbladder presented some dependent debris with essentially normal contour. The cystic and common bile ducts were normal. No overt evidence of active inflammatory,



**PATIENT**

Buddy Morrill

infiltrative or regenerative pathology was noted but should be paired with current or past LE elevations regarding any clinical significance to this presentation. The hepatic lymph nodes were unremarkable.

**SPECIES**

Canine

**Gastrointestinal**

Examination of the **gastrointestinal tract** revealed a stomach and intestine free of stasis, of normal wall thickness, acceptable curvilinear mural detail, and peristaltic activity. Small and large intestine demonstrated normal luminal chyme and stool consistency respectively. No obstructive or overt infiltrative disease was noted. No associated abnormal lymphatic activity was noted.

**BREED**

Boxer Cross

**SEX**

Neutered male

**Pancreas**

The base and limbs of the **pancreas** were observed to be largely isoechoic to surrounding omental fat. Pancreatic duct and capsular contour were acceptably normal and parenchyma respected normal curvilinear patterns. No overt evidence of active inflammatory or neoplastic disease was noted.

**AGE**

10 years

**ULTRASONOGRAPHIC FINDINGS**

Left renal cortical cysts.

**WEIGHT**

69.5 lbs

**INTERPRETATION OF THE FINDINGS & FURTHER RECOMMENDATIONS**

I cannot completely rule out that the cystic structure in the left kidney is not emerging metastatic lesion. Given the patient's history this should be monitored over the next 2-23 weeks to assess for any growth. The remainder of the abdomen was unremarkable.

**INTERPRETED BY**

Eric Lindquist, DMV  
DABVP, Cert. IVUSS

**IMAGING PERFORMED BY**

Dr. Bailes

**HOSPITAL NAME**

All Creatures Great and Small

**REFERRING VET**

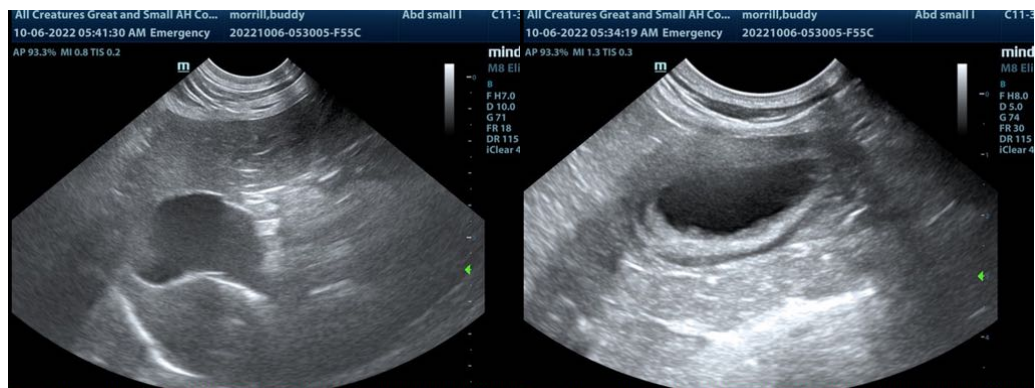
Dr. Bailes

**INVOICE**

39965

**DATE**

10/6/22





**PATIENT**

Buddy Morrill

**SPECIES**

Canine

**BREED**

Boxer Cross

**SEX**

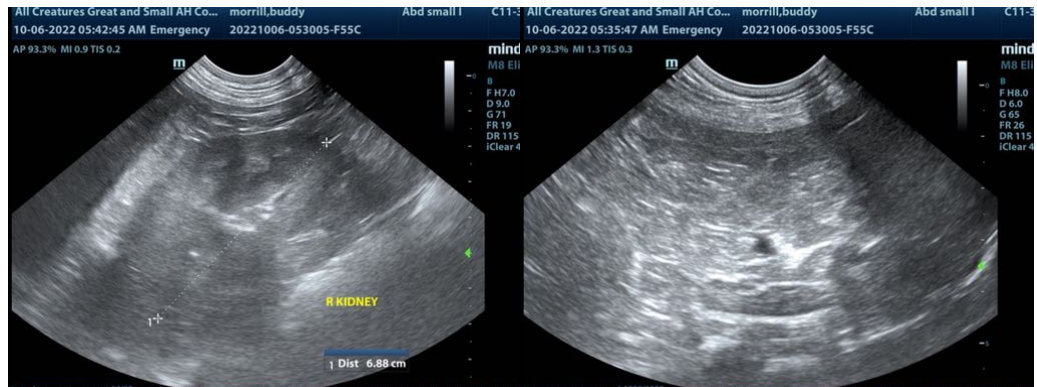
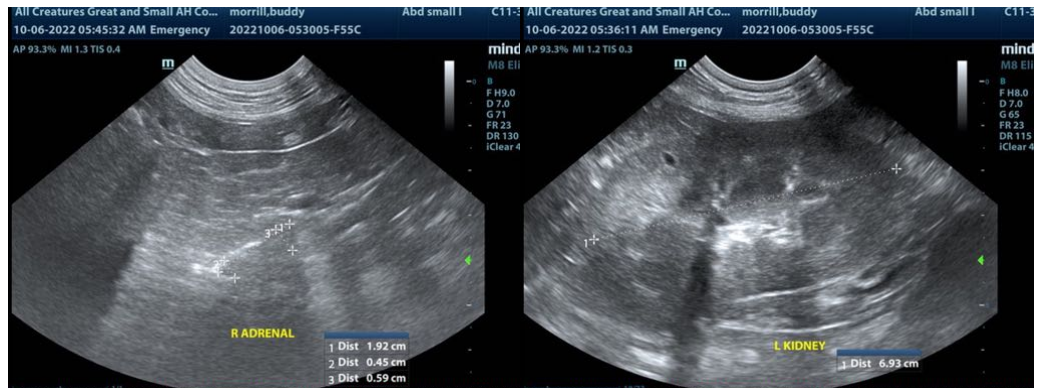
Neutered male

**AGE**

10 years

**WEIGHT**

69.5 lbs



**INTERPRETED BY**

Eric Lindquist, DMV  
DABVP, Cert. IVUSS

**IMAGING PERFORMED BY**

Dr. Bailes

**HOSPITAL NAME**

All Creatures Great and Small

**REFERRING VET**

Dr. Bailes

**INVOICE**

39965

**DATE**

10/6/22

The information and recommendations provided are based on the images presented by the referring veterinarian/sonographer. No evaluation can be communicated regarding pathology that was not visible in the image/video clips provided.

Thank you for this referral. If the clinical or image interpretation does not parallel your findings or if I can be of any further assistance please contact me.

Eric Lindquist, DMV, DABVP, Cert. IVUSS, CEO of SonoPath.com  
info@SonoPath.com